

ADULT OCULAR ONCOLOGY

A CONCISE GUIDE

**Bertil Damato
Maya Klaff-Dahl
Malin Ermedahl Conradi
Gustav Stålhammar
&
Maria Fili (Director)**

**Sektionen för ögononkologi
S:t Eriks Ögonsjukhus
Stockholm**

CONTENTS

CONTENTS	2
PREFACE	6
DETECTION OF OCULAR TUMORS	7
INVESTIGATION	8
HISTORY	8
VISUAL ACUITY	8
CONJUNCTIVAL EXAMINATION	8
EXTRAOCULAR TUMOR	9
PREDISPOSING CONDITIONS FOR CONJUNCTIVAL MALIGNANT TUMORS	9
ANTERIOR SEGMENT EXAMINATION	10
ANTERIOR SEGMENT TUMOR	10
SECONDARY EFFECTS	10
PREDISPOSING CONDITIONS FOR INTRAOCULAR TUMORS	10
POSTERIOR SEGMENT EXAMINATION	11
POSTERIOR SEGMENT TUMOR	11
SECONDARY EFFECTS	11
THREE-MIRROR EXAMINATION	11
TRANSILLUMINATION	11
COLOR PHOTOGRAPHY	12
FUNDUS AUTOFLUORESCENCE (FAF)	13
FLUORESCEIN ANGIOGRAPHY	14
INDOCYANINE-GREEN ANGIOGRAPHY (ICG)	14
OPTICAL COHERENCE TOMOGRAPHY (OCT)	14
ULTRASONOGRAPHY (US)	15
METHODS:	16
TUMOR BIOPSY	17
EXCISIONAL BIOPSY	18
INCISIONAL BIOPSY	18
	2

ASPIRATION BIOPSY	18
CONJUNCTIVAL IMPRINT CYTOLOGY	19
LIQUID BIOPSY	19
COMPUTERIZED TOMOGRAPHY (CT)	19
MAGNETIC RESONANCE IMAGING (MRI)	19
OCULAR TUMORS	20
UVEAL MELANOMA	20
CLINICAL FEATURES	20
CLINICAL INVESTIGATIONS	21
LABORATORY INVESTIGATIONS	21
SURVIVAL PROGNOSTICATION	22
TREATMENT	23
OCULAR RESULTS OF CONSERVATIVE THERAPY	27
METASTATIC DISEASE FROM UVEAL MELANOMA	28
COUNSELLING	29
CHOROIDAL NEVUS	29
MOLES SCORING SYSTEM	29
MELANOCYTOMA	32
CONGENITAL OCULAR MELANOCYTOSIS	32
CHOROIDAL HEMANGIOMA	33
CHOROIDAL OSTEOMA	33
SCLERO-CHOROIDAL CALCIFICATION	34
OCULAR SCLEROMA	34
NEUROFIBROMA, NEURILEMMOMA AND LEIOMYOMA	35
ASTROCYTIC HAMARTOMA	35
RETINAL CAVERNOUS ANGIOMA	35
CONGENITAL RETINAL ARTERIOVENOUS MALFORMATION	35
RETINAL HEMANGIOBLASTOMA	36
VASOPROLIFERATIVE TUMOR	36
RETINOBLASTOMA	37
MEDULLOEPITHELIOMA	37
CONGENITAL HYPERTROPHY OF THE RPE (CHRPE)	37

IRIS CYSTS	38
ADENOMA AND ADENOCARCINOMA	39
COMBINED HAMARTOMA OF THE RPE AND RETINA	39
INTRAOCULAR METASTASIS	39
VITREORETINAL LYMPHOMA	40
OTHER HEMATOLOGICAL MALIGNANCIES	41
PARANEOPLASTIC SYNDROMES	42
CONJUNCTIVAL MELANOMA	42
PRIMARY ACQUIRED CONJUNCTIVAL MELANOSIS (PAM)	43
CONJUNCTIVAL NEVUS	44
SQUAMOUS PAPILLOMA	44
OCULAR SURFACE SQUAMOUS NEOPLASIA	45
INVASIVE CONJUNCTIVAL CARCINOMA	46
SEBACEOUS GLAND CARCINOMA	46
CONJUNCTIVAL LYMPHOMA	46
CHORISTOMA	47
OTHER CONJUNCTIVAL LESIONS	47
PATIENT REFERRAL	48
INDICATIONS FOR REFERRAL	48
METHOD OF REFERRAL	48
CONDITIONS NOT NEEDING REFERRAL	48
MONITORING PATIENTS	50
INDICATIONS	50
COUNSELLING	52
OCULAR SURVEILLANCE	53
IMMEDIATE POST-OPERATIVE PERIOD	53
LONG-TERM TUMOR MONITORING	53

SYSTEMIC SURVEILLANCE FOR METASTASIS	56
INDICATIONS	56
DURATION	56
METHODS	56
DIAGNOSTIC AND THERAPEUTIC PROCEDURES AT LOCAL HOSPITAL	57
CATARACT SURGERY	57
GLAUCOMA SURGERY	57
STRABISMUS SURGERY	57
TREATMENT FOR MACULAR EDEMA	57
TREATMENT FOR EXUDATIVE RETINAL DETACHMENT	58
ENUCLEATION	58
REMOVAL OF EXTRUDING TANTALUM MARKER	58
BIOPSY OF CONJUNCTIVAL PRIMARY ACQUIRED MELANOSIS	58
EXCISION BIOPSY OF NODULAR CONJUNCTIVAL TUMORS	58
VITREORETINAL LYMPHOMA BIOPSY	59

PREFACE

We have prepared this guide to enhance our collaboration with ophthalmologists and other colleagues from all over Sweden.

Here, we focus on the most common conditions and treatments. This guide is not meant to be encyclopedic.

If this text is read with a PDF reader, items of interest can easily be found by doing a word search. References are not included, because it is so easy to search the literature on the Internet.

This guide has been adapted from similar guides prepared for Moorfields Eye Hospital, London, and the Royal Liverpool University Hospital, United Kingdom.

Any suggestions for improving this guide would be most welcome.

Bertil Damato
Maya Klaff-Dahl
Malin Ermedahl Conradi
Gustav Stålhammar
&
Maria Fili
(Director)



Maria Fili



Bertil Damato



Maya Klaff-Dahl



Malin Ermedahl Conradi

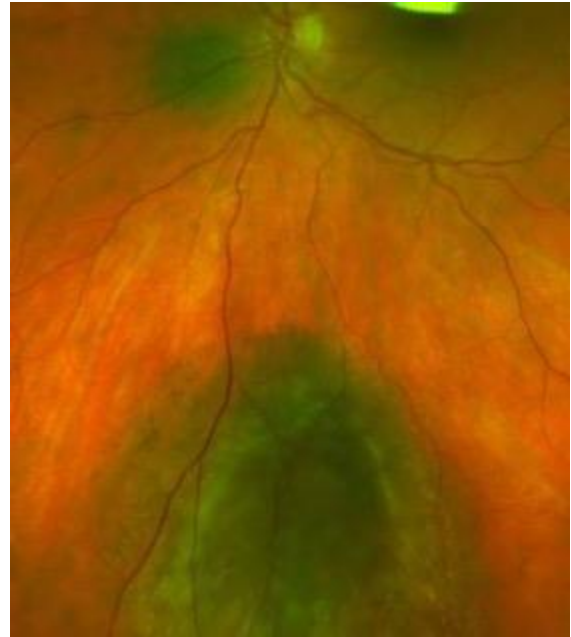

Gustav Stålhammar

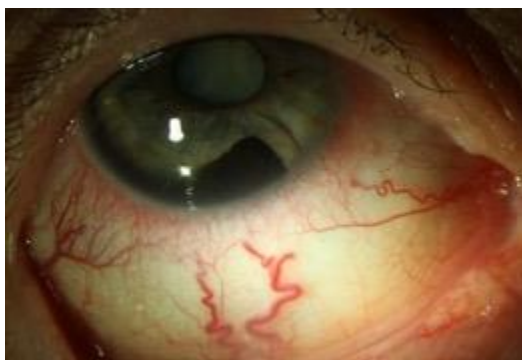DETECTION OF OCULAR TUMORS

Many asymptomatic tumors are detected by routine screening, for example, performing bilateral ophthalmoscopy when the patient has presented for new spectacles. However, it is not uncommon for patients to present with a symptomatic choroidal tumor soon after having an eye examination, suggesting perhaps that the ophthalmoscopy was limited to optic disc and macula. A significant proportion of patients with uveal melanoma report that their tumor was not detected when they first presented on account of symptoms. In comparison with symptomatic patients whose tumor is immediately detected, such individuals experience longer delays in obtaining treatment and are also more likely to lose vision and the eye.

There is no consensus as to whether both pupils should be dilated in all patients or only if there are any specific indications. It is beyond the scope of these guidelines to comment on what is acceptable in routine practice in Sweden.



Peripheral choroidal melanoma, which would have been missed if the examiner had focused only on 'disc and macula' and the juxtapapillary choroidal nevus



Sentinel vessels overlying a ciliary body melanoma that has invaded the anterior chamber

INVESTIGATION

HISTORY

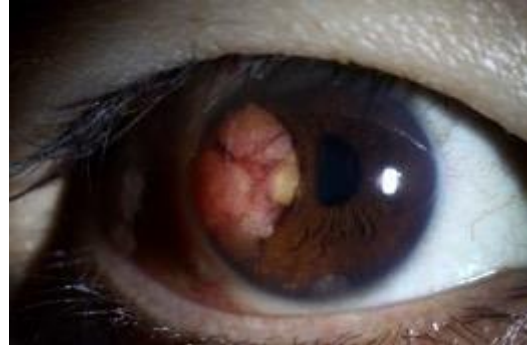It is necessary to obtain a full history including:

- Ocular symptoms, and their duration.
- Systemic enquiry
- Past ocular and systemic history.
- Family history of ocular and systemic disease.
- Topical and systemic medications.
- Present and past history regarding smoking, alcohol and other habits.
- Allergies.
- Social and occupational status, not least to understand the patient's visual needs.

The history can sometimes provide diagnostic clues, for example, if the patient has been a heavy smoker for many years or if a previous mastectomy has been performed. While such information might suggest the source of an intraocular metastasis, it should not be relied upon to distinguish between a metastasis and other types of tumor, such as melanoma and hemangioma. This is because dual pathology is not uncommon.

The history also provides an understanding of the patient's visual needs, which may help in the selection of the most appropriate form of treatment.

The duration of the visual loss can have prognostic significance, for example, in patients with choroidal hemangioma in whom visual loss is irreversible if long-standing.



Iris tumor in a 51-year-old woman with a history of breast cancer with systemic metastases. Ocular metastasis was confirmed.

VISUAL ACUITY

Ideally, visual acuity is measured using a LogMAR chart, which overcomes the limitations of the Snellen test.

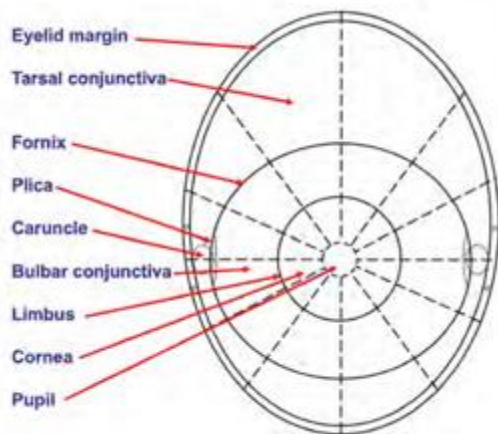
CONJUNCTIVAL EXAMINATION

When the patient has a conjunctival tumor, it is essential to examine the entire conjunctiva. The superior fornix can be inspected by gently pinching the eyelid skin and pulling the eyelid away from the globe, using a binocular indirect ophthalmoscope and 20 D lens.

Palpation of the pre- and post-auricular, cervical and submandibular areas is performed routinely, to detect any lymph node enlargement.

In addition to assessing the primary tumor, it is useful to document any secondary effects, identify any predisposing factors and recognize any concurrent disease.

Damato has devised a diagram that shows the entire conjunctival surface unobstructed by half-closed eyelids.



Template for drawing conjunctival tumors

EXTRAOCULAR TUMOR

A primary conjunctival or corneal tumor is described according to:

- Most likely site of origin (i.e., conjunctiva, cornea, intraocular structures, eyelid).
- Quadrant (i.e., superior, supero-nasal, nasal, etc.).
- Circumferential spread, which is measured in clock minutes in a clockwise direction (e.g., 5 to 30 or 55 to 5). This is easier than using degrees and more precise than clock hours. Circumferential spread can be described separately at limbus, bulbar conjunctiva, palpebral conjunctiva, etc.
- Posterior extent (e.g., cornea, limbus, bulbar conjunctiva).
- Anterior extent (e.g., fornix, palpebral conjunctiva, lid margin, skin).
- Consistency (i.e., solid, cystic, multicystic).
- Distortion of normal anatomy.
- Shape (i.e., flat, dome, unifocal-multinodular, multifocal).
- Margins (i.e., diffuse, discrete).
- Color (i.e., pink, white, tan, etc.).
- Vascularity (present or absent).
- Seeding (i.e., across conjunctiva, into cornea, etc.).
- Deep invasion (i.e., conjunctival stroma, sclera, and intraocularly)
- Longitudinal and transverse basal dimensions, using the measure on the slit-lamp
- Extraocular spread (i.e., pre-auricular, sub-mandibular nodes, etc.)

SECONDARY EFFECTS OF EXTRAOCULAR TUMOR

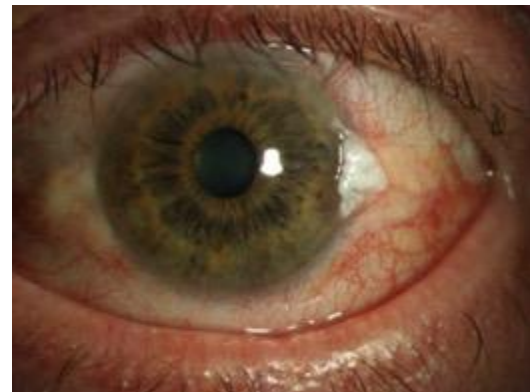
These include features such as:

- Feeder vessels.
- Infection.
- Hemorrhage.

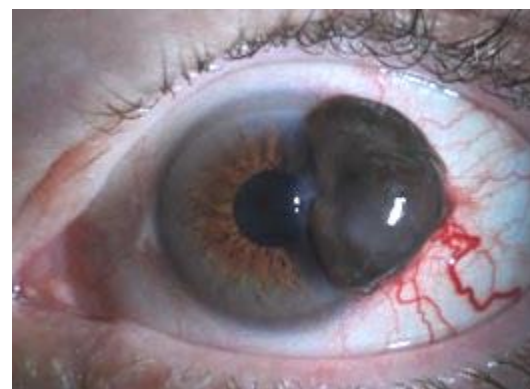PREDISPOSING CONDITIONS FOR CONJUNCTIVAL MALIGNANT TUMORS

These include conditions such as:

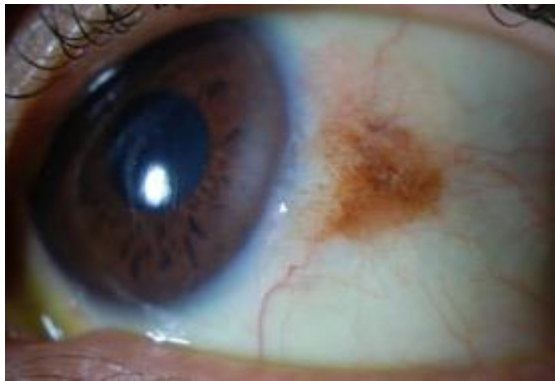
- Primary acquired melanosis.
- Eyelid sebaceous gland carcinoma, which can recur in a pagetoid fashion in conjunctiva.
- Actinic keratosis.



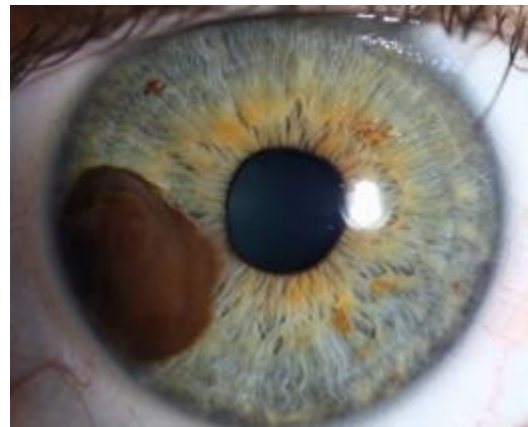Conjunctival carcinoma at the temporal limbus of the left eye



Feeder vessels supplying a conjunctival melanoma of the left eye



Primary acquired melanosis of the left eye, which predisposes to invasive melanoma



Iris melanoma

CONCURRENT DISEASE

Abnormalities that may be relevant to the treatment of the ocular tumor include:

- Keratoconjunctivitis sicca.
- Marginal keratitis.
- Ingrowing lashes.

ANTERIOR SEGMENT EXAMINATION

ANTERIOR SEGMENT TUMOR

The tumor is described according to:

- Most likely site of origin (i.e., iris, ciliary body, choroid).
- Quadrant (i.e., superior, supero-nasal, etc)
- Circumferential spread, ideally in clock minutes in a clockwise direction (e.g., 5 to 30 or 55 to 5).
- Posterior extent (e.g., choroid, pars plana, pars plicata, pupil margin, iris surface).
- Anterior extent (e.g., iris surface, angle, cornea).
- Longitudinal and transverse basal dimensions, using the measure on the slit-lamp. (See below for ultrasonography).
- Consistency (i.e., solid, cystic, multicystic).
- Shape (i.e., flat, dome, multinodular).
- Margins (i.e., diffuse, discrete).
- Color (i.e., pink, white, tan, etc.).
- Vascularity (present or absent).
- Seeding (i.e., across iris or into angle).
- Angle involvement (i.e., in clock minutes).
With melanoma, it can be difficult to distinguish tumor from melanomacrophages clinically
- Extraocular spread (i.e., absent, nodular, diffuse).

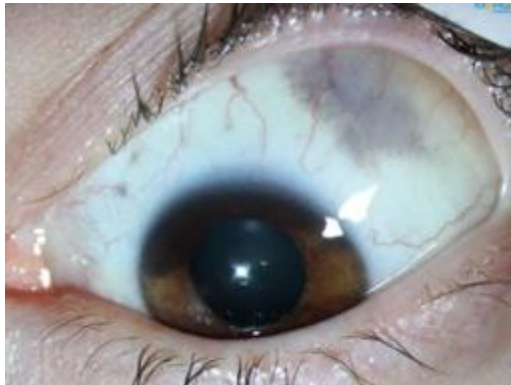
SECONDARY EFFECTS

These include:

- Glaucoma.
- Lens abnormality (e.g., cataract, deformity, subluxation).
- Dilated episcleral vessels, in the presence of ciliary body involvement.
- Iris cyst formation.
- Ectropion uveae.
- Pupillary peaking.
- Hyphema.
- Band keratopathy.

PREDISPOSING CONDITIONS FOR INTRAOCULAR TUMORS

- Ocular or oculodermal melanocytosis (uveal melanoma).
- Sturge-Weber syndrome (diffuse choroidal hemangioma) and other vascular malformations.
- *BAP1* Tumor Predisposition Syndrome (uveal melanoma)
- *DICER1* Tumor Predisposition Syndrome (medulloepithelioma)



Congenital ocular melanocytosis with slate-grey subconjunctival pigmentation supero-temporally and with sectorial iris pigmentation supero-nasally in the left eye of a child.

POSTERIOR SEGMENT EXAMINATION

POSTERIOR SEGMENT TUMOR

To describe a posterior segment tumor, as many of the following features as possible should be noted:

- Tissue of origin (e.g., choroid, retina, RPE).
- Shape (e.g., dome, mushroom, etc.).
- Margins (i.e., discrete, diffuse).
- Tissue color (e.g., grey, pink, white, etc.).
- Vascularity (e.g., vascular, avascular).
- Quadrant (e.g., superior, supero-temporal, etc.).
- Posterior extent, including distances to optic disc and fovea.
- Anterior extent (i.e., post-equatorial, pre-equatorial, pars plana, pars plicata, angle, etc.).
- Circumferential involvement of optic disc and ciliary body (e.g., in clock minutes).
- Internal spread (e.g., sub-retinal space, retina, vitreous).
- Size (i.e., longitudinal, transverse and largest basal dimensions, and thickness).

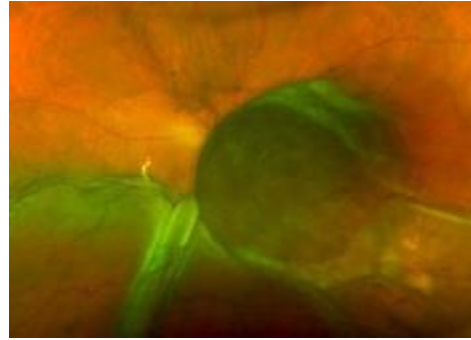
SECONDARY EFFECTS

The presence of any secondary effects should be recorded, which include:

- RPE changes overlying tumor (i.e., drusen, orange pigment, choroidal neovascular membrane).
- RPE changes adjacent to tumor (i.e., marginal atrophy, cobblestone degeneration, 'comet's tail' or 'peacock tail' atrophy). Exudative retinal detachment (i.e., over tumor surface, inferior retina, with an

estimate of the percentage of retina detached).

- Hemorrhage (i.e., subretinal, vitreous, etc.)
- Cataract.
- Glaucoma.

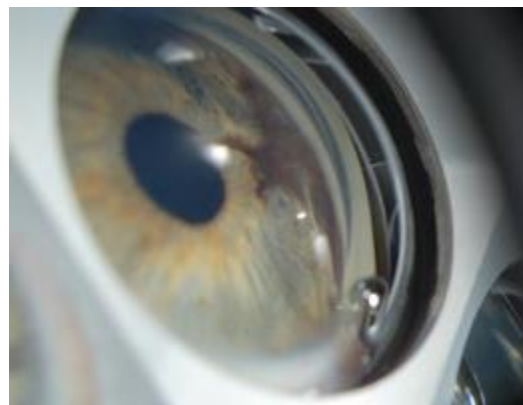

Choroidal melanoma that has perforated Bruch's membrane, retinal pigment epithelium and retina, which is detached.

THREE-MIRROR EXAMINATION

The indications are to:

- Identify the cause of raised intraocular pressure.
- Determine (after mydriasis) whether a lesion behind the iris is solid or cystic.
- Find a small, retinal angioma.
- Determine the anterior extent of a pre-equatorial tumor.
- Measure the circumferential extent of ciliary body or angle involvement by a tumor, aligning in turn each lateral tumor margin with the center of the mirror.



Gonioscopy showing tumor spread around the angle

TRANSILLUMINATION

- **Trans-pupillary**, placing the illuminator on the cornea. Care is taken not to overestimate posterior extension because of a

shadow cast by a thick tumor when the light is shone obliquely. If a transilluminator is not available, the examiner can assess translucency while an assistant shines a light through the pupil with a binocular indirect ophthalmoscope and lens.

- **Trans-ocular**, with a right-angled transilluminator on the globe directly opposite to the tumor. This is less convenient than trans-pupillary transillumination, but slightly more accurate.
- **Trans-scleral**, with the light source on the sclera over the tumor. This only determines whether the tumor transmits light.

Not all pigmented tumors are melanomas and not all melanomas are pigmented.



Transpupillary transillumination showing the shadow of a choroidal melanoma extending to ora serrata

COLOR PHOTOGRAPHY

Color photography is useful for:

- Documenting the tumor size and its distances from optic disc and fovea (e.g., in disc diameters). This information is particularly useful when the tumor shows diffuse spread that is not adequately defined with ultrasonography (see below).
- Documenting the circumferential location of the tumor with respect to fovea. This is useful when preparing a 3-D model of the eye for planning radiotherapy.

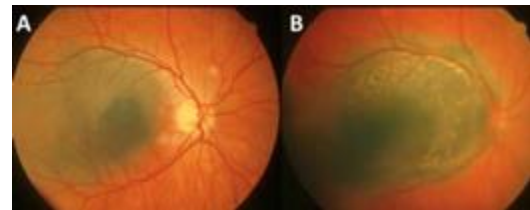Widefield imaging has greatly improved documentation of retinal and choroidal tumors. (PMID31890289)

Color photography helps to determine whether the tumor is growing, for example, when differentiating nevus from melanoma or to detect marginal tumor recurrence after conservative therapy.

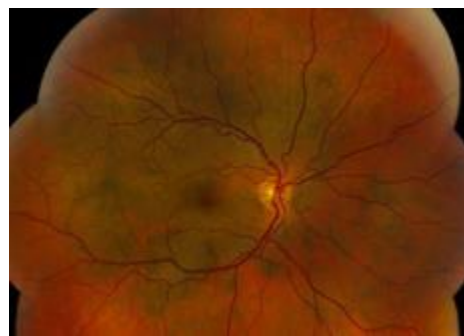The relationship between tumor margins and adjacent retinal vessels is noted, taking into consideration any variation in magnification and illumination.

When photographing extraocular tumors, the angle of illumination is adjusted to highlight any surface features of the tumor. When an iris lesion is photographed, care is taken to avoid corneal reflections over the lesion.

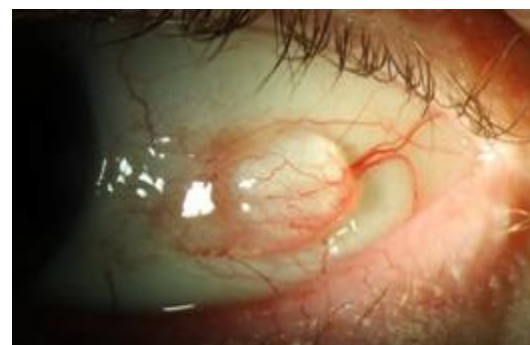
All patients should, if possible, be asked to sign a consent form for the use of their images for teaching, research, and audit purposes and for publication in journals and on the Internet. If the face is photographed so that the patient is identifiable, special consent is required.



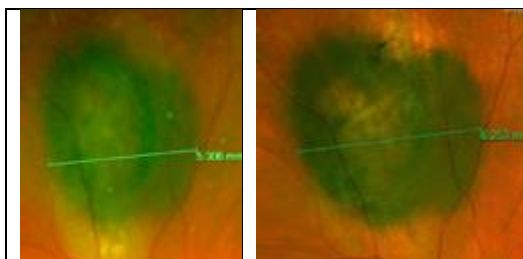
Choroidal melanoma in the right eye (A) at presentation, and (B) three years later, when the tumor had grown to involve the optic nerve. Unfortunately, the patient had got lost to follow-up. Note the lateral extension across blood vessels and the increased lipofuscin.



Choroidal metastases from cutaneous melanoma. The tumors were too thin and diffuse for assessment by ultrasonography



Conjunctival cyst, best demonstrated by oblique illumination.



Sequential measurement of this tumor suggests an increase in transverse basal diameter from 5.3 mm to 6.3 mm, but this is a false impression caused by photographic artifact, as revealed by unchanged distances between the tumor margins and the retinal blood vessels.

FUNDUS AUTOFLUORESCENCE (FAF)

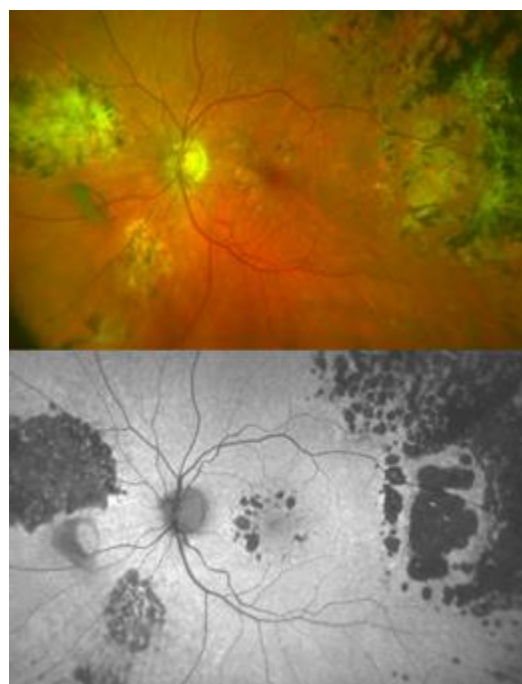
This investigation helps to identify abnormalities that may not be visible with color photography. (PMID23429597)

Hyper-autofluorescent abnormalities include: lipofuscin, hemosiderin, subretinal lymphomatous deposits, and RPE/outer retinal damage caused by serous retinal detachment, which may be intermittent.

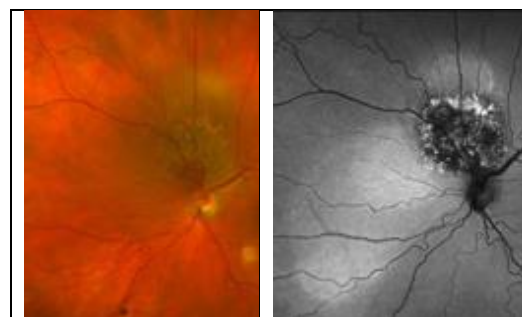Hypo-autofluorescent abnormalities include RPE atrophy over a choroidal tumor - as well as RPE and choroidal atrophy exposing sclera.

FAF is especially useful for distinguishing choroidal nevi from small melanomas according to the amount of lipofuscin on the tumor surface. Lipofuscin can develop also over other kinds of tumor, such as metastases and hemangiomas.

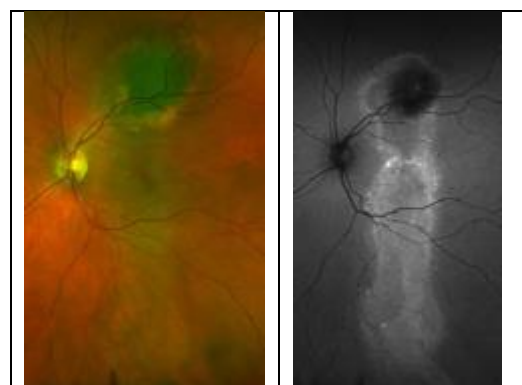FAF is also useful for assessing activity in eyes with vitreoretinal lymphoma.



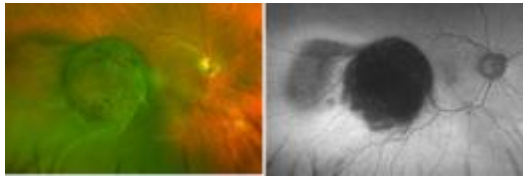
Retinal lymphoma with fine hyper-autofluorescent sub-RPE tumor deposits and hypo-autofluorescent areas of RPE atrophy



Choroidal melanoma with hyper-autofluorescent lipofuscin and RPE abnormality



Hyper-autofluorescence caused by fluid leakage from a small choroidal melanoma. Note also the brightly hyper autofluorescent lipofuscin that has desquamated from the tumor to settle inferiorly.



Mushroom melanoma, with hypo-autofluorescence where tumor has broken through RPE

FLUORESCCEIN ANGIOGRAPHY

Tumor fluorescence is related to:

- Fluorescein concentration in the tumor stroma.
- Hyperfluorescent RPE abnormalities, such as drusen, RPE detachments, choroidal new vessels and serous retinal detachment.
- Intervening hypofluorescent pigments, which include
 - (a) melanin in the tumor and RPE; (b) hemoglobin in any hemorrhages; and (c) lipofuscin (i.e., 'orange pigment').
- Reflections from white tissue, such as exposed sclera.
- Autofluorescence, which occurs with optic disc drusen.

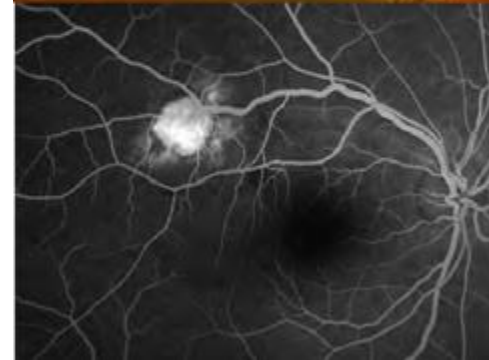
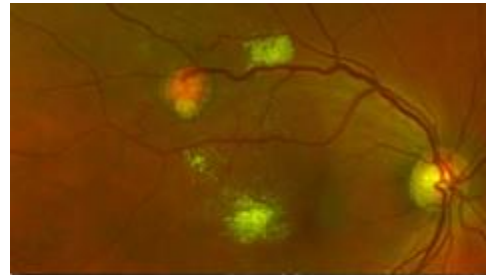
Fluorescence does not indicate whether a lesion is benign or malignant.

Hypofluorescence after phototherapy or radiotherapy of a choroidal melanoma does not necessarily mean that the tumor is destroyed.

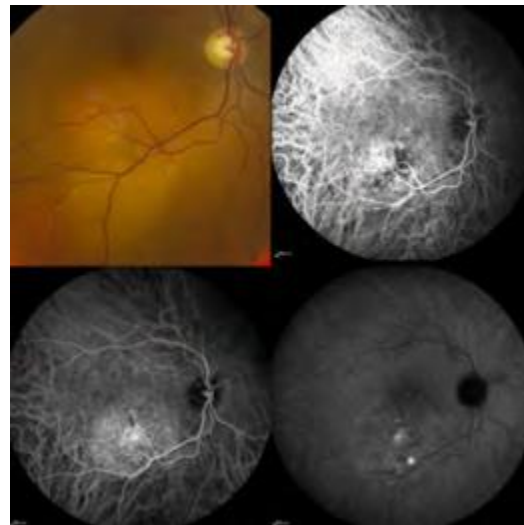Fluorescein angiography is most useful when investigating retinal vascular tumors and ocular neovascular complications.

INDOCYANINE-GREEN ANGIOGRAPHY (ICG)

The principles of fluorescein angiography apply to indocyanine green angiography (ICG), except that the infra-red light is not absorbed by melanin and hemoglobin to the same extent as fluorescein, so that changes in the RPE and retina are less conspicuous and so that choroidal vasculature is visible. Although choroidal hemangiomas show typical features on ICG angiography this investigation is not usually necessary because the ophthalmoscopic appearances are so characteristic.



Retinal hemangioblastoma, showing hyperfluorescence on fluorescein angiography



ICG angiogram of a choroidal hemangioma. Typically, choroidal hemangiomas show hypo fluorescence ('washout') in the late stages of the angiogram, but this feature is not always present, as in this case.

OPTICAL COHERENCE TOMOGRAPHY (OCT)

OCT demonstrates abnormalities such as cystoid edema, retinal detachment, drusen, lipofuscin, and RPE detachment and atrophy. (PMID25827541, 35959157)

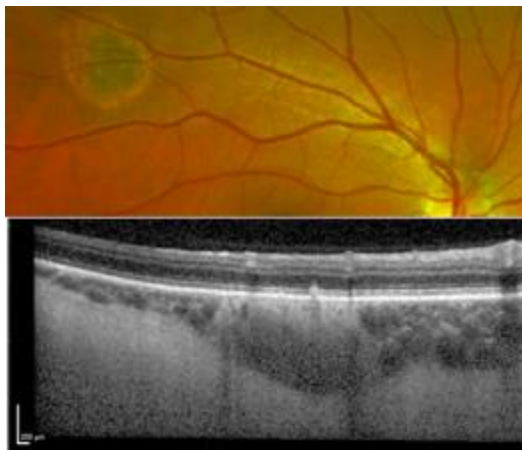
This investigation can also provide diagnostic clues (e.g., choroidal metastases and lymphomas as well as posterior scleritis tend to

have a lumpy surface not usually seen with other lesions.

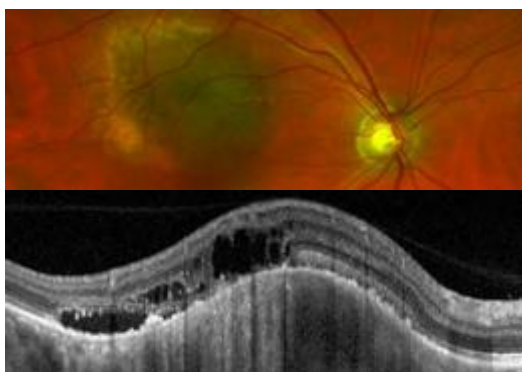
OCT is also useful for measuring thickness of small, posterior tumors, if the appropriate type of scan is performed (e.g., enhanced depth imaging).

Anterior segment OCT can help define iris and conjunctival lesions.

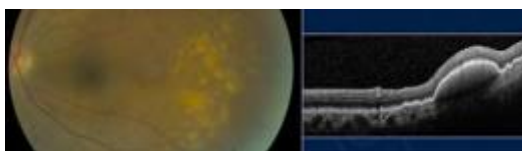
OCT angiography reveals radiation-vasculopathy providing information that can help predict response to anti-angiogenic agents in patients with macular edema after radiotherapy.



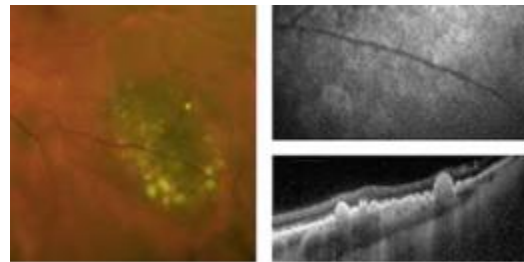
OCT showing a halo choroidal nevus with a flat anterior surface but with a convex posterior surface. In cases like this, OCT measures tumor thickness more accurately than US.



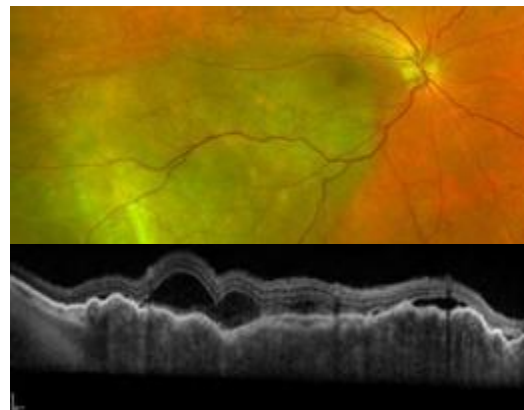
OCT showing intra-retinal edema (a sign of chronicity) and sub-retinal fluid, as well as clumps of orange pigment on the anterior RPE surface over a choroidal melanoma



OCT showing sub-RPE deposits of lymphoma cells, trapped by Bruch's membrane.



Drusen overlying a choroidal nevus. (Top left) Color photograph showing discrete, pearly-white drusen, (Top right) FAF showing minimal fluorescence, and (Bottom right) OCT showing sub-RPE location of drusen, which helps differentiate these from lipofuscin, which is on the retinal surface of the RPE



OCT showing the lumpy surface (typical of a choroidal metastasis), also with retinal detachment

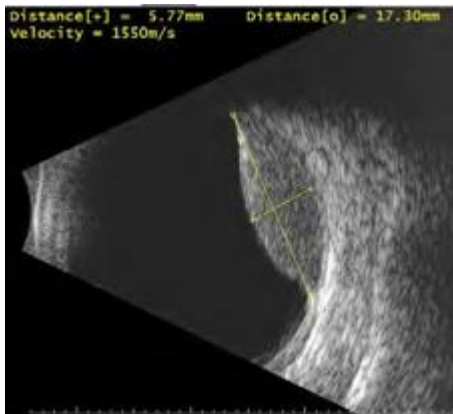
ULTRASONOGRAPHY (US)

Ultrasonography has several applications in ocular oncology. (PMID26910565) It is performed to:

- Detect an intraocular tumor when the media are opaque, for example, in the presence of vitreous hemorrhage or cataract.
- Detect posterior extraocular tumor extension.
- Define the shape of the tumor (i.e., dome, diffuse, multilobular or mushroom). A mushroom shape is almost pathognomonic of uveal melanoma.
- Measure tumor dimensions (e.g., when planning therapy or assessing tumor growth or regression over time). Ultrasonography is not useful for monitoring small tumors,

because color photography and OCT are usually more sensitive.

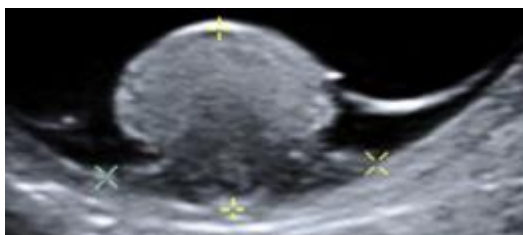
- Demonstrate internal acoustic reflectivity, which may suggest a particular diagnosis. (e.g., acoustically hollow uveal effusion (PMID20159229))



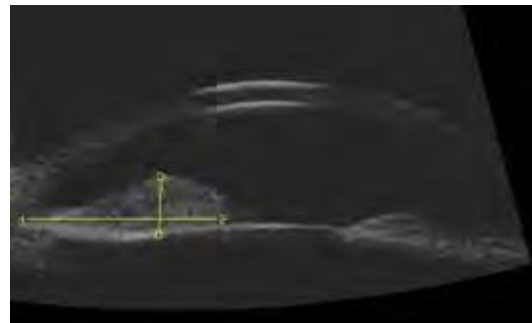
Transverse B-scan of a temporal choroidal melanoma in the right eye, taken with the patient looking to the right

The types of ultrasonography include:

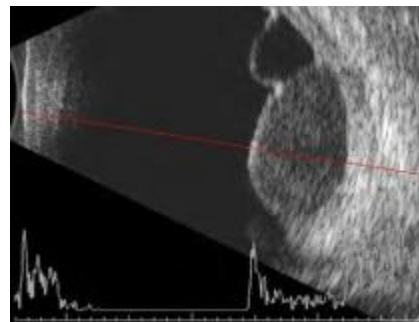
- A-scan ultrasonography, with a stationary transducer, which produces a parallel, one-dimensional beam. Standardized ultrasonography uses an 8 MHz probe, calibrated with a model eye.
- B-scan ultrasonography, performed with an oscillating transducer, which produces a two-dimensional beam focused near the retina.
- High-frequency ultrasonography, also called 'ultrasound biomicroscopy', which defines structures anterior to the ora serrata. (PMID16024841)
- Doppler ultrasonography, which demonstrates blood flow (e.g., helping to distinguish tumor from hemorrhage).
- Three-dimensional imaging, which can enhance tumor volume measurements.



B-scan ultrasound showing a choroidal tumor with a mushroom shape, which is almost pathognomonic of melanoma. Note the high reflectivity in the edematous intra-retinal part of the tumor and the low reflectivity in the compact, intra-choroidal part of the lesion.



High-frequency scan of an iris melanoma.



A- and B-scans of a choroidal tumor

METHODS:

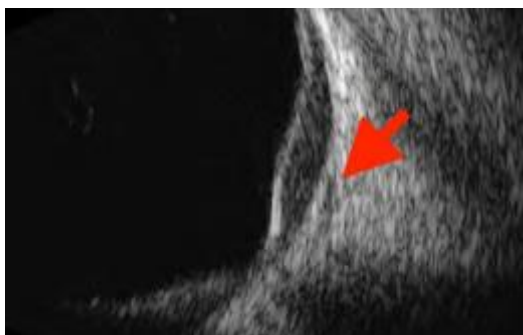Scans are longitudinal, transverse, oblique, and axial, obtained by tilting, sliding and twisting the probe.

- When searching for a tumor (e.g., with opaque media) start at the macula, with the probe touching the limbus, then slide the probe tip to the equator of the eye while tilting it to screen the eye as far anteriorly as ciliary body. Do this in all cardinal directions of gaze, with longitudinal and transverse scans.
- To scan an eccentric tumor, ask the patient to look in the direction of the tumor (e.g., to the left if the lesion is located temporally in the left eye). This is so that the probe is perpendicular to the tumor, making the internal scleral surface visible.
- Reduce the gain as much as possible, to improve resolution.
- When measuring tumor thickness, ensure that the probe is at right angles to the tumor, that the thickest point is measured, and that the calipers are placed at the internal scleral surface and tumor apex, taking account of any retinal detachment.
- Measure the largest, longitudinal, and transverse basal dimensions. Take care not to over-estimate tumor size in the presence of retinal detachment and not to under-

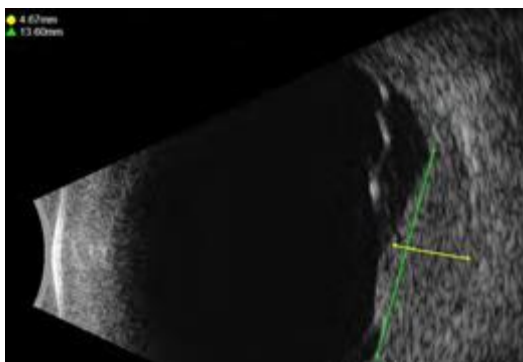
estimate basal diameter if the tumor margins are tapering.

- Assess internal tumor spread (e.g., from choroid to retina and vitreous).
- Look for extraocular tumor spread, taking care to differentiate tumor from muscle.
- Assess internal acoustic reflectivity noting whether the reflectivity is low, medium or high (compared to retro-ocular fat) and regular or irregular. It is useful to identify spontaneous movement (e.g., shimmering caused by blood flow).
- Look for echo mobility by asking the patient to look from side to side as the scan is taken.
- Assess the vitreous, by increasing the gain.
- Document the eye whether the scan is longitudinal, transverse or oblique.

When comparing sequential measurements, consider measurement variation and look for a trend over several weeks or months before deciding whether the tumor is growing or regressing. As a general principle, thickness must change by more than 0.5 mm to be significant.



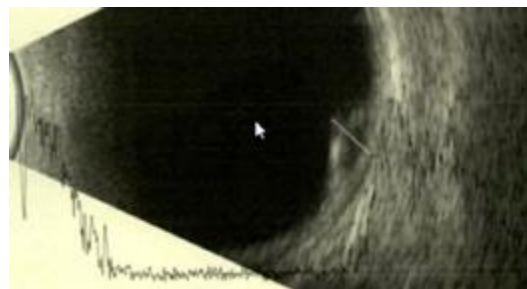
Extraocular extension of a choroidal lymphoma. Note the low internal acoustic reflectivity, which helps distinguish this tumor from diffuse choroidal hemangioma



B-scan of a choroidal hemangioma, showing a high internal acoustic reflectivity



B-scan of a choroidal metastasis, showing a moderate internal acoustic reflectivity



Exaggerated measurement of tumor thickness in a B-scan, because the referring ophthalmologist has included the sclera and retina in the measurement.

TUMOR BIOPSY

Ocular tumor biopsy has several indications. (PMID 35941182) It is performed to to:

- Establish the diagnosis if ocular examination and imaging are inconclusive (e.g., to differentiate between amelanotic choroidal melanoma and metastasis or between conjunctival squamous or sebaceous gland carcinoma and melanoma).
- Confirm the suspected diagnosis if requested by the patient (e.g., if treatment of a small, juxtapapillary choroidal melanoma is likely to cause severe visual loss). Some oncologists and radiotherapists insist on histological proof before starting treatment (e.g., vitreoretinal lymphoma, solitary intraocular metastasis without any evidence of other systemic disease).
- Characterize the type of uveal metastasis, in the absence of any detectable systemic primary tumor, so that investigations can be targeted accordingly.
- Detect genetic abnormalities related to metastatic spread from uveal melanoma (e.g., *BAP1* immunohistochemistry).
- Determine the severity of atypia in primary acquired melanosis, to decide whether to administer topical chemotherapy.
- Define the depth of invasion of a conjunctival tumor (e.g., melanoma), to

decide whether adjunctive radiotherapy is needed.

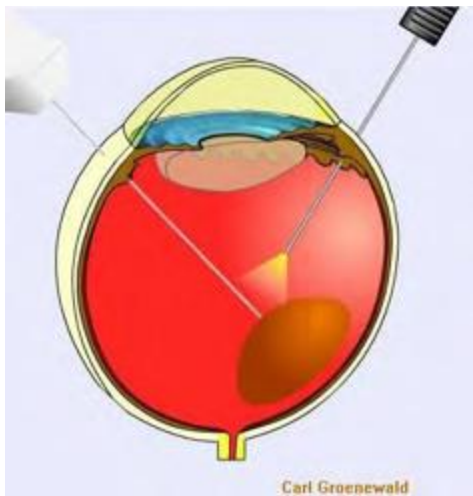
- Detect regional metastases in patients with high-risk conjunctival tumors, by performing sentinel lymph node biopsy.

Biopsy is contra-indicated in eyes with suspected retinoblastoma, because of a high risk of seeding tumor cells into the orbit.

EXCISIONAL BIOPSY

This is the preferred technique for any nodular conjunctival tumors. A no-touch technique is used. The instruments are replaced with a fresh set for wound closure, to prevent tumor seeding. Care is taken not to cause crush artefact.

Excisional biopsy is also useful for some uveal tumors if tumor removal is likely to be an effective treatment irrespective of the diagnosis (e.g., when it is not possible to differentiate between ciliary body melanoma, adenocarcinoma, neurilemmoma, etc.).



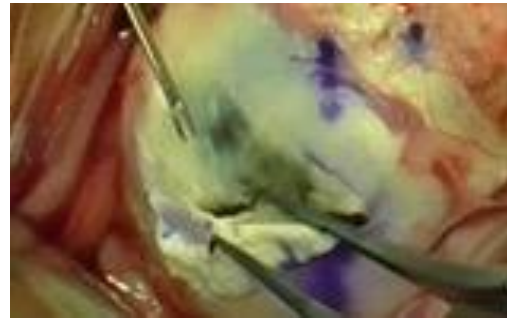
Trans-retinal aspiration biopsy of a choroidal tumor with a vitreous cutter

INCISIONAL BIOPSY

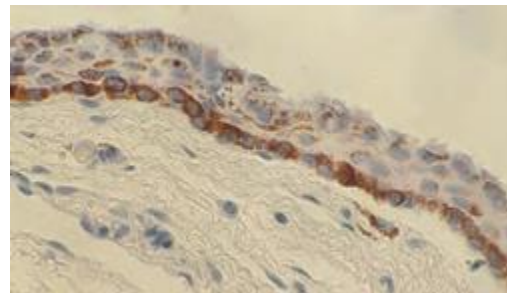
This is indicated for diffuse conjunctival disease, such as primary acquired melanosis (PAM), both at initial presentation and, if recurrence is suspected, after treatment. Incisional biopsy of nodular tumors, such as melanoma, is contra-indicated because this procedure can seed tumor cells to adjacent tissues, giving rise to multiple recurrences, which may be difficult or

impossible to control, except by exenteration. Care is taken not to cause crush artefact.

Incisional biopsy of uveal tumors, ideally with Essen Forceps, can be performed under a lamellar scleral flap, using tissue glue to seal the wound to prevent extraocular recurrence.



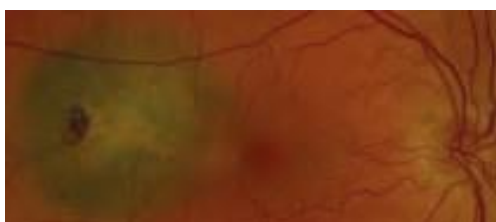Trans-scleral tumor biopsy with Essen Forceps



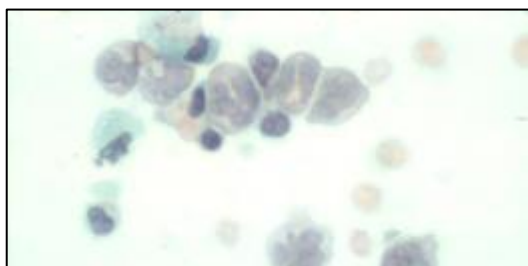
Incisional conjunctival biopsy showing an increased number of melanocytes. These show no cellular features of malignancy (i.e., no 'atypia') and are not invading the superficial layers of the epithelium. This biopsy made it possible to discharge the patient without any topical chemotherapy

ASPIRATION BIOPSY

Fine-needle aspiration biopsy of intraocular tumors is performed trans-sclerally or trans-retinally, depending on the location of the lesion. The use of a vitreous cutter provides larger samples and in some centers is performed without vitrectomy, laser or tamponade. Suspected vitreoretinal lymphoma requires a large, undiluted sample of vitreous and rapid transfer to the laboratory unless a transport medium is used.



Choroidal melanoma, confirmed by trans-retinal biopsy with a vitreous cutter



Vitreous biopsy showing lymphoma cells with large, multilobular nuclei

The main risks are vitreous hemorrhage, which usually resolves spontaneously, and failure to achieve a result, because of an insufficient sample or technical difficulties in the laboratory. Subconjunctival seeding of uveal melanoma can rarely occur unless cryotherapy is administered. Biopsy is not believed to cause metastasis of uveal melanoma.

CONJUNCTIVAL IMPRINT CYTOLOGY

This does not provide information about the depth of tumor spread and is not widely used.

LIQUID BIOPSY

Research is in progress to analyze blood samples instead of tumor tissue specimens (e.g., to detect circulating DNA predicting metastasis from uveal melanoma).

It is essential to liaise with the laboratory in advance of any biopsy to ensure that the correct transport medium is used. This is especially important with vitreoretinal lymphoma, because of the need to process the sample without delay.

In patients with retinoblastoma, analysis of cell free DNA in aqueous humor can identify the

causative RB1 mutation as well as secondary genetic aberrations that are associated with ocular and systemic prognosis. This is especially useful when tumor tissue is not available because the patient has not undergone enucleation.

COMPUTERIZED TOMOGRAPHY (CT)

The indications for CT are limited as far as uveal tumors are concerned, because US is usually adequate. For example, although CT nicely demonstrates bone in a choroidal osteoma, similar information can be obtained less expensively and more conveniently with US.

MAGNETIC RESONANCE IMAGING (MRI)

Magnetic resonance imaging with fat suppression and contrast agent can be useful in selected cases.

Melanin has peculiar paramagnetic features, being hyperintense and hypointense with respect to vitreous in T1 and T2 images respectively; however, as mentioned, not all melanocytic tumors are melanoma and not all melanomas are pigmented.

With conjunctival tumors, MRI scans may detect or define orbital spread. Some find contrast-enhanced MRI useful in differentiating eccentric disciform from melanoma.

OCULAR TUMORS

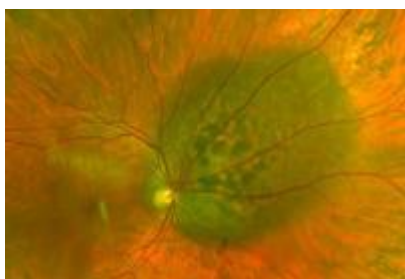UVEAL MELANOMA

About 90% of all uveal melanomas involve the choroid, the remainder being confined to ciliary body and/or iris. (PMID 32273508)
Presentation peaks at around the age of 60 years and is rare before adulthood. Men and women are affected in similar numbers.

CLINICAL FEATURES

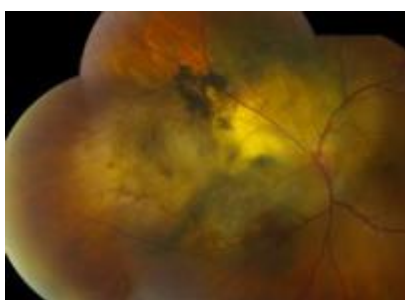
Choroidal melanoma

- Dome shape in most patients, with brown/grey color from multilayering of the RPE, which can also show drusen and clumps of lipofuscin. This pigment appears orange over pigmented tumors and brown over amelanotic tumors. Where the RPE is absent, the tumor itself is white, yellow, tan, brown, grey or black, with visible blood vessels if the tumor is amelanotic.



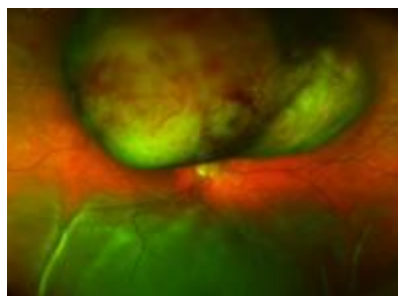
Choroidal melanoma involving disc

- Mushroom shape, if the tumor has grown through RPE and Bruch's membrane, which strangulates the tumor veins, causing edema and tissue swelling.
- Diffuse growth if the tumor is infiltrative, often with extraocular extension by the time the diagnosis is made.



Diffuse choroidal melanoma

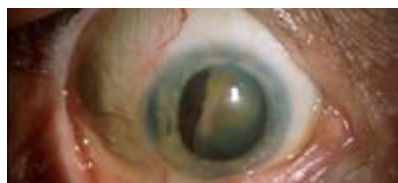- Exudative retinal detachment, initially only over the tumor surface, eventually becoming total.



Large, amelanotic choroidal melanoma with bullous serous detachment

Ciliary body melanoma

- The tumor can have a dome shape or can grow circumferentially. It can be pigmented or amelanotic.
- The overlying episcleral vessels are usually dilated ('sentinel vessels').

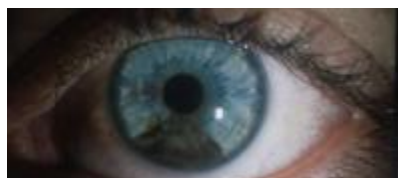


Ciliary body melanoma invading anterior chamber. Note the sentinel vessels.

- As with choroidal tumors, ciliary body melanomas can cause retinal detachment.
- Pressure on the lens can cause astigmatism and cataract.
- The tumor can spread into the anterior chamber or extraocularly to appear under the conjunctiva.

Iris melanoma

- The tumor can be nodular or diffuse and pigmented or amelanotic.
- Almost all are inferior.
- Spread around the angle can cause glaucoma. Gonioscopy is essential.

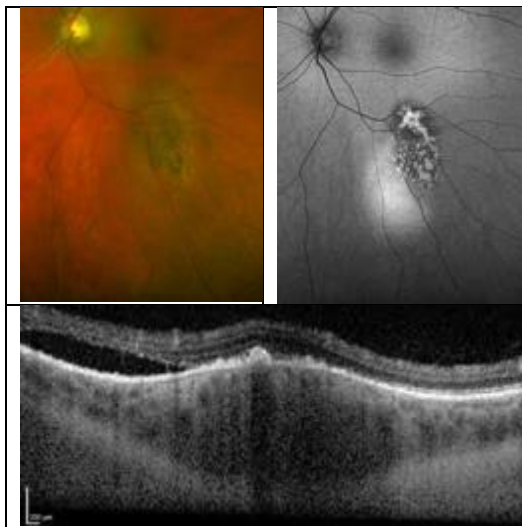


Iris melanoma

CLINICAL INVESTIGATIONS

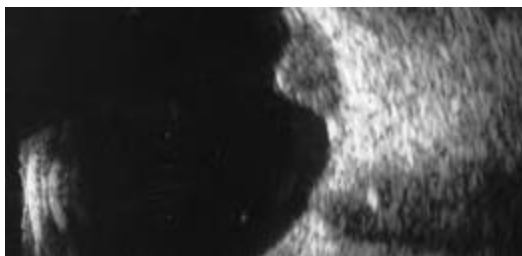Choroidal melanoma

- Fluorescein angiography does not usually assist diagnosis.
- Autofluorescence imaging shows hyper-autofluorescent lipofuscin and hypo-autofluorescence where the RPE is absent.
- Optical coherence tomography reveals serous retinal detachment and intra-retinal edema; measures thickness more accurately than ultrasound in small tumors; and helps distinguish drusen from lipofuscin.



Inferior choroidal melanoma in the left eye with orange pigment on its surface. Autofluorescence imaging shows hyper-autofluorescent lipofuscin. OCT shows the tumor, with subretinal fluid and clumps of lipofuscin on the retinal side of the RPE. OCT also indicates the tumor thickness.

- Ultrasonography shows the tumor shape (i.e., dome, mushroom or diffuse) and reveals any extraocular spread (which must not be confused with oblique muscle). The internal acoustic reflectivity is low, except for tumor that has grown through RPE.



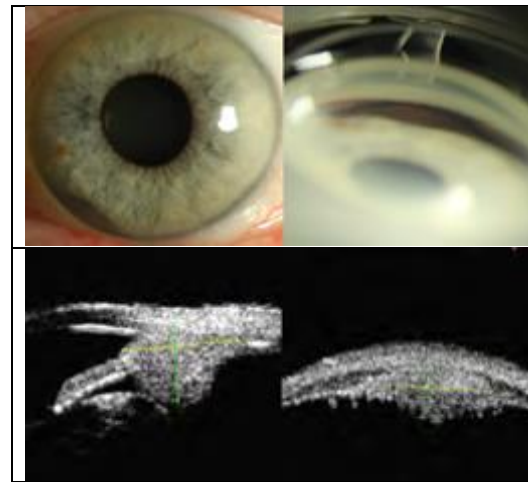
B-scan ultrasound of a choroidal melanoma showing low acoustic reflectivity

- Indocyanine green angiography, computerized tomography, and magnetic resonance imaging are rarely required.

- Trans-scleral or trans-retinal biopsy is useful when the diagnosis is uncertain.

Ciliary body melanoma

- Transillumination shows the circumferential extent of the tumor.
- Ultrasonography can reveal small ciliary body melanomas that are not visible by ophthalmoscopy, even with mydriasis. High-frequency ultrasonography may be needed.
- Gonioscopy is useful to exclude anterior chamber spread.



Ciliary body melanoma invading anterior chamber, defined with slit-lamp photograph, gonioscopy, and longitudinal and transverse ultrasound B-scans

- If diagnostic biopsy is necessary, this can be done trans-sclerally, either with a fine needle or with Essen Forceps, under a lamellar scleral flap.

Iris melanoma

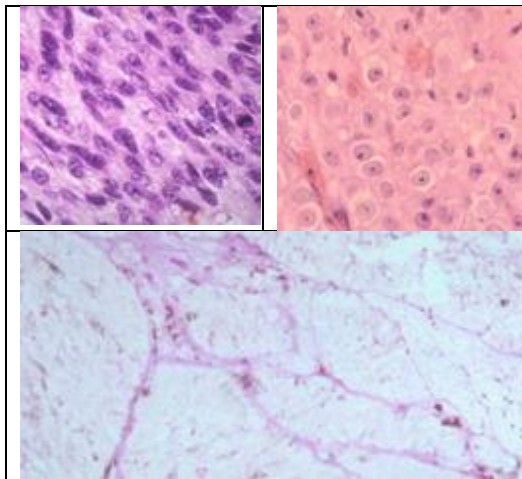
- High-frequency ultrasonography is useful for measuring tumor dimensions and excluding ciliary body involvement .
- Incisional biopsy may differentiate melanoma from nevus in some cases.

LABORATORY INVESTIGATIONS

Histopathology

- The melanoma cell type can be spindle, epithelioid, or mixed. Epithelioid cells are associated with an increased risk of metastasis.
- When the entire tumor is available for analysis (e.g., after enucleation or local resection) the mitoses per high-power field indicates of tumor growth rate and risk of metastasis.

- Extravascular matrix in the tumor stroma can form a variety of patterns, such as closed loops, which indicate a worse prognosis.
- Immunohistochemistry using stains such as Melan-A confirms the diagnosis of melanoma. Nuclear *BAP1* staining has been found to be a useful prognostic tool, with nuclear *BAP1* loss associated with metastasis. (PMID 25058347)



Light micrographs of choroidal melanomas showing spindle and epithelioid melanoma cells and closed loops

Genetic aberrations

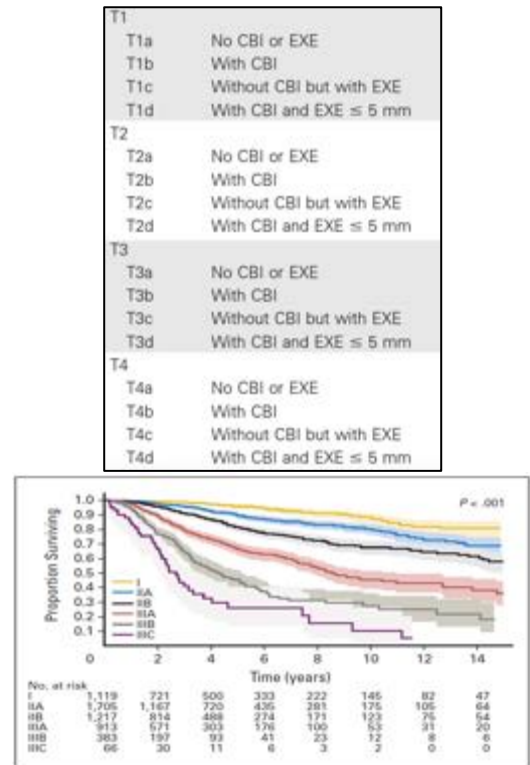
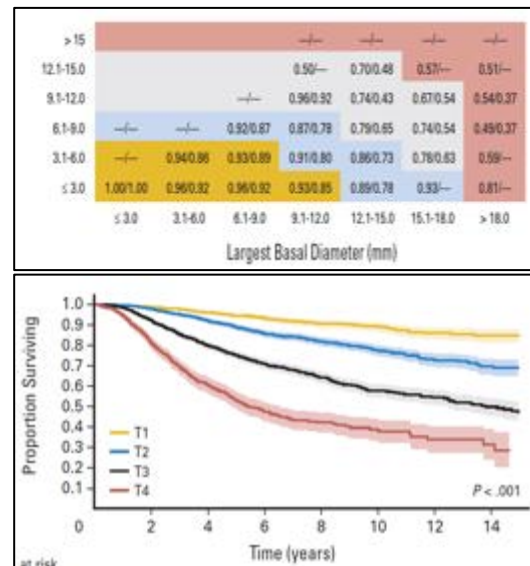
Genetic aberrations in the tumor itself profoundly influence prognosis. (PMID34771666) The sensitivity of genetic testing has improved with methods such as next generation sequencing. (PMID 31024753)

- Metastatic disease develops almost exclusively in patients whose uveal melanoma shows chromosome 3 loss ('monosomy 3'), especially with 8q gain. 6p gain and *EIF1AX* mutation are associated with a better prognosis.
- *BAP1* mutation indicates a high risk of metastasis.
- SF3B1 is associated with late metastases in some patients.
- In the US, uveal melanomas are classified according to their gene expression profile, with class 2 tumors having a worse prognosis.
- Patients who are young or who have a family history of uveal melanoma, skin melanoma, renal cancer or mesothelioma are referred to a geneticist to exclude the *BAP1* tumor predisposition syndrome.


SURVIVAL PROGNOSTICATION

The risk of metastatic disease is estimated according to clinical, histological and genetic predictors. (PMID 21658465)

- The tumor, Node, Metastasis (TNM) staging system predicts metastatic death according to tumor thickness, basal diameter, ciliary body involvement and extraocular spread. (PMID 33738986, 23816968)



- The Liverpool Uveal Melanoma Prognosticator Online (LUMPO) (www.LUMPO.net), developed by Damato and associates in Liverpool, predicts survival according to the TNM predictors as well as melanoma cell type, mitotic count, extravascular matrix patterns, chromosome 3 loss, and chromosome 8q gain, also taking into account the patient's age and sex. (PMID 32085617)



LUMPO screenshot, showing survival plots, TNM stage, and estimates of metastatic and non-metastatic mortality. (Currently not available in Europe until a CE Mark is obtained)

- Gill et al have report good prognostic results with a score determined by sex, age, TNM stage, chromosome 3 loss and 8q gain.
- Damato et al have also developed tables predicting metastatic death according to tumor diameter, chromosome 3 loss and age. (PMID 32334433)

DISOMY-3 MELANOMA							
LBDT [mm]	Treatment age <81 yrs			Treatment age >80 yrs			
	Years after treatment			Years after treatment			
	2	5	10	2	5	10	
<10.1	0.1 [0, 0.5]	0.7 [0, 1.6]	2.1 [0.7, 4]	<10.1	0.1 [0, 0.5]	0.6 [0, 1.4]	1.4 [0.4, 2.6]
10.1-12.0	0.8 [0.2, 1.7]	1.7 [0.5, 3.4]	3.7 [1.5, 6.7]	10.1-12.0	0.7 [0.1, 1.6]	1.5 [0.5, 3]	2.7 [1.1, 4.8]
12.1-14.0	1.1 [0, 2.5]	3.3 [1, 6]	6.5 [2.7, 11]	12.1-14.0	1 [0, 2.4]	2.9 [0.9, 5.3]	4.9 [2, 8.3]
14.1-16.0	1.5 [0, 4]	5.3 [1.8, 9.6]	11 [4.9, 18]	14.1-16.0	1.5 [0, 3.8]	4.6 [1.6, 8.4]	8 [3.7, 13]
16.1-18.0	3.1 [0, 8.7]	12 [5.1, 21]	17 [8, 28]	16.1-18.0	2.9 [0, 8.3]	11 [4.5, 19]	14 [6.5, 22]
18.1-28.0	6 [0, 14]	12 [2.4, 25]	18 [6.2, 32]	18.1-28.0	5.7 [0, 14]	11 [2.3, 22]	15 [4.6, 26]

MONOSOMY-3 MELANOMA							
LBDT [mm]	Treatment age <81 yrs			Treatment age >80 yrs			
	Years after treatment			Years after treatment			
	2	5	10	2	5	10	
<10.1	2.5 [0.6, 5.2]	13 [6.4, 21]	26 [13, 41]	<10.1	2.4 [0.5, 5]	11 [5.5, 18]	19 [9.6, 30]
10.1-12.0	5 [2.2, 8.4]	20 [12, 28]	37 [22, 51]	10.1-12.0	4.8 [2.1, 8.1]	18 [11, 25]	28 [17, 38]
12.1-14.0	8 [4.9, 12]	33 [24, 42]	53 [38, 65]	12.1-14.0	7.9 [4.7, 12]	29 [21, 37]	42 [30, 51]
14.1-16.0	13 [9.2, 18]	42 [35, 50]	66 [55, 75]	14.1-16.0	13 [8.8, 17]	37 [30, 44]	52 [43, 60]
16.1-18.0	21 [16, 27]	59 [51, 67]	77 [67, 85]	16.1-18.0	20 [15, 26]	53 [46, 61]	64 [56, 71]
18.1-28.0	32 [26, 38]	70 [63, 78]	80 [73, 87]	18.1-28.0	31 [25, 37]	64 [54, 71]	77 [64, 77]

UNKNOWN CHROMOSOME 3 STATUS							
LBDT [mm]	Treatment age <81 yrs			Treatment age >80 yrs			
	Years after treatment			Years after treatment			
	2	5	10	2	5	10	
<10.1	0.6 [0.2, 1.1]	3.1 [2.1, 4.2]	6.6 [5, 8.3]	<10.1	0.6 [0.2, 1]	2.7 [1.8, 3.6]	4.7 [3.6, 6]
10.1-12.0	2 [1.2, 3]	7 [5.3, 8.9]	13 [10, 15]	10.1-12.0	1.9 [1.1, 2.9]	6.1 [4.6, 7.8]	9.7 [7.8, 12]
12.1-14.0	4 [2.6, 5.4]	15 [13, 18]	25 [21, 28]	12.1-14.0	3.8 [2.5, 5.1]	14 [11, 16]	19 [17, 22]
14.1-16.0	7.9 [5.7, 10]	25 [22, 30]	41 [36, 45]	14.1-16.0	7.6 [5.5, 9.8]	22 [19, 26]	32 [28, 36]
16.1-18.0	15 [11, 19]	43 [37, 48]	55 [50, 61]	16.1-18.0	14 [11, 18]	38 [33, 43]	46 [41, 51]
18.1-28.0	25 [21, 30]	56 [50, 62]	65 [59, 70]	18.1-28.0	24 [20, 29]	51 [45, 56]	56 [51, 62]

TREATMENT

Plaque Brachytherapy

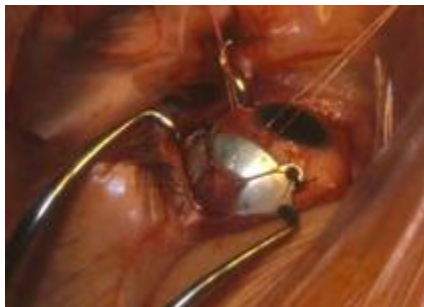In most centers, the first choice of treatment is brachytherapy, which is administered with a radioactive plaque containing ruthenium-106 or iodine-125, popular in Europe and the US respectively. (PMID 29844657, 29538180) At St Erik Eye Hospital, both these plaques are available. Brachytherapy involves an operation to suture the plaque to the sclera over the tumor and a second operation, a few days later, to remove the plaque once the prescribed radiation dose has been delivered.

Iodine plaques emit gamma irradiation and can successfully treat tumors as thick as 10 mm; however, they deliver large doses of radiation to healthy ocular structures, such as the optic disc, causing collateral damage.

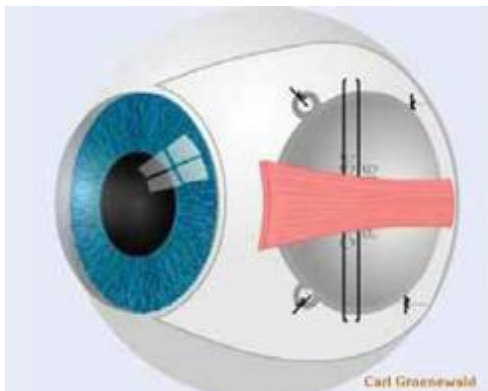
Our first choice of radiotherapy for choroidal melanomas up to 5 mm in thickness is ruthenium plaque radiotherapy. (Damato is a consultant for Bebig, Eckert & Ziegler.)

To reduce collateral damage to optic disc and fovea, the plaque can be placed eccentrically, with its posterior edge close to the posterior tumor margin. This requires accurate plaque

insertion, which can be achieved using a right-angled transilluminator and a perforated template, designed by Damato, produced by Altomed Ltd, UK., and distributed by Eckert and Ziegler, Germany. The surgeon slides the tip of the transilluminator down the groove until it clicks into the perforation, then performs binocular indirect ophthalmoscopy to locate and move the spot of light in relation to the tumor margin, either before suturing the template to the sclera ('sunrise test') or afterwards ('sunset test').



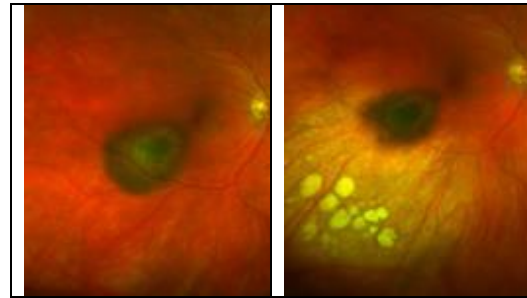
Ruthenium plaque placed over a temporal choroidal melanoma in the right eye, under the lateral rectus muscle.



Ruthenium plaque with mattress suture



Ruthenium plaque template and right-angled transilluminator (not to scale), designed by Damato and manufactured by Altomed, Boldon, UK.



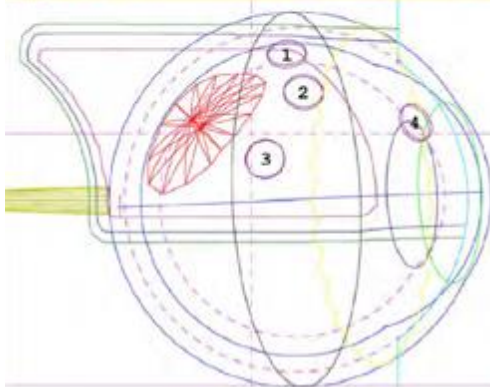
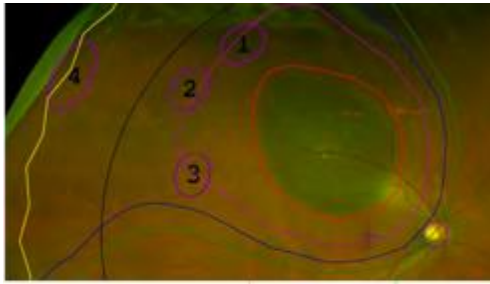
Choroidal melanoma before and after ruthenium plaque radiotherapy by Damato. The plaque was placed eccentrically, with its posterior edge aligned with the posterior tumor margin to conserve central vision. The treated tumor developed a dark, moth-eaten appearance. With a scleral dose of 350 Gy, the tumoricidal effects of the radiation extend about 2 mm beyond the visible area of choroidal atrophy.

Proton beam radiotherapy

Proton beam radiotherapy enables a high dose of radiation to be aimed precisely at a uveal melanoma irrespective of the tumor's size, shape and location. (PMID24227980)

Facilities for this treatment are available in a growing number of centers around the world. Some oncologists use proton beam radiotherapy for all choroidal melanomas; others reserve it for tumors that cannot adequately be treated by brachytherapy, that is, tumors that are large or those that extend close to the optic disc or fovea.

The treatment involves (1) ultrasound measurements of tumor dimensions and distance from disc; (2) insertion of tantalum markers at known distances from tumor margins, from each other, and from limbus; (3) 3-D computer modeling of the eye and tumor, using the ultrasound and intra-operative measurements and x-rays of the tantalum markers; (4) preparation of a tight-fitting face mask and dental bite to immobilize the head during treatment; and (5) proton beam radiotherapy, delivered once a day over four consecutive days.



Fundus photo and computer-generated model showing the tumor, tantalum markers and dosimetry.

Proton beam radiotherapy of large uveal melanomas is often complicated by persistent exudative retinal detachment, rubeosis and neovascular glaucoma. This condition, which Damato has termed 'toxic tumor syndrome', can be treated successfully by treating the irradiated tumor with photodynamic therapy, transpupillary thermotherapy, trans-retinal endoresection or trans-scleral exoresection. In some cases, this problem can be prevented by anti-angiogenic therapy.

Proton beam radiotherapy of medial tumors can cause permanent epiphora if the tear ducts are included in the radiation field. Irradiation of the superior eyelid margin results in keratinization of the superior tarsal conjunctiva and painful corneal abrasion. This problem can be avoided by treating superior tumors through closed eyelids, so that the lid margin is out of the radiation field.

In 1994, it was found that iris melanomas can be treated satisfactorily with proton beam radiotherapy, thereby avoiding the problems of iridectomy and iridocyclectomy. The main problems are cataract, which is eminently treatable, and glaucoma.

Stereotactic radiotherapy

With stereotactic radiotherapy, a highly collimated beam of radiation is aimed at the

tumor from many different directions, either simultaneously or in sequence, so that a high dose of radiation is delivered to the melanoma with relative sparing of healthy tissues. (PMID32969745, 28849326)

This approach is generally used as an alternative to proton beam radiotherapy, in centers where a cyclotron unit is not available.

Photocoagulation

Photocoagulation of uveal melanoma with high-energy light is associated with a high complication rate and has been superseded by transpupillary thermotherapy.

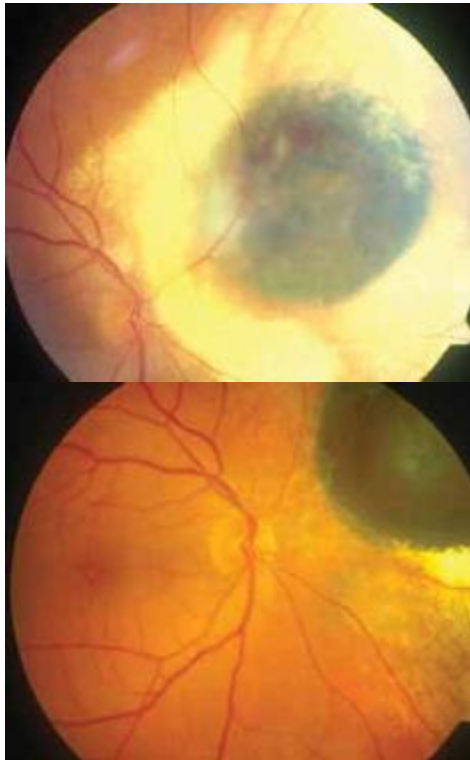
Transpupillary thermotherapy (TTT)

With transpupillary thermotherapy, the tumor is heated by a few degrees for about one minute by means of a 3 mm diode laser beam, administered using a contact lens. (PMID25439431) The power of the laser is adjusted so that retinal blanching does not develop for at least 40 seconds.

The effects of transpupillary thermotherapy are said to extend to a depth of up to 4 mm. Adjunctive brachytherapy is advocated as a means of avoiding local tumor recurrence from intra-scleral tumor (i.e., 'sandwich technique').

Transpupillary thermotherapy alone is associated with a high rate of local tumor recurrence and is not administered as a primary treatment for choroidal melanoma unless (1) the patient has a limited life expectancy, (2) the patient is diabetic (so that there is an increased risk of radiation retinopathy), has a small tumor and accepts that TTT is not as reliable as radiotherapy, or (3) the patient has an indeterminate melanocytic choroidal tumor but does not accept monitoring after being informed of uncertainty regarding the risks of such management.

We generally perform TTT only as a secondary treatment after radiotherapy (1) if there is uncertainty about adequacy of radiotherapy, or (2) as a treatment for exudation, either at the time of presentation or when exudation develops after treatment.



Exudation from an irradiated choroidal melanoma, with resolution after transpupillary thermotherapy of the 'toxic tumor'

Photodynamic therapy (PDT)

Photodynamic therapy using Verteporfin is associated with a high failure rate. (PMID32890790) This treatment is generally reserved for: (1) 'leaking nevi'; (2) exudation or macular edema after radiotherapy; and (3) selected, small melanomas when other methods are likely to cause visual loss and when the patient accepts that radiotherapy may be required for persistent or recurrent tumor. Aura biosciences has developed AU-011, which is injected into the vitreous and which is activated by laser. (PMID 29242243) At the time of writing this guide, the results of clinical trials are still awaited.

Cryotherapy

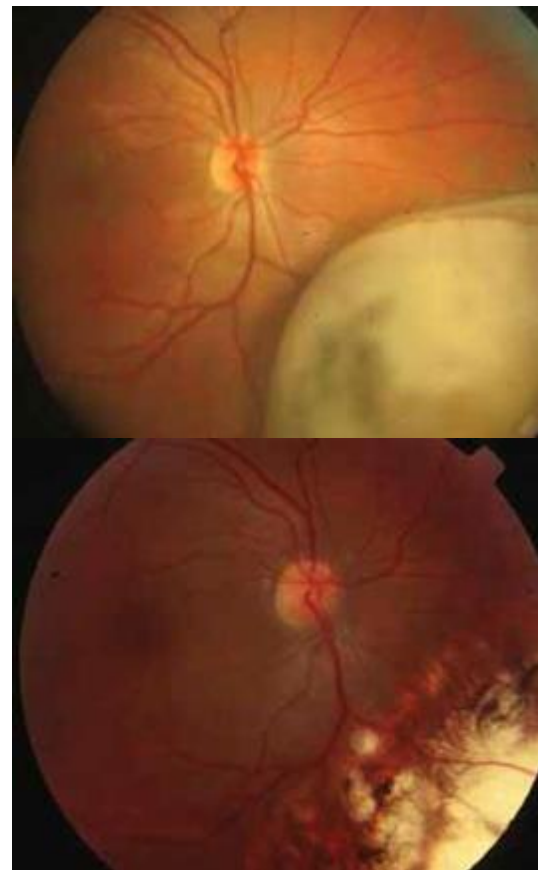
Cryotherapy has been reported to be effective for some choroidal melanomas; however, this form of therapy has not gained widespread acceptance.

Trans-Scleral Local Resection (Exoresection)

Exoresection comprises iridectomy, iridocyclectomy and choroidectomy. (PMID 20456258, 24722505, 22042014) Excision of small, ciliary body melanomas has been performed for many years. Advances in microsurgery and hypotensive anesthesia have also made it possible to remove large tumors

extending as far posteriorly as the fovea. This operation is difficult and therefore performed only in a few centers, where it is reserved for tumors that are considered too large for radiotherapy.

The main complications are local tumor recurrence and rhegmatogenous retinal detachment. Tumor control has improved with adjunctive brachytherapy and by restricting this surgery to tumors less than 17 mm in diameter. Surgical refinements have reduced the incidence of retinal tears. In the event of a retinal break, immediate vitreoretinal surgery at the end of the local resection is highly successful at preventing retinal detachment.



Choroidal melanoma (13 x 11 x 7 mm) before and after trans-scleral local resection by the author. Eighteen years post-operatively, the vision was 6/5 and there was no recurrence.

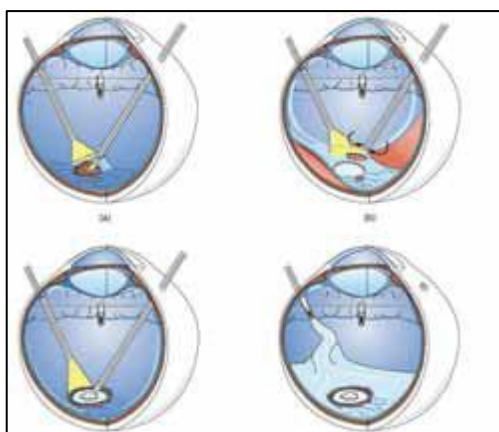
Endoresection

With endoresection, the uveal melanoma is removed with a vitreous cutter, either through a hole in the retina or after raising a retinal flap. (PMID 24169650) This is performed under heavy liquid. After tumor removal, endolaser is administered to kill any residual tumor and to achieve retinopexy. The eye is filled with silicone, which is removed after 12 weeks,

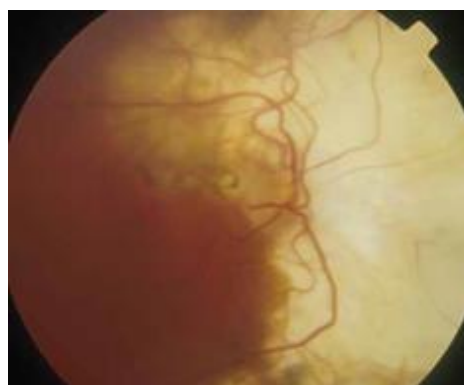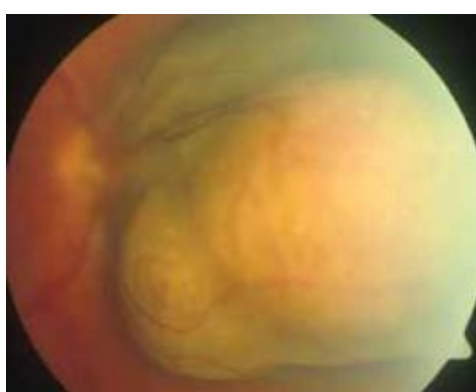
when epiretinal membrane peel and phaco are performed, with lens implant.

Some administer neoadjuvant radiotherapy (i.e., before the endoresection and some prescribe adjuvant radiotherapy (i.e., after the endoresection).

Most complications have been caused by the vitrectomy (e.g., entry-site tears and not the endoresection itself. Following a fatal case of air embolism, fluid-air-silicone oil exchange was replaced by direct heavy liquid-silicone oil exchange but even this procedure has been followed by sudden deaths from gas embolism soon after the operation, probably caused by vaporization of the heavy liquid, perfluoro-n-octane, when this enters the general circulation. (PMID 35352011)



Endoresection of choroidal melanoma



Choroidal melanoma (11 x 10 x 7 mm) in the right eye of a 65-year-old man before and after endoresection by Damato. The vision in the left eye was poor because of trauma. Five years postoperatively the vision in the treated eye was 6/9 and there was no recurrence

Enucleation

Primary enucleation for uveal melanoma is now performed only when other methods are considered unlikely to conserve the eye and useful vision.

The enucleation is performed in the standard fashion, using the surgeon's preferred implant. Non-porous implants give the same results as porous implants but are less expensive and easier to remove if they become exposed. (PMID27861329) To ensure that the correct eye is removed, the tumor is visualized by binocular indirect ophthalmoscopy, which is done *after* draping the patient and covering the other eye, in accordance with WHO standards.

Studies by Damato and associates show that quality of life after enucleation is not significantly worse than after radiotherapy if the visual acuity in the fellow eye is good. (Pubmed29555484, 31768363) Poor quality of life occurs only in about 20% of patients, in whom loss of well-being is caused by factors unrelated to the ocular tumor or its treatment (e.g., poor social support, poor general health, financial difficulties, etc.)

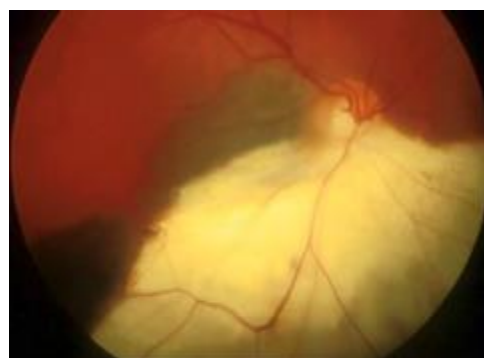
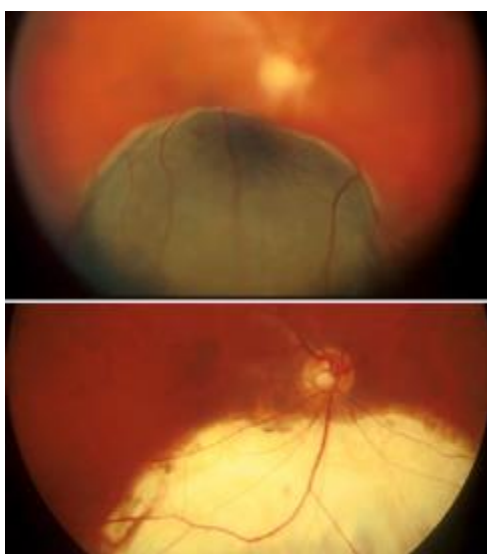OCULAR RESULTS OF CONSERVATIVE THERAPY

The ocular results of conservative therapy are usually reported in terms of local tumor control, visual acuity, ocular conservation and complications such as exudative or rhegmatogenous retinal detachment, neovascular glaucoma, cataract and phthisis.

Clinical features predicting ocular outcomes include>

- Largest basal tumor diameter.
- Tumor thickness.
- Distances to optic disc and fovea.
- Retinal invasion.
- Extra-ocular spread.
- Exudative retinal detachment.
- Systemic factors such as diabetes, which aggravate visual outcome after radiotherapy.
- The degree of tumor malignancy, as indicated by cell type and mitotic count, which is important but not usually known at the time of primary treatment.
- It is not known whether genetic aberrations influence ocular outcome; however, if genetic predictors of metastasis are known to be present (e.g., if biopsy has been performed before treatment), then more aggressive therapy may be administered (e.g., selecting radiotherapy instead of photodynamic therapy). This would avoid patients or their relatives attributing any metastatic disease on any failure of local tumor control (even if there is no firm evidence that such a complication influences survival).

To a large extent, ocular outcomes after treatment of uveal melanoma are determined by the success with which any side effects and complications are managed (e.g., macular edema after radiotherapy, rhegmatogenous retinal detachment after endoresection).



Local recurrence three years after trans-scleral resection performed in 1992. The patient required enucleation.

METASTATIC DISEASE FROM UVEAL MELANOMA

Before ocular treatment, it is conventional practice to screen all patients with uveal melanoma for systemic metastases, by performing a liver scan, chest x-ray, and liver function tests. Some oncologists reserve such screening for patients with a large tumor (i.e., basal tumor diameter >16 mm) and/or any suspicious symptoms (i.e., abdominal pain, weight loss, anorexia, etc.).

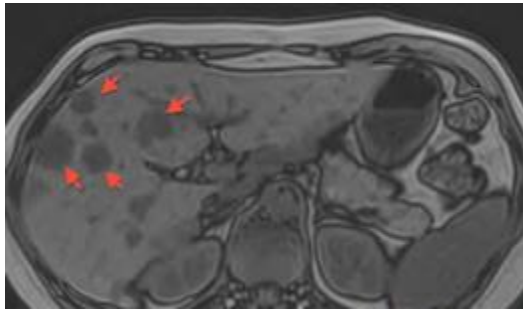
See section on 'Systemic Surveillance for Metastatic Disease' later in this document.

Treatment

Treatment for metastases from uveal melanoma is usually disappointment, although there has been some improvement recently. (PMID 36600005)

Metastases from uveal melanoma have a low mutation rate so that they are less immunogenic and therefore less responsive to immune checkpoint inhibitors than cutaneous melanomas, except perhaps in patients with very early detection of hepatic metastases.

Encouraging results have been reported with Tebentafusp (Immunocore, Abingdon, UK), which links the patient's own T-cells with melanoma cells. (Damato is a consultant for Immunocore Ltd.).



MRI scan showing hepatic metastases from uveal melanoma

Chemosaturation therapy involves perfusion of the liver with melphalan, through the hepatic artery, with hepatic vein isolation and extraction of the drug with a CHEMOSAT® (Delcath, NY, USA) filter to reduce systemic toxicity.

Prolonged survival can occur after surgical resection of isolated hepatic metastases.

COUNSELLING

There is growing awareness of the psychological morbidity that patients and their relatives experience and these issues are increasingly being addressed more fully.

The specialist ocular oncology nurse also plays an important role, for example: (a) speaking to each patient immediately after the initial consultation; (b) visiting all patients in the ward; (c) telephoning every patient a few days after discharge from hospital; (d) providing a telephone helpline; and, on request, (e) arranging for new patients to speak to similar patients who have previously had the same treatment.

CHOROIDAL NEVUS

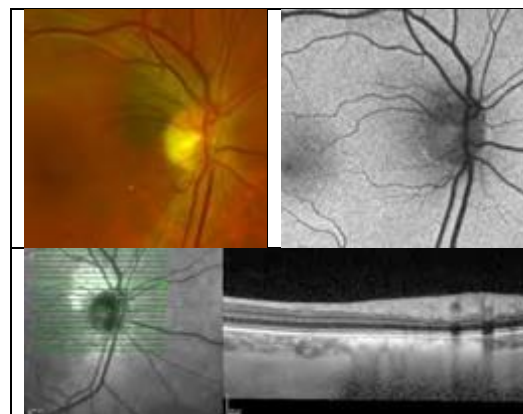
Choroidal nevi are reported to occur in about 5 to 10 percent of the population, with about 90 percent developing posterior to the equator.

It can be difficult for non-specialists to differentiate choroidal nevi from melanomas. Damato has therefore developed the MOLES acronym, scoring system and management guidelines to avoid unnecessary referral of patients with choroidal nevi to hospital eye clinics while expediting diagnosis and treatment of patients with choroidal melanoma. (PMID 35764877)

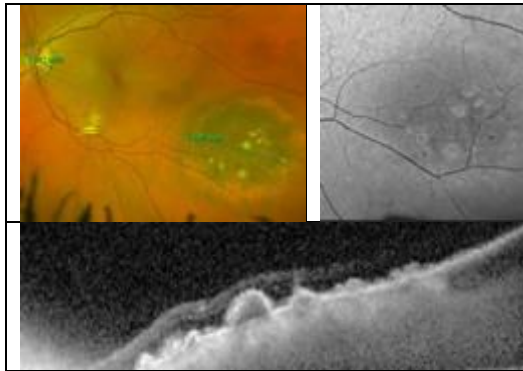
MOLES SCORING SYSTEM

Clinical Feature	Score
<ul style="list-style-type: none"> ■ Mushroom shape Nil = 0 Incipient, with erosion of RPE = 1 Present, with overhang = 2 	
<ul style="list-style-type: none"> ■ Orange pigment Absent = 0 Minimal dusting = 1 Confluent clumps = 2 	
<ul style="list-style-type: none"> ■ Large size Diameter <3DD and thickness <1.0mm = 0 Diameter 3-4DD and/or thickness 1-2mm = 1 Diameter >4mm and/or thickness >2mm = 2 	
<ul style="list-style-type: none"> ■ Enlargement* Nil or new tumor but no previous exam = 0 Uncertain / 'new tumor but no old image' = 1 Definite, with sequential imaging = 2 	
<ul style="list-style-type: none"> ■ Subretinal fluid Nil = 0 Minimal, visible only with OCT = 1 Significant, visible ophthalmoscopically = 2 	
* Assume growth and score enlargement >0 if diameter >5 DD or thickness >3 mm.	
Total Score	

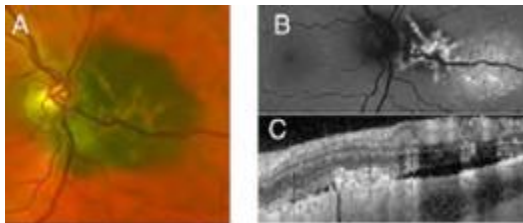
Score	Diagnosis	Management
0	Common nevus	Self care*
1	Low-risk nevus	Non-urgent referral to ophthalmologist
2	High-risk nevus	Non-urgent referral to ophthalmologist
3	>Probable melanoma	Urgent referral to ophthalmologist



Common choroidal nevus (MOLES score = 00000 = 0). The color photograph shows the small tumor size. The autofluorescence image excludes lipofuscin. The OCT shows the tumor to be flat with no subretinal fluid. Contrary to previous reports, juxtapapillary location is not a sign of malignancy.

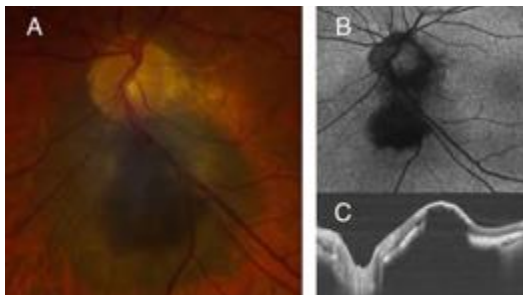


Low-risk choroidal nevus (MOLES = 00100 = 1) with a diameter of 3-4DD, a thickness < 1 mm, no orange pigment and no subretinal fluid. Drusen on the tumor surface indicate chronicity. The tumor has a partial halo, which is reported to be associated with a relatively low risk of malignancy.

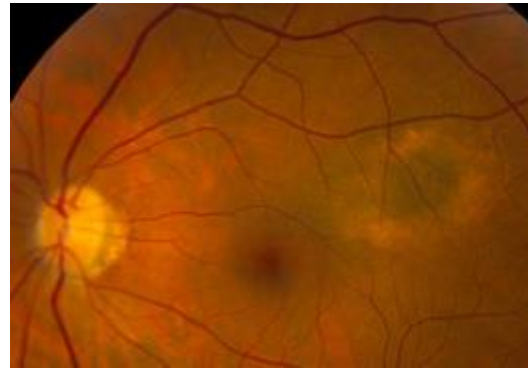


Choroidal melanoma with clumps of confluent orange pigment, which on FAF is hyper-autofluorescent and which on OCT is seen on the retinal surface of the RPE (unlike drusen, which are located between RPE and Bruch's membrane). There is also subretinal fluid.

Mushroom shape is almost pathognomonic for choroidal melanoma. It occurs when the tumor extends through Bruch's membrane and retinal pigment epithelium (RPE). When this happens, the tumor thickness increases so that the MOLES score exceeds 2. A score of 1 indicates that the tumor bulges slightly through a defect in Bruch's membrane.

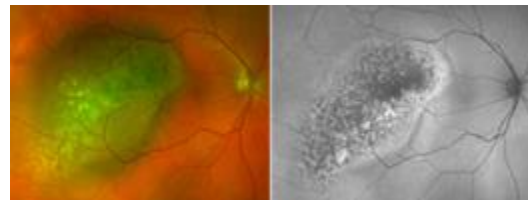


High-risk choroidal nevus with tumor spread into the retina as shown by the OCT and the hypo autofluorescence on FAF (MOLES score = 10100 = 2). No growth was observed over 13 years.



Choroidal nevus (MOLES = 00000). The lesion is unusual because it has a halo, which is said to be a reassuring feature.

Orange pigment, consisting of lipofuscin, accumulates on the retinal surface of the RPE overlying choroidal melanomas, particularly posterior to the equator. Light dusting of orange pigment can occur over choroidal nevi and is given a MOLES score of 1; however, clumps of confluent orange pigment tend to occur with melanomas, hence the score of 2. Over amelanotic tumors, lipofuscin can appear brown. This pigment is hyper-autofluorescent. On OCT, lipofuscin forms fluffy deposits on the retinal surface of the RPE, unlike drusen, which form discrete lumps between RPE and Bruch's membrane. Note that orange pigment can appear over other tumors, such as metastases and hemangiomas.



Amelanotic choroidal melanoma imaged with the Optos camera, showing golden-colored lipofuscin, which is hyperfluorescent.

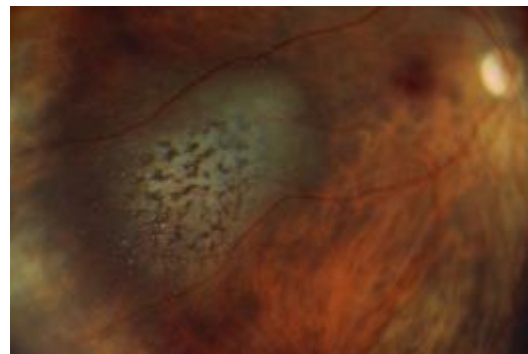


Fig. Amelanotic choroidal melanoma photographed with the Panoret camera, showing lipofuscin as dark-brown clumps

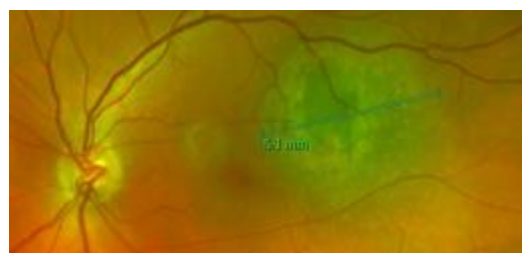
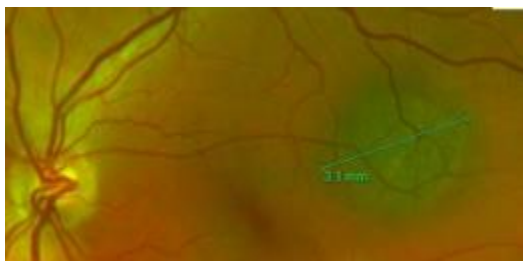
Larger size. Choroidal melanomas tend to be wider and thicker than nevi, although there is

some overlap. Augsburger et al found that there are approximately 125 choroidal nevi for every melanoma in the thickness range of 1.5 to 2 mm, 25 nevi for every melanoma in the thickness range of 2 to 2.5 mm, and 5 nevi for every melanoma in the thickness range of 2.5 to 3 mm.

Erring on the side of caution, the tumor thickness is given MOLES scores of 0, 1 and 2 if the tumor thickness is <1 mm, 1-2 mm or >2 mm respectively (i.e., 'flat/minimally thickened', 'slightly dome shaped – seen with difficulty on ophthalmoscopy', and 'significantly elevated - easily visible on ophthalmoscopy'). If possible, the thickness of small, posterior lesions should be documented by performing optical coherence tomography (OCT). Ultrasonography may be useful when OCT is not possible because of large tumor size or peripheral location.

Augsburger et al found that there are approximately 70 nevi for every choroidal melanoma in the basal diameter range of 5 to 6 mm, 10 nevi for every melanoma in the diameter range of 6 to 7 mm, and 3 nevi for every melanoma in the range 7 to 8 mm. The MOLES system therefore scores basal diameter as 0, 1 or 2 if measurements are <3 DD, 3-4 DD, and >4 DD respectively (1DD=1.5 mm. Tumors rarely become thicker without also showing an increase in diameter; color photography should therefore be sufficient when OCT and ultrasonography are not possible.

Enlargement of choroidal nevi is rare after the age of 25 years, and when it occurs it is minimal and slow (i.e., <0.5 mm/yr.). Sequential fundus photography makes it easier to detect tumor growth, especially if distances between tumor margins and nearby retinal landmarks are assessed.



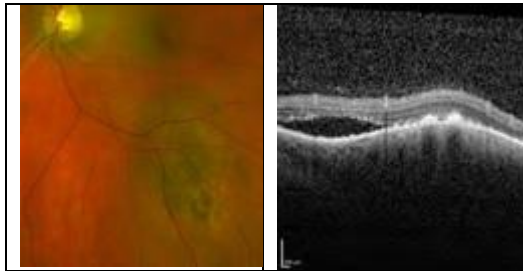
Growth of a choroidal melanoma, best seen using retinal blood vessels as a guide (more sensitive than assessing basal diameter)

Tumor enlargement confirmed photographically is given a MOLES score of 2. If photography suggests growth but is inconclusive, because of poor image quality, a score of 1 is given. A score of 0 is given if a lesion is detected and if the patient was not seen previously. A score of 1 is given if no lesion was documented or mentioned to the patient after previous ophthalmoscopy and if its absence previously not confirmed photographically. In our opinion, when monitoring suspicious lesions, ultrasonography is not required if sequential color photography does not suggest growth. This is because it is rare for tumors to grow thicker without becoming wider and/or showing other signs of progression, such as RPE perforation or increasing amounts of orange pigment and/or subretinal fluid.

Large tumors (i.e., >5DD wide or >3 mm thick) are assumed to have grown and are given an Enlargement score of 1. This is because lipofuscin and subretinal fluid may not be visible in color images of large, anterior melanomas.

Subretinal fluid (SRF) develops when RPE function is disturbed by an underlying choroidal tumor. The retina is flat over typical nevi (i.e., MOLES score = 0) but some larger lesions may show minimal or localized detachment, which is given a score of 1. Significant and extensive retinal detachment that extends beyond the tumor margins or that is visible ophthalmoscopically is given a MOLES score of 2.

Subretinal fluid is best detected with OCT. Cystoid spaces within the retina itself indicate chronicity and are given a score of 0. RPE and retinal changes caused by fluid gravitating from the tumor are also given a score of 0 if there is no longer any retinal detachment.



Retinal detachment, best demonstrated with OCT

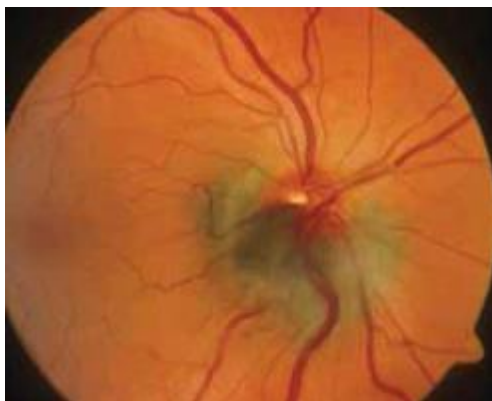
Some choroidal nevi are atypical because of large size, de-pigmented halo, drusen, a choroidal neovascular membrane, or amelanotic appearance.

The mnemonic TFSOM (To find small ocular melanoma) previously stood for: Thickness, Fluid, Symptoms, Orange pigment, and Margin near disc. Proximity to disc is no longer considered to indicate malignancy. 'M' now represents 'melanoma hollow on ultrasonography). The letters '-DIM' (doing imaging) have been added to represent 'Diameter more than 5mm'.

Unlike TFSOM, MOLES does not require ultrasonography. This is because many clinics lack the skill and equipment needed to assess internal acoustic reflectivity of thin tumors.

MELANOCYTOMA

Melanocytomas are usually seen at the optic disc but can arise anywhere in the uveal tract. (PMID16500211)



Melanocytoma, with no change after several years

This tumor can show malignant growth, either because of malignant transformation (reportedly in 1-2% of cases) or if a melanoma has mistakenly been diagnosed as melanocytoma. Melanocytomas can grow slowly, may extend extraocularly and can also

undergo necrosis to cause pigment dispersion, as well as: (a) optic nerve compression and acute visual loss if the tumor is located at the optic disc; and (b) uveitis and (c) glaucoma if it is situated in ciliary body. Patients with melanocytoma tumor are managed in the same way as those with a suspicious nevus.

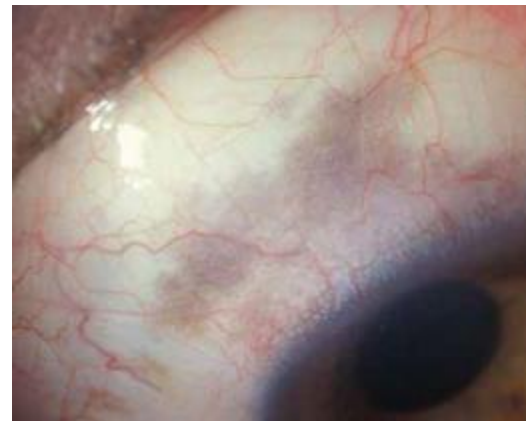
CONGENITAL OCULAR MELANOCYTOSIS

Congenital ocular melanocytosis (COM) (also known as congenital ocular melanosis and oculo-dermal melanocytosis (i.e., nevus of Ota)) are associated with a 1 in 400 risk of uveal melanoma, which tends to be relatively aggressive. (9442799) There is an association between melanocytosis and bilateral Sturge-Weber syndrome.

Diagnosis

Diagnosis is based on any of the following:

- Iris heterochromia, sometimes with multiple 'nipple-like' lesions known as mammillations.
- Slate-grey episcleral pigmentation.
- Skin pigmentation around eye.
- Choroidal pigmentation.



Congenital ocular melanocytosis (nevus of Ota). Note the slate grey scleral pigmentation. The overlying conjunctiva is clear and transparent. The melanocytosis also involves a sector of the iris

COM is sub-conjunctival and should be distinguished from conjunctival melanosis by dragging the conjunctiva from side to side with a cotton bud after administering an anesthetic drop and noting whether the pigmented tissue moves.

Management

COM is managed in the same way as high-risk nevus (i.e., MOLES score = 2), with annual

ocular examination with mydriasis. Ciliary body melanoma is detected by noting dilated episcleral vessels if UBM is not possible. Multiple ocular melanomas (and orbital melanoma) can occur in this condition. COM can cause glaucoma, which needs to be excluded at every visit.

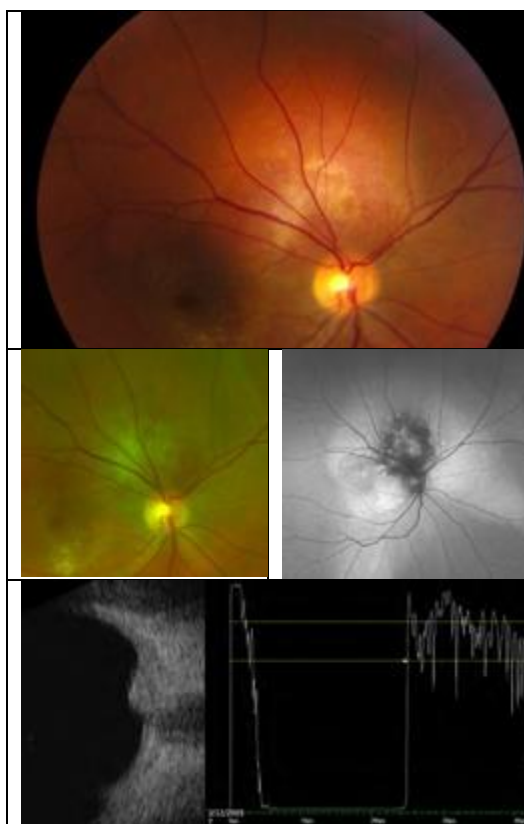
CHOROIDAL HEMANGIOMA

Choroidal hemangiomas usually develop posteriorly, near the optic disc or fovea. (PMID 3175430,) They can be nodular ('circumscribed') or diffuse.

A choroidal hemangioma can remain asymptomatic or can cause exudative retinal detachment, with visual loss and, eventually, painful neovascular glaucoma.

Diagnosis

US shows high acoustic reflectivity. Fluorescein angiography is not helpful. Although indocyanine green angiography can show 'late washout', this investigation is rarely necessary.



Circumscribed choroidal hemangioma imaged with standard color photography, Optos, autofluorescence imaging, B-scan ultrasonography and A-scan ultrasonography. The tumor has the same color as the surrounding choroid and shows a high internal acoustic reflectivity.

Management

FOCAL

If a circumscribed hemangioma is asymptomatic, treatment is not necessary so that the patient can be discharged, with advice on what to do if symptoms develop.

Symptomatic tumors should be treated semi-urgently because the chances of therapy improving vision diminish if visual loss is severe and/or prolonged. Vision may remain poor if the eye is amblyopic.

The first choice of therapy is photodynamic therapy. It may be necessary to repeat the photodynamic therapy if retinal detachment persists after more than two months. If this is not possible, then monthly intravitreal anti-angiogenic injections may improve vision. Radiotherapy can also be effective but is avoided if possible. When irradiation is necessary, proton beam radiotherapy reduces exposure of healthy tissues to radiation.

DIFFUSE

Diffuse choroidal hemangiomas are usually extensive and often associated with a bullous retinal detachment. They can be associated with:

- Sturge-Weber syndrome, which includes facial nevus flammeus, glaucoma and leptomeningeal angiomas with calcification causing epilepsy and visual field defects. (PMID 31313748, 33843430)
- Phakomatosis pigmentovascularis, which includes nevus flammeus, nevus of Ota and, therefore, uveal melanoma, in rare cases.
- Klippel-Trenaunay syndrome, which includes nevus flammeus, soft tissue and bone hypertrophy, and many other features.

Photodynamic therapy may fail if the choroidal hemangioma is extensive. Alternative methods of treatment include plaque radiotherapy, external beam radiotherapy and proton beam radiotherapy.

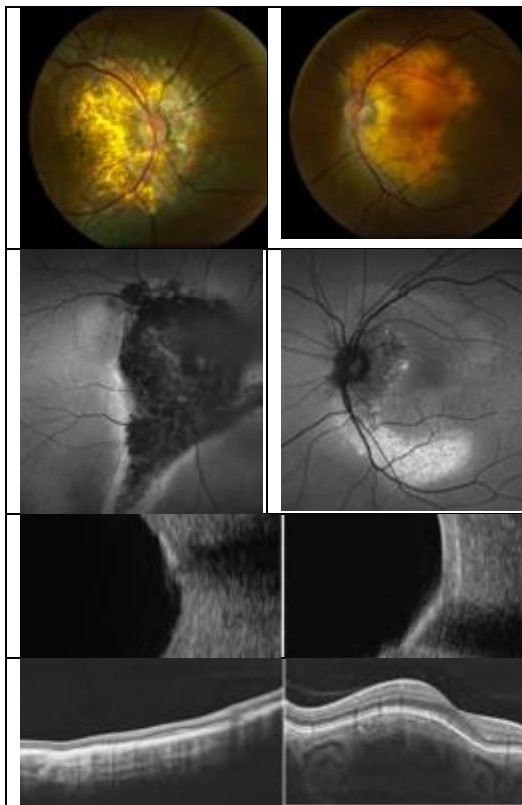
CHOROIDAL OSTEOMA

Choroidal osteoma can affect the fovea both directly and by inducing choroidal neovascularization. (PMID 25100910)

Spontaneous decalcification of choroidal osteoma causes RPE atrophy and visual loss if the fovea is involved.

Diagnosis

Ultrasonography shows the very high acoustic reflectivity of the tumor surface, with orbital shadowing. Areas of RPE atrophy are non-autofluorescent on FAF. OCT shows transverse layering within the tumor.



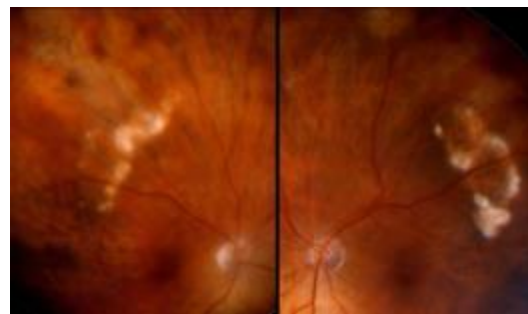
Bilateral choroidal osteomas, progressing in the left eye and regressed in the right eye. Color photography shows these lesions to be pink in the left eye and yellow in the right eye. FAF shows normal autofluorescence where RPE is present in the left eye and hypo autofluorescence where RPE is atrophic in the right eye. Ultrasonography shows highly reflective lesions, with orbital shadowing. OCT shows the layering within the tumor in the left eye and flattening of the tumor in the right eye.

Management

Photodynamic therapy for tumors growing towards the fovea may induce regression before central vision is lost. Any choroidal neovascularization causing visual loss is treated in the usual way.

SCLERO-CHOROIDAL CALCIFICATION

This is a degenerative condition causing linear intra-scleral calcification, usually in the region of the oblique muscle insertions. (PMID12055456) Ultrasonography shows high reflectivity with orbital shadowing. No treatment is needed unless a choroidal neovascular membrane develops. This condition is usually idiopathic but may be associated with disordered calcium metabolism in patients with conditions such as Bartter's syndrome, Gitelman syndrome, etc.

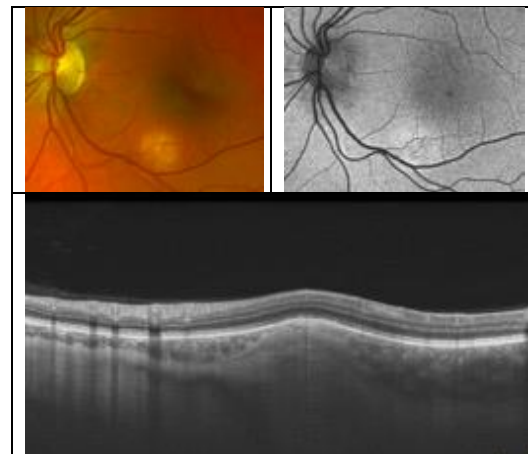


Bilateral sclero-choroidal calcification

OCULAR SCLEROMA

This scleral nodule, which Damato et al have termed 'ocular scleroma', compresses the overlying choroid, causing RPE atrophy. US shows no orbital shadowing.

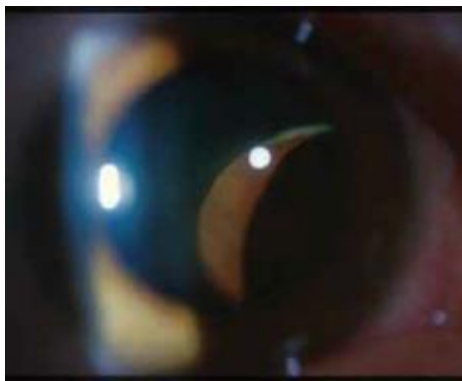Scleroma, otherwise 'solitary idiopathic choroiditis' or 'focal scleral nodule', is neither choroidal nor inflammatory and are inactive and harmless.



Scleroma, located in sclera and showing overlying choroidal compression and RPE atrophy

NEUROFIBROMA, NEURILEMMOMA AND LEIOMYOMA

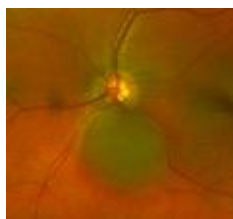These tumors usually develop in the ciliary body but can occur anywhere in the choroid. Although clinical features allow a tentative diagnosis, histology is required for confirmation. Most are diagnosed after local resection, biopsy or enucleation. Treatment is by trans-scleral local resection, which is a specialized procedure.



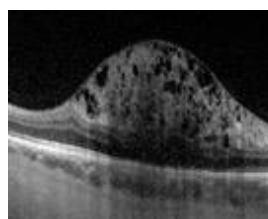
Ciliary body neurilemmoma mimicking melanoma. The tumor is amelanotic but appears pigmented because of the overlying pigment epithelium.

ASTROCYTIC HAMARTOMA

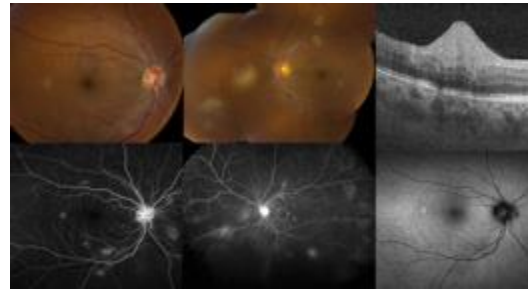
This benign retinal hamartoma usually occurs in children in association with tuberous sclerosis. (PMID 27447981). A solitary lesion can arise at any age in otherwise healthy individuals. Systemic disease is excluded by: (a) dermatological examination; (b) MRI brain scan for intra-cranial lesions; (c) family studies; and (d) molecular genetic studies. These are organized in collaboration with a geneticist. Most astrocytic hamartomas are static and asymptomatic. Any vitreous hemorrhage, neovascular glaucoma and optic nerve damage may be treated empirically, albeit with a guarded prognosis.



**Color photograph
Astrocytic hamartoma**



OCT appearance

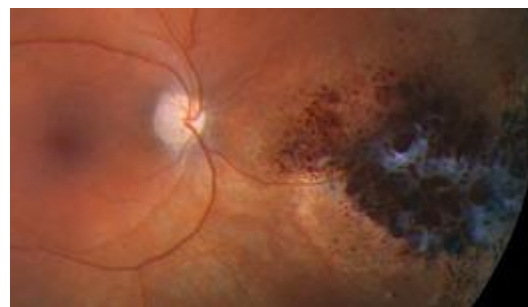


Multiple retinal angiomas in a patient with tuberous sclerosis

RETINAL CAVERNOUS ANGIOMA

Retinal cavernous angioma consists of a cluster of blood-filled saccules, with fluid levels. Visual loss may be caused by vitreous hemorrhage, macular location or epiretinal membrane formation. (PMID27820777)

This condition may be sporadic or inherited in an autosomal dominant fashion, in which case it may be associated with intracranial cavernous angiomas and cutaneous lesions.



Cavernous retinal angioma, resembling a bunch of grapes

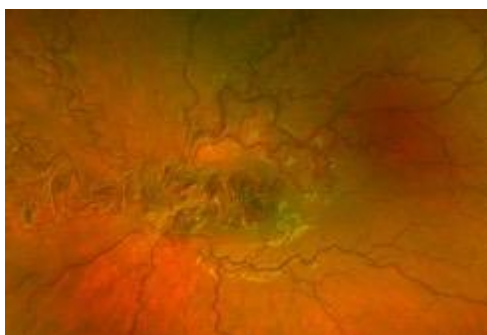
The patient and any close relatives require neurological examination with MRI scans. Photocoagulation of retinal lesions is avoided because it can result in hemorrhage and tumor enlargement.

CONGENITAL RETINAL ARTERIOVENOUS MALFORMATION

This condition has several names, including racemose retinal angioma and Wyburn-Mason syndrome. (PMID29630270) There may be only abnormal capillaries between the major retinal blood vessels, arteriovenous communications without intervening capillaries and extensive arteriovenous malformations, which may progress over time and thrombose. Other ocular features include retinal vascular

occlusion (possibly causing NVG), macular edema, vitreous hemorrhage, optic nerve compression, optic atrophy, proptosis, ptosis, strabismus. About 30% of patients have intracranial racemose hemangiomas, which can cause seizures, headache, hemiparesis, visual deficits, and hydrocephalus. Similar lesions in the mandible can cause severe hemorrhage after dental extraction.

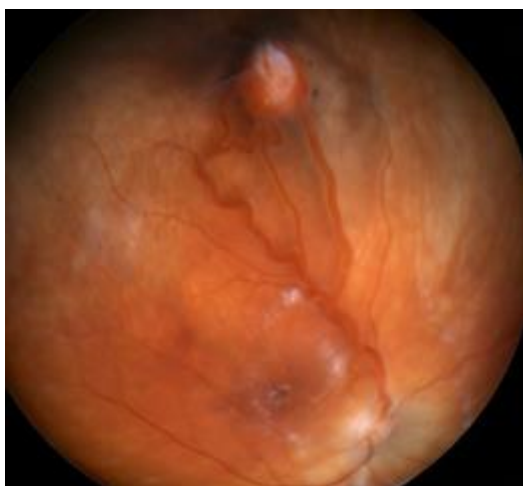No ocular treatment is required unless there are complications, which are treated as appropriate. Patients require brain MRI and are advised about the risk of hemorrhage after dental extraction.



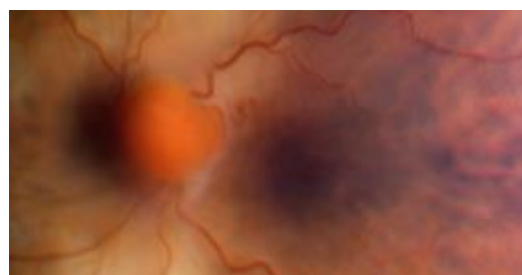
Racemose angioma (Wyburn-Mason Syndrome)

RETINAL HEMANGIOBLASTOMA

Retinal hemangioblastoma (retinal capillary angioma) can develop in isolation or in association with von Hippel Lindau syndrome. (PMID31095066) Patients with this ocular tumor are therefore referred to a clinical geneticist and other specialists for systemic investigation and treatment.



Retinal hemangioblastoma, with feeder vessels



Capillary hemangioblastoma of the optic disc

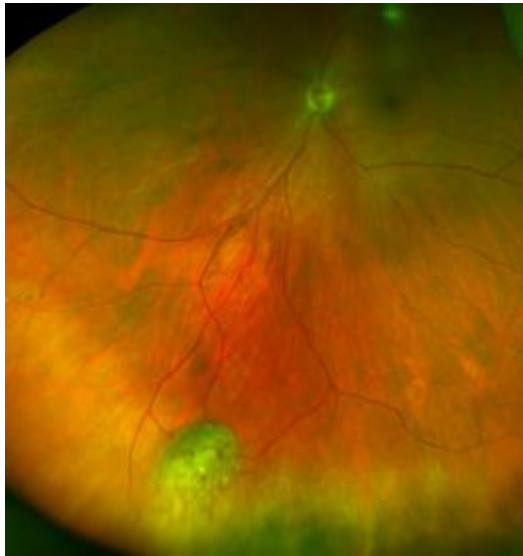Patients with VHL syndrome require ophthalmoscopy every 6-12 months.

Retinal lesions can be treated with: (a) photocoagulation or cryotherapy if small, depending on whether they are posterior or anterior, respectively; or (b) photodynamic therapy; (c) cryotherapy or ruthenium plaque radiotherapy if more than 1-2 DD in size; and (d) vitreoretinal surgery if vitreous bands and tractional retinal detachment are present. (PMID31259811)

Suggested treatments for juxtapapillary lesions include anti-angiogenic therapy (e.g., Avastin, photodynamic therapy, and proton beam radiotherapy. Unfortunately, the prognosis is poor. Belzutifan, a hypoxia-inducible factor inhibitor, may be helpful in these patients.

VASOPROLIFERATIVE TUMOR

This is a pink/yellow tumor usually located inferiorly, temporally and anteriorly. This condition may arise in isolation or in association with other ocular conditions, such as uveitis, previous retinal detachment, ocular trauma and retinitis pigmentosa. Visual loss can be caused by macular exudates and epiretinal membranes. Advanced tumors can cause total retinal detachment and neovascular glaucoma.



Vasoproliferative tumor

Treatment is by (a) cryotherapy, (b) photodynamic therapy, or (c) ruthenium plaque radiotherapy. There may be scope for surgical removal of exudates and epiretinal membranes if these threaten vision.

RETINOBLASTOMA

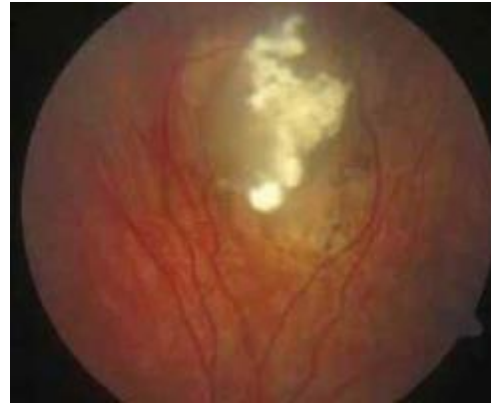Retinoblastoma is a malignant tumor arising from retinal cells (PMID27189421) This disease only rarely affects adults. It can do so in the following ways: (a) development of a secondary malignant neoplasm of the orbital region or ocular adnexa after previous radiotherapy; (b) an inactive tumor, consisting either of a benign variant of retinoblastoma or a spontaneously regressed tumor, with both of these varieties threatening tumor recurrence; (c) development of adult retinoblastoma, which is usually peripheral and often associated with clinical features resembling uveitis; and (d) development of retinal vasculopathy or cataract after previous radiotherapy for retinoblastoma.

Retinoblastoma is staged according to the International Retinoblastoma Classification (PMID15763190, 31421017, 23399379) and the TNM staging system. Treatment is with intra-arterial or intravenous chemotherapy if the tumor is too large for laser therapy or cryotherapy, with intravitreal chemotherapy for vitreous seeds. (PMID 33530736, 33536230, 34000459, 35609621, 33447588)

Brachytherapy is reserved for resistant disease if the tumor does not extend close to optic disc. (PMID363178171, 34928770) Enucleation for advanced disease, especially if unilateral (e.g.,

Group E and unilateral Group D disease). (PMID 31421017, 34298608)

After enucleation, the eye is examined histologically to identify any spread beyond the retina into choroid, optic nerve and orbit, to estimate the risk orbital recurrence, CNS disease, and metastasis. (PMID 28302322, 23399379, 19653709) Tumor is harvested for genetic testing to identify the RB1 mutation as well as secondary mutations, which may have prognostic significance. (PMID 32139107) If the eye is conserved, these genetic aberrations may be identified in an aqueous humor (liquid) biopsy. (PMID 33805776)



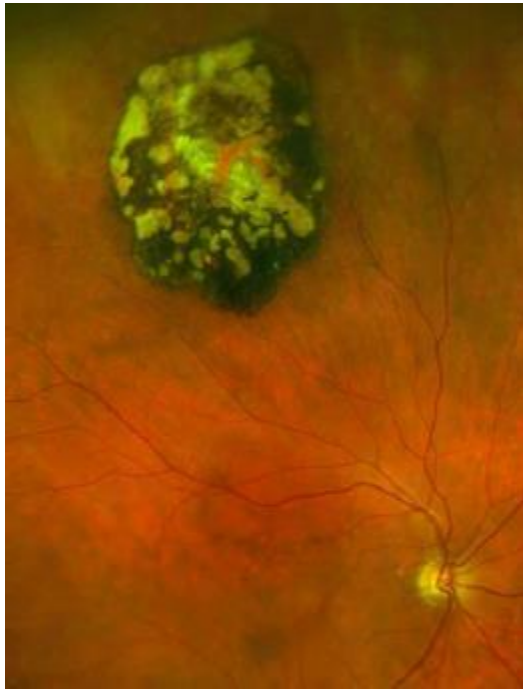Spontaneously regressed retinoblastoma in a teenager. This was later treated with a ruthenium plaque.

MEDULLOEPITHELIOMA

This is derived from retina and ciliary epithelium and usually presents in childhood. (PMID 31124483) Very rarely, it can become manifest in adulthood. It can be associated with the *DICER1* syndrome. The diagnosis is based on slit-lamp examination and UBM. Secondary effects, such as glaucoma, cataract and retinal detachment, need to be excluded. Small tumors may respond to plaque radiotherapy, but diffuse, large or recurrent tumors are treated by enucleation, with exenteration if there is orbital extension, because of the risk of intracranial spread, which can be fatal.

CONGENITAL HYPERTROPHY OF THE RPE (CHRPE)

These lesions are flat and deeply pigmented, commonly with areas of RPE atrophy ('lacunae'), discrete margins, and, in some cases, a narrow de-pigmented 'halo'. (PMID35015449)



Congenital hypertrophy of the retinal pigment epithelium, with discrete margins and lacune

Solitary and clustered lesions (i.e., ‘grouped pigmentation’, ‘bear tracks’, ‘cat’s paws’) do not have any systemic associations. (PMID8460012) The presence of more than three spindle-shaped lesions affecting one or both eyes is associated with familial adenomatous polyposis (FAP, which predisposes to colon carcinoma. Most patients with FAP have CHRPE lesions. (PMID35321042)

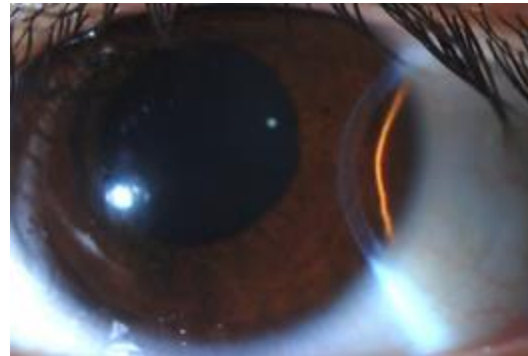
Nodular tumors arising from CHRPE have rarely been described and these are believed to be adenomas or low-grade adenocarcinomas. (PMID11296028) Review every two years is therefore indicated.

IRIS CYSTS

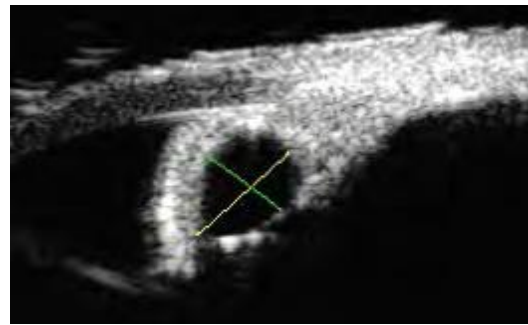
Diagnosis

Slit-lamp examination is performed with 3-mirror examination after mydriasis to determine whether the cyst arises in (a) pupil margin (‘central’), (b) iris pigment epithelium (‘midzonal’), (c) iridociliary angle (‘peripheral’), (d) iris stroma, or (e) conjunctiva (i.e., implantation cyst). It is important to exclude associated conditions such as: (a) life-threatening, dissecting aortic aneurysm in the case of autosomal dominant iris flocculi (occurring at the pupil margin)(PMID 29055370, 29875232); (b) associated tumors such as

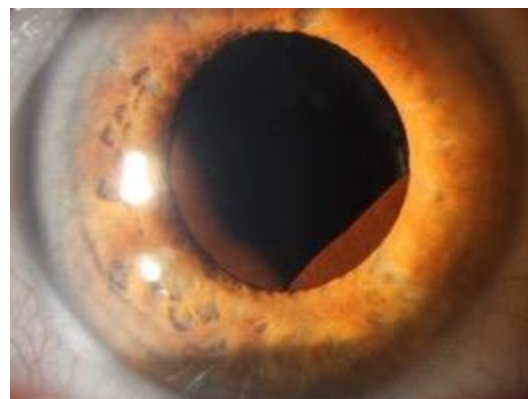nevus, melanoma and medulloepithelioma; and (c) secondary glaucoma and cataract.



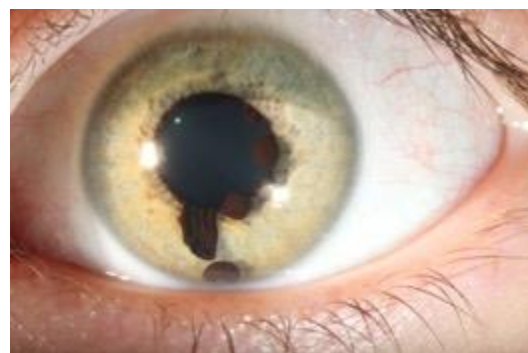Peripheral iris cyst, located temporally in the left eye, pushing the iris forward and narrowing the angle



Peripheral iris cyst, confirmed with B-scan ultrasonography, which shows a hollow tumor. Multiple tiny cysts are usually also present, bilaterally



Midzonal iris cysts. Note the smooth surface.



Iris flocculi, which may be associated with autosomal-dominant *ACTA2* mutation and fatal dissecting aneurysm

Treatment

Asymptomatic cysts can be observed.

Symptomatic epithelial cysts can be ruptured with argon or Nd-YAG laser treatment.

Stromal iris cysts threatening vision can be destroyed by collapsing the cyst by needle aspiration and performing cryotherapy or injecting alcohol, which is removed after a few minutes. This treatment may need to be repeated. Local resection is another option.

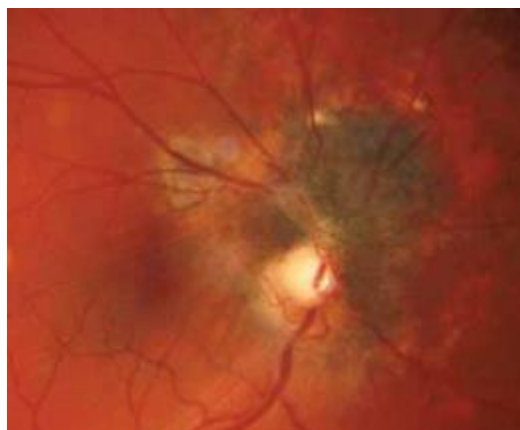Patients with iris flocculi need to be referred to a vascular surgeon.

ADENOMA AND ADENOCARCINOMA

These tumors arise from retinal pigment epithelium, ciliary epithelium, CHRPE, or from chorioretinal scars. They can be pigmented or amelanotic and difficult to differentiate clinically from melanoma. These tumors tend to be diagnosed histologically, after resection. Although observation has been recommended, most ciliary body tumors are treated by iridocyclectomy, which is useful both for diagnosis and treatment.

COMBINED HAMARTOMA OF THE RPE AND RETINA

This rare condition can affect the juxtapapillary retina or can be peripheral. The diagnosis is based on ophthalmoscopy. Occasionally, epiretinal membrane surgery can improve vision. Occlusive therapy of the fellow eye has been recommended for children with visual loss. An association with neurofibromatosis has been reported.



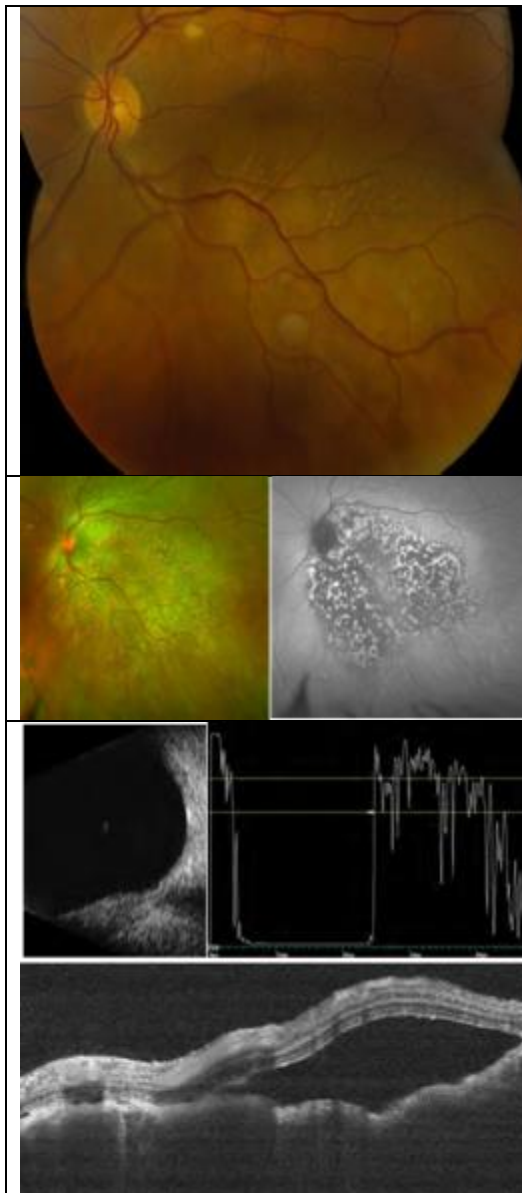
Combined hamartoma of the RPE and retina

INTRAOCULAR METASTASIS

Intraocular metastases are common but often overshadowed by the systemic disease. (PMID28399345, 35306540) Most uveal metastases arise in breast and lung. Metastases can be multiple and bilateral. They tend to grow relatively fast and cause extensive exudative retinal detachment.

Diagnosis

Metastases are usually posterior, amelanotic, and plateau-shaped, with indistinct margins, and exudative retinal detachment. Tumor vasculature is not usually visible. There can be clumps of lipofuscin, which can appear brown. These tumors show medium reflectivity on ultrasonography, as well as hyper- and hypo-autofluorescent stippling on autofluorescence imaging. OCT shows a lumpy anterior surface, which is typical of this condition. Biopsy is useful for establishing the diagnosis and indicating the likely site of the primary cancer if this is not known. Some perform biopsy only as a last resort, when systemic investigations are inconclusive. Such testing can delay treatment, allowing the tumor to grow significantly and to cause irreversible visual loss. Also, systemic investigations may fail to detect the primary tumor. For these reasons, some therefore advocate biopsy in the first instance.



Choroidal metastasis with standard color photography and Optos. FAF shows extensive clumps of orange pigment. US shows moderate internal acoustic reflectivity. OCT shows a typical lumpy surface with retinal detachment.

Treatment

Patients with ocular metastases require multidisciplinary care, with involvement of medical oncologists, radiotherapists, and other specialists.

If the patient is starting systemic therapy, ocular assessment is repeated about 4 weeks after completing the first course of therapy in the hope that the tumor regresses. Most patients receive external beam radiotherapy, which is delivered either over several weeks if the life-expectancy is good or over a few days if the prognosis for survival is poor. If the patient lives far from the ocular oncology center, this

external beam radiotherapy may be delivered at a hospital near the patient's home. Before starting ocular radiotherapy, it is important to exclude intracranial metastases, which would be treated at the same time. If the tumor is small, the ocular oncologist may attempt photodynamic therapy in the hope of sparing the patient from the inconvenience of external beam radiotherapy. As a rule, all follow-up is at the local hospital, especially if the patient is unwell.

VITREORETINAL LYMPHOMA

Vitreoretinal lymphoma is strongly associated with CNS lymphoma, which has a high mortality. (PMID33481398, 34009095). This is mostly because of CNS involvement. (PMID35740632) Patients are elderly, unless immunodeficient.

The lymphoma is believed to originate systemically, homing to brain, retina, and testis. Some believe that the tumor cells reach the retina via the retinal arterioles, then spread into the vitreous and infiltrate into the sub-RPE space, where they are trapped by Bruch's membrane so that they accumulate to form small deposits or large tumor masses.

Clinical features

These can include the following:

- Vitreous infiltrates, which can obscure the fundus.
- Anterior chamber cells, in some patients.
- Subretinal yellow-white tumor deposits, which can cause RPE atrophy when they regress.
- Retinal arteriolar sheathing and occlusion.
- Cystoid macular edema (albeit rarely).
- Epiretinal membranes.
- Optic nerve infiltration with swelling and atrophy.

Investigations

- Ophthalmoscopy and wide-angle color photography, to document subretinal deposits, vascular sheathing, and occlusion.
- Fundus autofluorescence imaging to show hyper-autofluorescent sub-RPE deposits and hypo-autofluorescent areas of RPE atrophy.
- OCT, which demonstrates sub-RPE deposits, cystoid edema and epiretinal membranes.
- Vitreous biopsy for: cytology to identify lymphoma cells; immunohistochemistry, flow cytometry and gene rearrangement

studies to show monoclonality and mutations, such as *MYD88*, as well as excluding infectious agents.

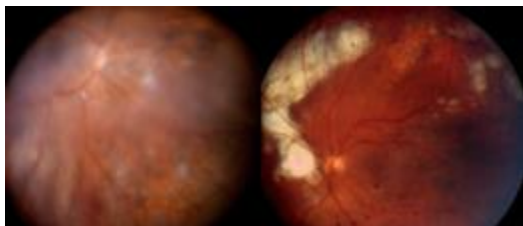
- Systemic and CNS investigations, in collaboration with a hemato-oncologist.

Treatment

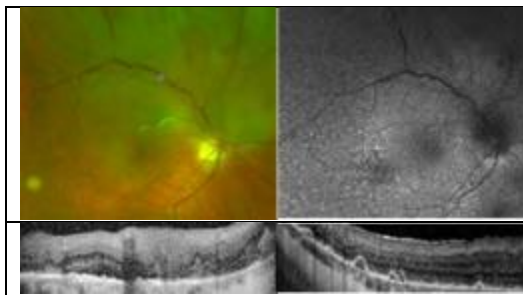
There is no consensus on 'best treatment'. Most rely on intravitreal methotrexate injections.

An alternative approach, hopefully prolonging life, is:

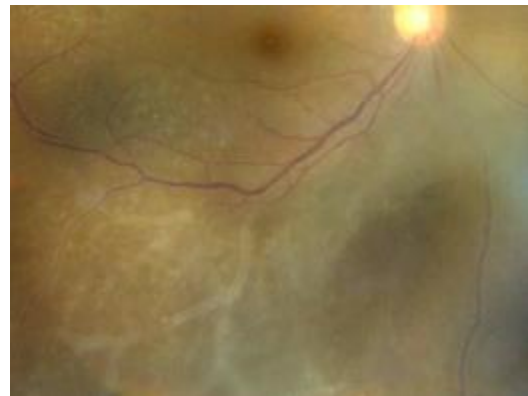
- High-dose systemic chemotherapy followed by immunotherapy with lenalidomide or similar agents, administered by a hemato-oncologist.
- Therapeutic vitrectomy for dense vitreous infiltrates, which are resistant to systemic therapy
- Ocular radiotherapy for resistant disease.
- Intra-vitreous melphalan, rituximab or methotrexate if other methods fail.



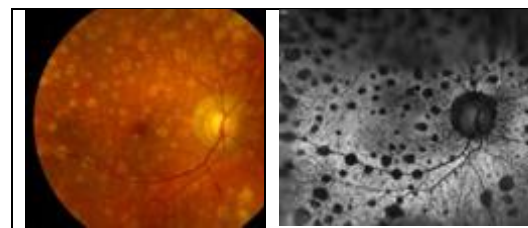
Bilateral vitreoretinal lymphoma, with infiltrates predominantly vitreal in the right eye and mostly sub-RPE in the left eye.



Vitreoretinal lymphoma. The color image shows a diffuse retinal infiltrate and an intravitreal clump of lymphoma cells. FAF shows multiple hyper-autofluorescent sub-RPE deposits. OCT shows the intra-retinal infiltrate superior to the disc (left) and the sub-RPE deposits at the macula (right).



Vitreoretinal lymphoma with sheathing of retinal arterioles by lymphoma cells



Atrophic RPE spots, which are hypofluorescent on FAF, corresponding to sites of previous sub-RPE lymphoma deposits

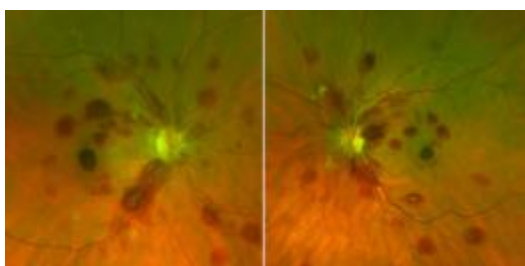
OTHER HEMATOLOGICAL MALIGNANCIES

These include:

Secondary intraocular lymphoma, leukemias, cutaneous T-cell lymphoma, multiple myeloma, etc.

Clinical features include:

- tumor deposits in retina, vitreous, optic disc and choroid.
- Circulatory disturbances, causing retinal hemorrhages, cotton wool spots, venous tortuosity and microaneurysms.
- Exudation, such as optic disc edema, exudative retinal detachment, and, in multiple myeloma, pars plana cysts.
- Infections, such as cytomegalovirus, toxoplasmosis, aspergillosis and cryptococcus.
- Extraocular abnormalities, such as proptosis, herpes zoster ophthalmicus, perilimbal infiltrates and graft-vs-host disease after allogeneic bone marrow transplantation.



Bilateral retinal hemorrhages and cotton-wool spots in a patient with leukemia

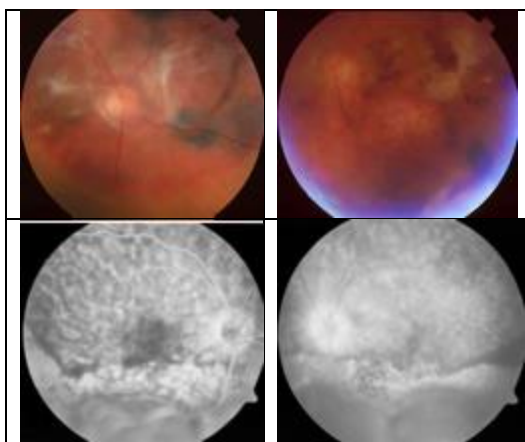
PARANEOPLASTIC SYNDROMES

These include:

- Melanoma-associated retinopathy (MAR).
- Cancer-associated retinopathy (CAR).
- Bilateral diffuse uveal melanocytic proliferation (BDUMP).
- Miscellaneous other abnormalities (e.g., optic neuropathy and vitelliform lesions).

Symptoms include visual loss, night blindness, photopsia.

Signs of BDUMP include: (a) RPE stippling, red/grey patches, and depigmented areas; (b) attenuation and perhaps sheathing of retinal vessels; (c) optic atrophy; (d) multiple pigmented and amelanotic tumors; (e) vitreous cells; (f) exudative retinal detachment; (g) cataract; and (h) glaucoma. Investigations include: (a) color photography; (b) fluorescein angiography; (c) ultrasonography, including high-frequency examination of ciliary body; and (d) electrophysiology. Patients are referred to an oncologist for further investigation. An occult primary neoplasm can sometimes be detected only after repeated examinations.



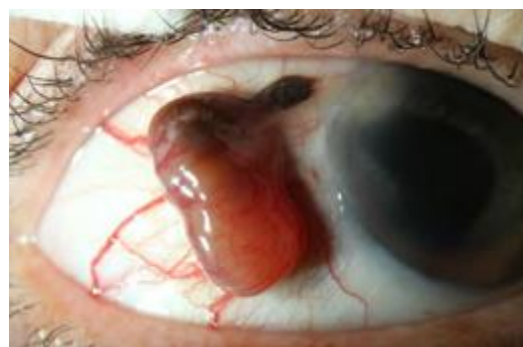Bilateral diffuse uveal melanocytic proliferation, with multiple pigmented choroidal lesions, diffuse uveal thickening, serous retinal detachment and rapidly progressive cataracts. The BDUMP

resolved after surgical removal of a small cancerous tumor in the right lung.

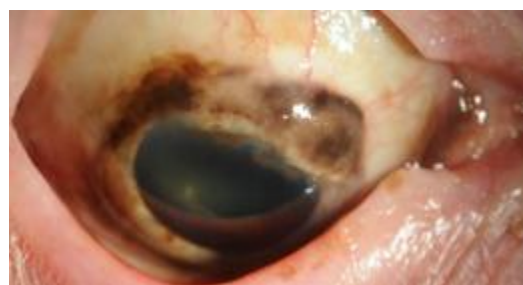Successful treatment of the primary tumor can result in regression of the ocular disease. Systemic steroids, plasmapheresis, and intravenous immunoglobulins can be tried but the results are unpredictable.

CONJUNCTIVAL MELANOMA

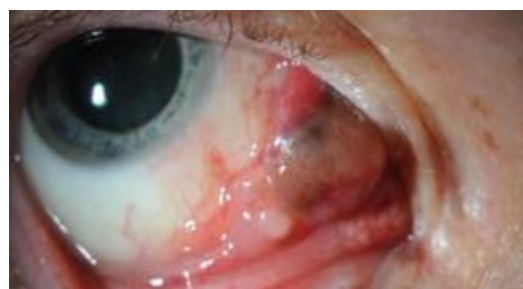Conjunctival melanomas are rare (PMID 34424954). They can arise in any part of the conjunctiva and can be nodular or diffuse, and pigmented or amelanotic, usually larger than nevi, with feeder vessels.



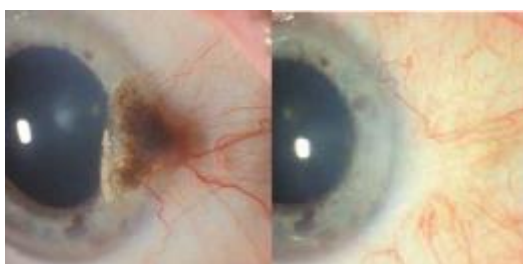
Nodular bulbar conjunctival melanoma in the right eye



Nodular melanoma arising from primary acquired melanosis



Right caruncular melanoma with melanotic and amelanotic areas. Despite successful ocular treatment the patient developed metastasis.



Conjunctival melanoma of the right medial limbus before and after treatment

Examination

The entire conjunctiva must be examined, and regional lymph nodes should be palpated. Biopsy must be excisional, using the no-touch technique, because incisional biopsy can cause tumor seeding, complicating subsequent management.

Management

Nodular melanomas are excised, using a no-touch technique. (PMID 31965542, 27218788, 19761427) The conventional practice is to excise the tumor with wide safety margins, apply adjunctive cryotherapy, then close the wound with an amniotic membrane graft, administering adjunctive radiotherapy and/or topical mitomycin C chemotherapy if histology indicates incomplete excision. (PMID 16970772) An alternative approach, favored by Damato, is to: excise the tumor with narrow safety margins using a no-touch technique; close the wound by primary intention (using fresh instruments); administer adjunctive radiotherapy if the tumor is invasive, irrespective of histological clearance; and prescribe topical chemotherapy if there is primary acquired melanosis or histological evidence of pagetoid tumor spread. (PMID 23174750) Proton beam or external beam radiotherapy may be useful for forniceal disease. (PMID 23174750) Exenteration may be needed for advanced disease. (PMID 36522530, 32572608) Neoadjuvant systemic therapy with immune checkpoint inhibitors may shrink the tumor enough to become resectable (PMID 30909967)

At each postoperative visit, the regional nodes are palpated, and the patient is asked about general health.

Any areas of confluent or increasing pigmentation are biopsied in case of recurrent disease. If enlarged regional nodes develop, the patient is referred to a head-and-neck surgeon for excision biopsy and radiotherapy. If there is

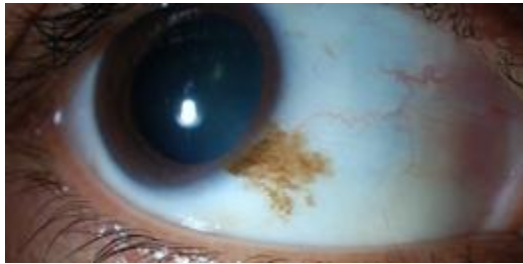
any suspicion of systemic disease, the patient is referred to an oncologist.

Risk factors for metastatic disease include large tumor size and non-bulbar conjunctival involvement. (PMID 33306519, 22965011, 31169891) The tumor is analyzed for *BRAF* mutations in case treatment with vemurafenib or other *BRAF* inhibitors is ever needed. Conjunctival melanomas can respond to immune checkpoint inhibitors, unlike uveal melanomas.

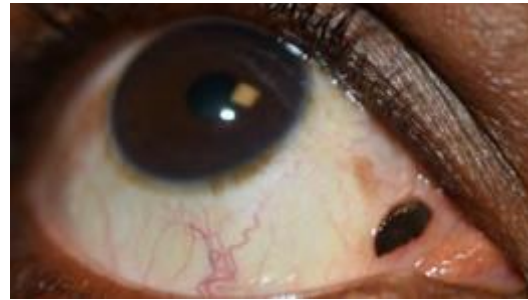If recent European guidelines for cutaneous melanoma are applied to conjunctival melanoma, patients with a 5-15% risk of metastatic death at 10 years would undergo lymph node ultrasonography, serum lactate dehydrogenase and serum S-100 analysis every 3-6 months. Patients with a higher risk of metastasis would in addition undergo computed tomography with intravenous contrast or positron emission tomography scans (PET CT) of the neck, thorax, abdomen and pelvis and magnetic resonance imaging with intravenous contrast of the brain. Those with less than a 5% risk of metastatic death at 10 years would undergo only clinical examination every 6-12 months, with palpation of cervical, preauricular and submandibular nodes.

PRIMARY ACQUIRED CONJUNCTIVAL MELANOSIS (PAM)

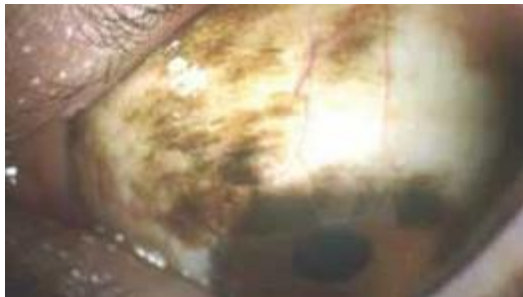
The term 'PAM' refers to conjunctival melanosis that is not congenital and not associated with systemic disease. (PMID 33342197, 34424954) Incisional biopsies are required to determine whether atypia is present. Samples are taken under local anesthesia and are about 3 mm in diameter to provide an adequate specimen without the need for suturing. The degree of malignancy is estimated according to melanocytic density and atypia as well as the density of the tumor cells and the extent of their spread towards the conjunctival surface. (PMID 33130046)



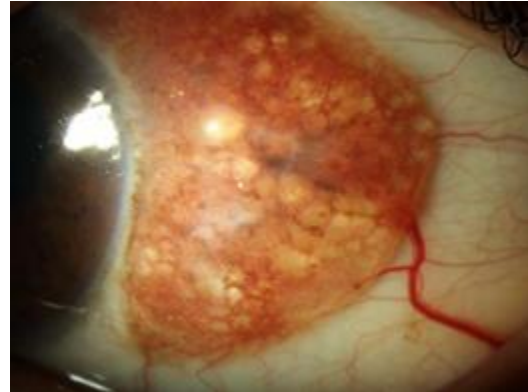
PAM, probably without atypia. Self-monitoring would be appropriate. The patient should be provided with a photograph



Nevus of the right plica



Extensive PAM requiring incisional biopsies to determine whether atypia is present.

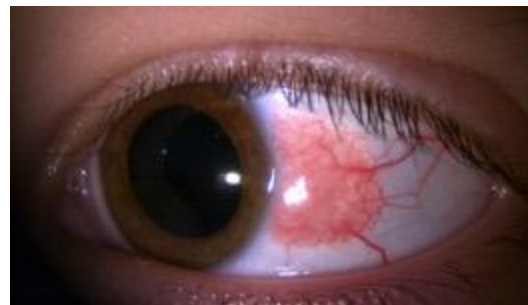

Giant bulbar nevus with multiple clear cysts

If there is no atypia on histology, no treatment is required.

If on slitlamp exam the PAM is limited, patients can be discharged with advice on self-monitoring. If the PAM is extensive, annual review by their local ophthalmologist would be prudent with biopsy if the melanosis increases.

Limited PAM with atypia is treated by local excision with adjunctive cryotherapy. In most patients, the disease is too extensive for excision and topical chemotherapy with mitomycin C is required. (PMID 16970772) Some prefer topical interferon. (PMID35278438) Resistant disease can be treated with liquid nitrogen cryotherapy. After treatment, patients are monitored for recurrence. Biopsies are indicated only if the melanosis increases.



Amelanotic conjunctival nevus in a child

CONJUNCTIVAL NEVUS

Conjunctival nevi usually have clear cysts within them. (PMID34424954) They show varying degrees of pigmentation, which can change over time, and tend to grow in the first two decades of life. (PMID 33199866)

Assessment

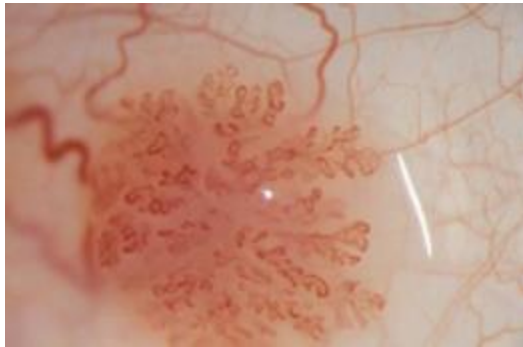
There are no data to indicate whether patients with an unequivocal nevus need surveillance by an ophthalmologist or whether they can safely be entrusted with self-monitoring and discharged.

Treatment

The risk of malignant transformation is less than 1%. There is no consensus as to whether nevi should be excised. Scope for removal is greater with nevi involving non-bulbar conjunctiva because metastasis is more likely if malignant transformation ever occurs.

SQUAMOUS PAPILLOMA

The tumor is diagnosed from its slit-lamp appearance and categorized as pedunculated or sessile and as single or multiple. (PMID31236424)

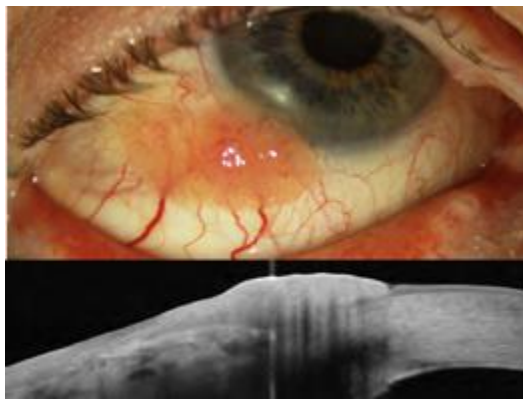


Conjunctival papilloma

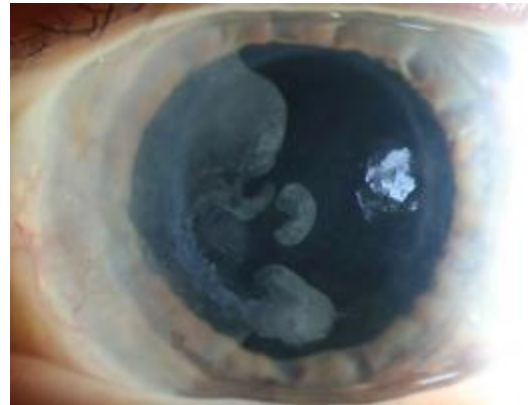Treatment is with topical and/or intralesional interferon because excision is commonly followed by recurrence, despite using a no-touch technique with adjunctive cryotherapy.

OCULAR SURFACE SQUAMOUS NEOPLASIA

Different terms for this include 'conjunctival and corneal intra-epithelial neoplasia (CCIN)' and 'conjunctival squamous intra-epithelial neoplasia (CSIN). (PMID34395915) This ranges from mild dysplasia to carcinoma in situ, confined to the epithelium. It can progress to invasive squamous cell carcinoma.



Conjunctival papillomatous carcinoma in situ. Excision biopsy is usually needed to exclude invasive carcinoma, but this patient was treated successfully with topical 5-FU alone because of his poor health.



Corneal squamous intra-epithelial neoplasia

Assessment

To differentiate this condition from a pagetoid variety of sebaceous carcinoma, it is necessary to perform multiple biopsies, using immunohistochemistry.

Management

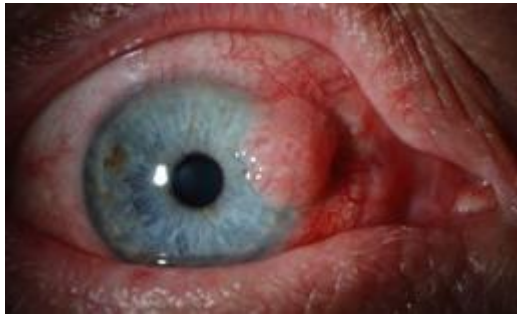Because of the diffuse nature of this lesion, complete excision is difficult so that recurrences are common without adjunctive cryotherapy and/or topical chemotherapy, consisting of either interferon or 5- fluorouracil. (PMID34395915)

Some prefer 5-FU to interferon because it is less expensive and more convenient for patients, requiring treatment over 16 days instead of four months and not needing refrigeration. (Cooling precipitates the 5-FU drug, making the drops ineffective). There is some evidence that 5-FU is more effective than interferon for more advanced disease. Mitomycin-C is reserved for resistant disease. (PMID 16970772)

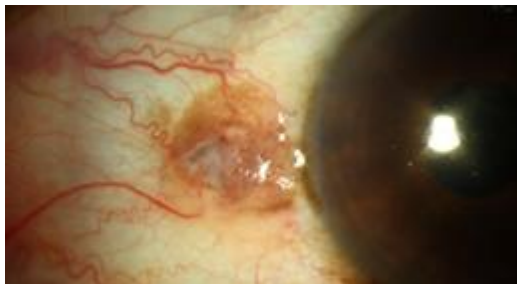As with Mitomycin-C topical chemotherapy, patients need to be advised to wear gloves when administering drops, to apply Vaseline to the lower eyelid to protect the skin, and to store soiled items in a special container, which must be taken to a pharmacy for safe disposal. Some authors advocate digital compression of the lacrimal sac for five minutes when the drops are instilled, to prevent canalicular obstruction.

INVASIVE CONJUNCTIVAL CARCINOMA

The term 'conjunctival squamous carcinoma' implies that the tumor is invasive, unless otherwise specified by the term 'in situ'.



Papillary conjunctival carcinoma



Pigmented squamous cell carcinoma in an African patient

Assessment

It is important to note whether the tumor is focal, diffuse or mixed. Anterior segment examination is performed to exclude intraocular spread, which causes glaucoma and pseudo-uveitis. The regional nodes are palpated.

Management

The standard treatment is local excision of any nodules. Some advocate histological assessment of clearance with frozen sections at the time of surgery. If the cornea is involved, the tumor is removed after devitalizing the epithelium with 95% alcohol. Bowman's layer is conserved as this is a barrier to intraocular spread. Adjunctive cryotherapy, radiotherapy or topical chemotherapy with 5-FU may reduce the chances of recurrence. Advanced disease may require enucleation or exenteration. After treatment, life-long surveillance is required as recurrence can occur after many years.

SEBACEOUS GLAND CARCINOMA

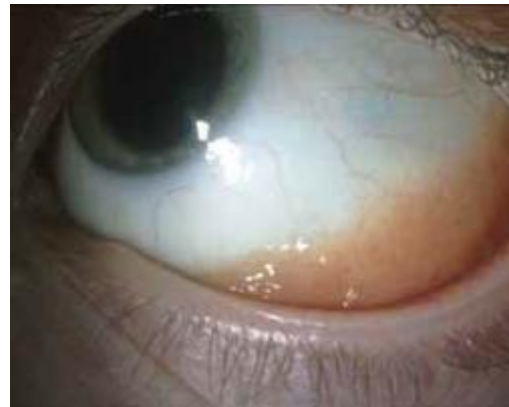
In the absence of a nodular eyelid tumor, pagetoid spread of sebaceous gland carcinoma across the conjunctiva can occur de novo. (PMID35966121) This condition should be considered in any patient with unilateral blepharoconjunctivitis, especially if this does not resolve with standard treatment.

Biopsy is necessary to confirm the diagnosis, using special lipid stains and immunohistochemistry. The regional nodes are palpated for metastases.

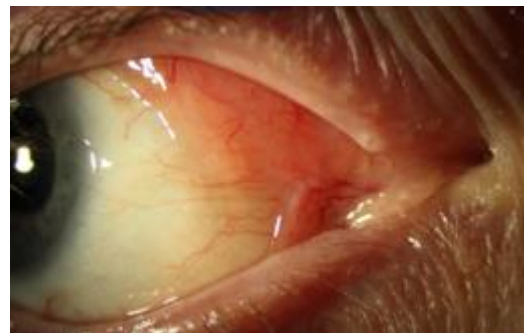
Surgical excision is not usually possible because the disease is extensive. Success has been reported with topical Mitomycin-C chemotherapy, which may avoid the need for exenteration. Life-long monitoring is needed. The five-year mortality is about 15 percent.

CONJUNCTIVAL LYMPHOMA

Conjunctival lymphoma usually presents as salmon-pink nodules, usually in the fornices and caruncular areas, often bilaterally. (PMID 35882984)



Conjunctival lymphoma, with typical salmon-pink color



Conjunctival lymphoma is often most prominent medially, around the plica

Assessment

Bilateral examination of the fornices is essential with palpation of the regional nodes.

Biopsy is required to confirm malignancy and to subtype the tumor. Most conjunctival lymphomas are of B-cell type, and the three most common are: (a) extranodal marginal zone B-cell lymphoma (i.e., MALT lymphoma); (b) follicle center lymphoma; and (c) diffuse large cell lymphoma.

Pathological investigations include: (a) demonstration of monoclonality by immunohistochemistry and with the polymerase chain reaction technique; (b) characterization of type of lymphocytic proliferation (i.e., B cell vs T cell); and (c) assessment of tumor cell proliferation rate. It is advisable to consult the pathologist before doing the biopsy to ensure that the sample is handled correctly (e.g., samples in saline and in formalin).

If the diagnosis of lymphoma is confirmed, staging and perhaps systemic treatment are required. The patient is referred to a hematologist with a special interest in this disease.

Treatment

Low-grade lymphomas can be observed without therapy or treated with external beam radiotherapy.

Systemic doxycycline may be tried if there is evidence or suspicion of chlamydia infection (as in endemic areas). High-grade lymphomas require external beam radiotherapy, which may be combined with systemic chemotherapy. Life-long follow-up is required.

CHORISTOMA

Troublesome limbal choristomas can be excised by lamellar dissection, being prepared to perform corneal or scleral grafting. Excision of supero-temporal dermolipoma in the lacrimal gland region is avoided as this can be followed by ptosis, dry eye, and limitation of eye movements.

OTHER CONJUNCTIVAL LESIONS

These include sarcoid granuloma (PMID35593845), pyogenic granuloma (PMID 8720684), amyloid (PMID16818085), dacryops (PMID31512543) and subconjunctival herniated orbital fat (PMID17255763). Further reading on conjunctival tumors. (PMID 31755426)

PATIENT REFERRAL

INDICATIONS FOR REFERRAL

- Any suspected intraocular or conjunctival malignancy, except for intraocular metastases if the diagnosis is certain and if these can be treated at the local hospital by radiotherapist or oncologist.
- Benign tumors requiring specialized treatment (e.g., symptomatic choroidal hemangioma, retinal hemangioblastoma, vasoproliferative tumor, and conjunctival papilloma).
- Suspected paraneoplastic syndromes, such as bilateral diffuse uveal melanocytic proliferation (BDUMP).

METHOD OF REFERRAL

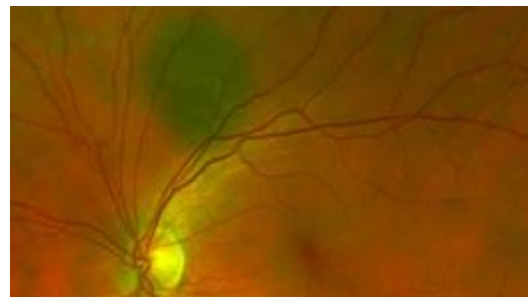
- Advise all patients of the suspected diagnosis, emphasizing the importance of not delaying or cancelling the hospital appointment.
- Instruct patients on what to do if an appointment is not received within a specified time. Give them a number to phone.
- Submit a color photograph (and any other relevant images) of the lesion with the referral. If growth has been documented, the oldest and most recent images should be sent with the referral. These images may avoid the need for a hospital visit if they provide enough information for a report to be given remotely.
- Do not delay the referral because investigations or results are awaited.
- State the suspected diagnosis and describe clinical findings explicitly (e.g., state actual size in mm or DD instead of writing 'large'). Also indicate the tumor location, including the quadrant (e.g., superior choroidal).
- Attach any investigation results including the pathology report if the tumor has been biopsied.

CONDITIONS NOT NEEDING REFERRAL

This section describes a few conditions that should not require referral to an ocular oncologist. However, if there is any uncertainty

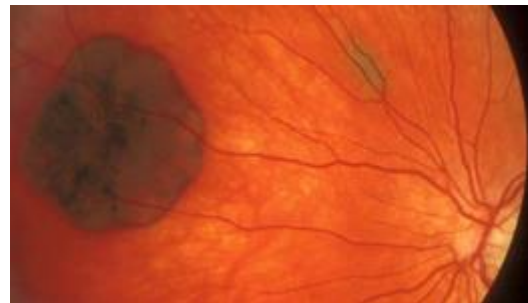about the diagnosis or about the need for referral, it would be reasonable to send images of the lesion to an expert for advice.

- Choroidal nevi with a MOLES score <3 (see section on choroidal nevus).



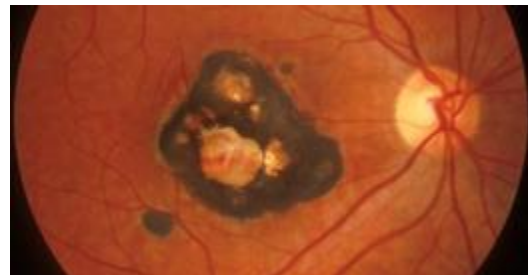Common choroidal nevus (MOLES score = 0)

- Nodular iris nevi with a diameter <5 mm and thickness <1 mm unless growth has been documented.
- Congenital hypertrophy of the retinal pigment epithelium (CHRPE).

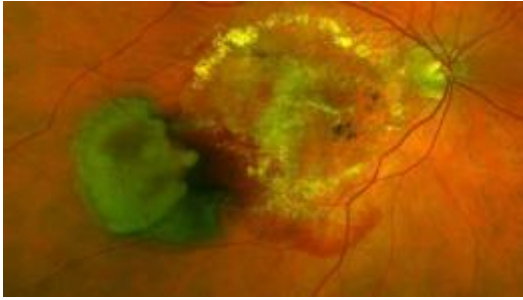


Congenital hypertrophy of the RPE

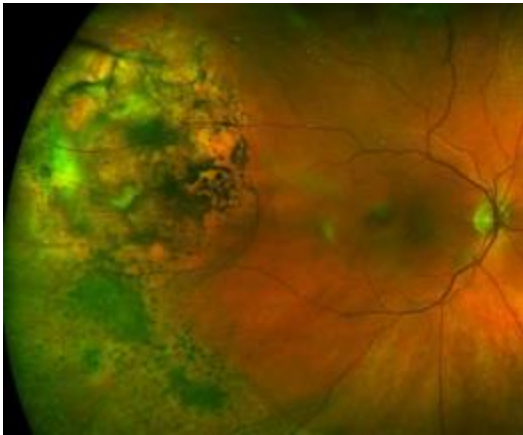
- Chorioretinal scars.



Chorioretinal scar with discrete, irregular margins



Age-related degeneration with subretinal hemorrhage



Age-related RPE disorganization following regression of an eccentric disciform lesion

MONITORING PATIENTS

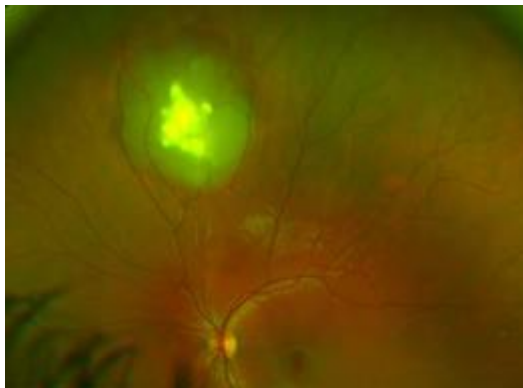
Monitoring should ideally be offered to patients as close to their home as possible. This would be more convenient and less expensive for them especially if they live far from an ocular oncology center.

Ophthalmologists are welcome to request advice from an ocular oncologist regarding frequency and method, if necessary. Images of the lesion and any relevant information would improve the quality of the report.

INDICATIONS

Surveillance for new lesions

- Primary ocular tumors in patients with VHL (retinal angioma, *DICER1* (medullo-epithelioma), congenital ocular melanosis (melanoma), and *BAP1* tumor predisposition syndrome (uveal melanoma).
- Recurrent ocular tumors (e.g., after treatment of uveal melanoma).
- Malignant transformation (e.g., melanocytoma, nevus, retinoma, CHRPE).



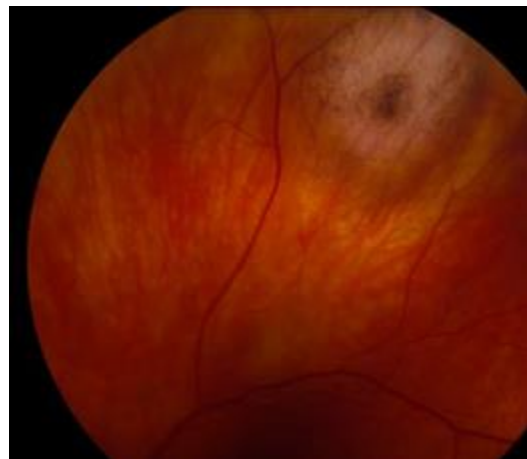
Retinocytoma in a child, with internal calcification. This lesion, if not treated, needs life-long monitoring in case malignant growth ever occurs.

- Systemic malignancy in patients with conditions such as uveal metastasis; ocular paraneoplastic disease (e.g., BDUMP; retinal angioma from VHL, multiple CHRPE lesions (suggesting polyposis coli); familial uveal melanoma (*BAP1* tumor predisposition syndrome), and ocular lymphoma in a patient with systemic or CNS disease.

- Metastatic disease in patients with uveal melanoma (especially liver), conjunctival cancers (especially regional nodes), etc.
- Psychological morbidity needing expert care, especially in patients with poor life expectancy (e.g., uveal melanoma), loss (e.g., of vision), disfigurement (e.g., after enucleation), etc.
- Side-effects and complications of treatment (e.g., radiation retinopathy, uveitis, glaucoma). tumor progression (e.g., nevus growth, osteoma extension, retinal detachment from choroidal hemangioma, necrosis of melanocytoma).
- Ocular side-effects of systemic treatment for cancer.

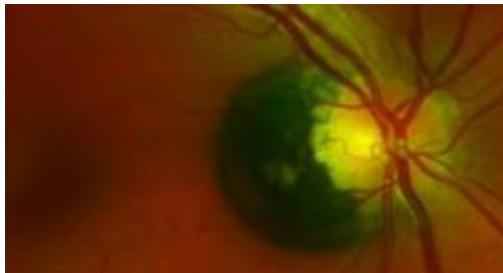
Monitoring of known lesions

- Common choroidal nevi (MOLES = 0). Patients should be reviewed every 1-2 years, ideally with sequential color photography, because very early uveal melanomas can be indistinguishable from common nevi, albeit rarely. OCT and FAF would enable subretinal fluid and lipofuscin to be detected with greater sensitivity. Ultrasonography is not required.
- Suspicious choroidal nevi (MOLES = 1 or 2). These ideally require color photography, OCT and FAF at baseline, then every 6-12 months according to risk of malignancy.



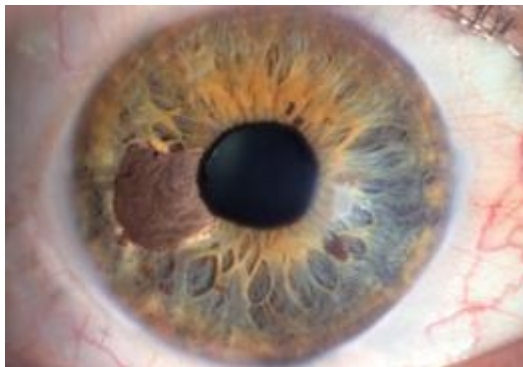Amelanotic choroidal nevus (MOLES = 00100 = 1).

- Congenital hypertrophy of the retinal pigment epithelium (CHRPE). Review every two years is indicated because of the (extremely) low risk of adenoma or adenocarcinoma and in case of mistaken diagnosis. If the lesion is too peripheral to photograph, a detailed drawing of the lesion may suffice.

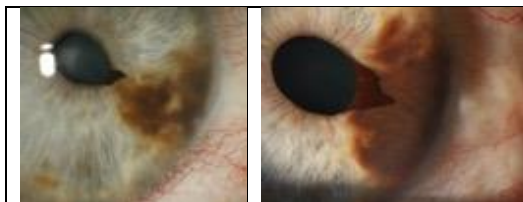


CHRPE lesion, which in this case is unusual because of its juxta- papillary location.

- Iris nevi should ideally be reviewed every 1-2 years, comparing slit- lamp appearances with a baseline color photograph. Gonioscopy is indicated if the tumor involves the angle. Ciliary body spread is detected with UBM or, less reliably, if this US is not possible, by noting sentinel vessels.

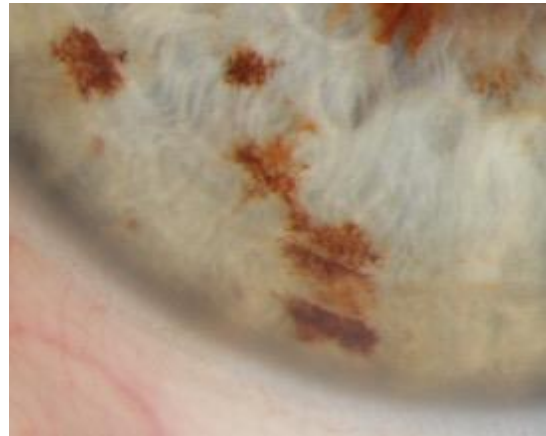


Monitoring by an ophthalmologist is indicated for iris nevi that are more than 3 mm in diameter or involving angle



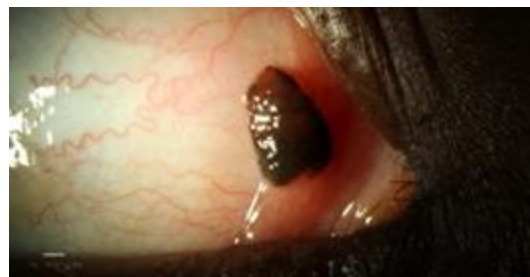Growth of an iris melanoma

- Iris freckles do not require any monitoring unless they cannot reliably be differentiated from nevi. Freckles tend to form a 'canopy' of pigmented cells on the iris surface, unlike nevi which disturb the iris anatomy.



Freckles, which overlie the iris, without disturbing the underlying anatomy

- Iridociliary cysts can be monitored by an ophthalmologist, if necessary. In some cases, diagnosis may need to be confirmed by an ocular oncologist with UBM if this is not available at the local hospital.
- Conjunctival nevi can undergo malignant transformation, albeit rarely (< 1% cases). They should be reviewed every 6-12 months, comparing slit-lamp appearances with baseline photographs. In addition to monitoring by an ophthalmologist, patients could be advised to self-monitor using a mirror or camera, if possible.



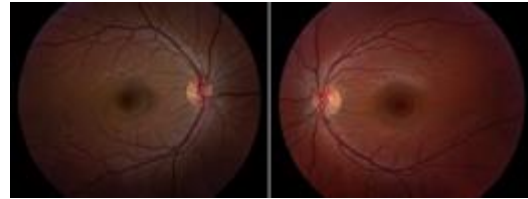
Conjunctival nevi require surveillance if self-monitoring is difficult because of their location or if differentiation from melanoma is uncertain or if involving non-bulbar conjunctiva where any malignant transformation is associated with an increased risk of metastasis.

- Primary acquired conjunctival melanosis if limited to a small area (i.e., diameter < 5 mm) can be monitored locally, with referral to an ocular oncologist only if the pigmentation becomes more extensive. Patients with a small area of perilimbal

pigmentation can self-monitor (alone or in addition to any surveillance by an ophthalmologist), using a mirror or camera. As with other lesions, baseline photography of the lesion is ideal.

- Choroidal hemangiomas require monitoring if asymptomatic and are treated only if causing retinal detachment or visual symptoms.
- Choroidal osteomas not involving the fovea need monitoring in case PDT is indicated because of growth threatening vision. Patients should be advised to present immediately if they develop symptoms, in case a neovascular membrane requires urgent treatment.
- Eccentric disciform lesions usually regress after a few weeks, when the patient can be discharged.
- von Hippel Lindau syndrome requires ophthalmic monitoring because of the risk of retinal hemangioblastomas, which resemble microaneurysms when small.
- Melanocytoma is a high-risk nevus, requiring life-long monitoring (i.e., annual review).
- Congenital ocular melanocytosis is associated with a 1-in-400 risk of melanoma, requiring long-term monitoring. It is important to exclude ciliary body melanoma, looking for

episcleral sentinel vessels if high-frequency ultrasonography is not available.



Congenital ocular melanosis of the right eye requires monitoring for uveal melanoma

These recommendations are only tentative as there is no consensus amongst ocular oncologists on monitoring. As mentioned, if any concerns or uncertainties ever arise, images of the lesion can be sent to an ocular oncologist for expert opinion.

COUNSELLING

- Ophthalmologists should provide all necessary information and guidance, emotional support and reassurance, not only to patients but also accompanying persons.
- It is also essential to provide advice the family doctor as well as any specialists involved in the patient's care (e.g., medical oncologist, geneticist).

OCULAR SURVEILLANCE

In general, patients should be reviewed at their local hospital approximately:

- 1 week after any intraocular procedure.
- 1 month after extraocular treatment (e.g., plaque radiotherapy, enucleation, conjunctival tumor excision).

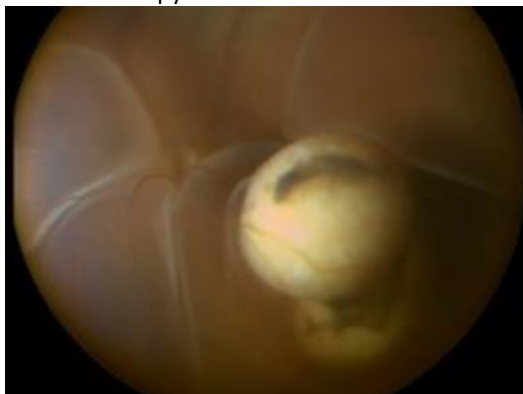
The follow-up schedule is planned at the discretion of the ocular oncologist, who also decides when the patient can be discharged to the patient's local hospital, according to the risk of local tumor recurrence and other ocular morbidity as well as the patient's ability to travel to the oncology center.

The discharge letter from the ocular oncology center will recommend care for each individual patient, with advice on problems that are most likely to occur.

IMMEDIATE POST-OPERATIVE PERIOD

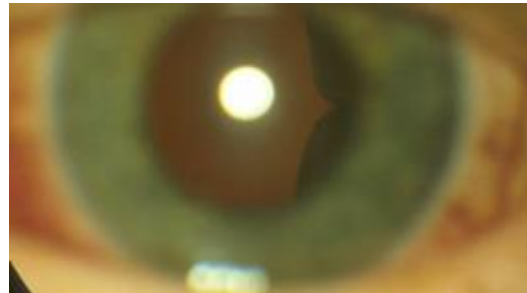
The most likely problems are:

- Raised intraocular pressure after vitrectomy, intravitreal steroid injection, or topical steroid therapy.
- Rhegmatogenous retinal detachment after local resection of an intraocular tumor.
- Endophthalmitis after any intraocular procedure.
- Orbital cellulitis after enucleation
- Hypotony after iridocyclectomy or cyclochoroidectomy.
- Severe exudative retinal detachment after radiotherapy.



Severe exudative retinal detachment after proton beam radiotherapy of a choroidal melanoma, which was successfully treated by endoresection of the 'toxic tumor'. Alternatively, intravitreal anti-VEGF injection may be successful.

- Corneal dellen after treatment of a medial conjunctival or intraocular tumor.
- Diplopia after extraocular muscle disinsertion.
- Allergy to any topical medications.
- Adverse reactions to any oral medications.
- Conjunctival dehiscence after conjunctival tumor excision or plaque radiotherapy. Irradiated sclera can melt if exposed, so that urgent conjunctival repair is indicated if dehiscence occurs.
- Uveal effusion after plaque radiotherapy for choroidal melanoma, a rare but potentially serious problem.

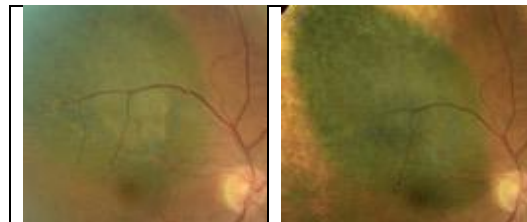


Uveal effusion after plaque radiotherapy for choroidal melanoma, a rare but potentially serious problem

LONG-TERM TUMOR MONITORING

As a rule, patients are reviewed every 6 months for four or five years, then annually.

- Local recurrence of posterior uveal tumor is best identified by sequential photography, noting lateral extension of margins towards adjacent landmarks or the appearance of greater bulk.



Recurrent choroidal melanoma following plaque radiotherapy. Note the tumor growth towards the optic disc.

Ultrasonographic detection of tumor growth is rare in the absence of other signs. (PMID 34830987) If thickness is measured, this dimension should exclude sclera and retina.

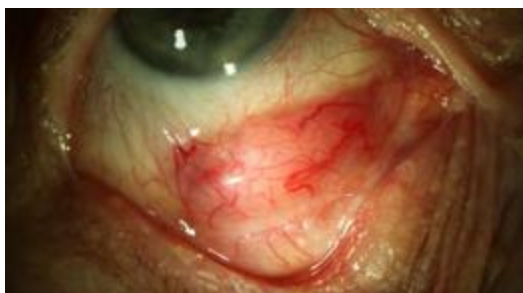Any apparent increase in thickness not exceeding 0.5mm should be regarded as measurement variation and the examination should be repeated several months later. Ultrasonography is also useful for detecting extraocular recurrence (which is rare). Life-long monitoring is ideal as tumors can recur many years after treatment (albeit rarely).

- Local recurrence of iris melanoma is detected by slit-lamp examination and gonioscopy, aided by sequential imaging.



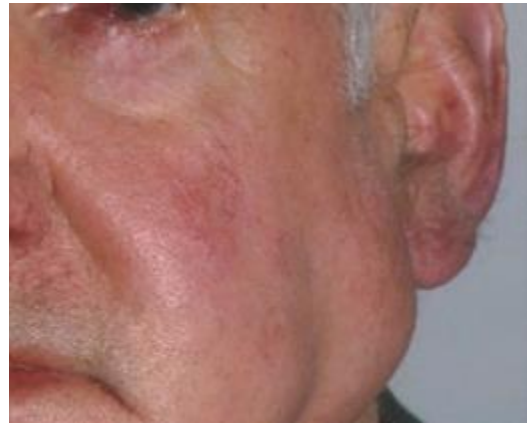Recurrent iris melanoma following proton beam radiotherapy

- Local tumor recurrence of intraocular metastasis is rare after radiotherapy and more common after other forms of treatment. Surveillance is performed as for uveal melanoma, but more frequently because metastases grow more rapidly.
- Local recurrence of a conjunctival tumor should be detectable by slit-lamp examination. It is essential to examine the entire conjunctiva, including the fornices.



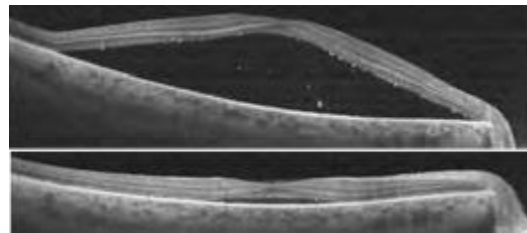
Recurrent conjunctival melanoma in inferior fornix

- Regional nodal metastases after treatment of a conjunctival tumor should be excluded by examining local lymph nodes by palpation at every visit and, if the risk of metastasis exceeds 5%, ultrasonography .



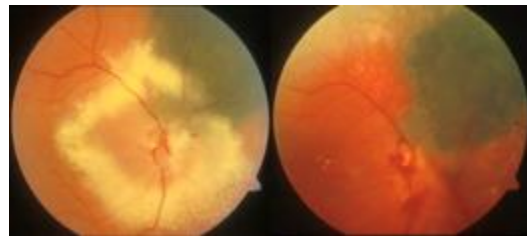
Pre-auricular metastasis from conjunctival melanoma

- Metastases from uveal melanoma are best detected by liver imaging (e.g., US or MRI).
- Macular edema and epiretinal membranes are detected by visual acuity testing and OCT.



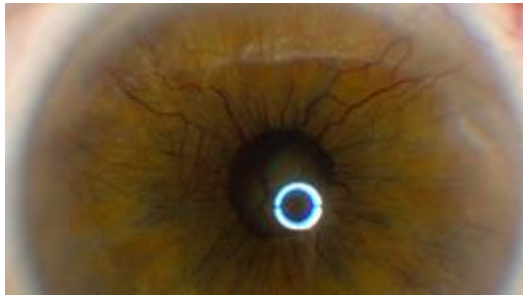
Serous retinal detachment after proton beam radiotherapy of a superior choroidal melanoma in the right eye (upper image), successfully treated by transpupillary laser therapy to the irradiated tumor after unsuccessful anti-VEGF therapy and photodynamic therapy (lower image)

- Radiation optic neuropathy needs close monitoring in case disc new vessels and neovascular glaucoma develop.



Optic neuropathy after proton beam radiotherapy of a juxtapapillary choroidal melanoma in the right eye, showing exudation (left) and, at a later date, neovascularisation with vitreous hemorrhage in the same eye (right)

- Exudative retinal detachment after brachytherapy or proton beam radiotherapy usually resolves spontaneously after a few months but may cause neovascular glaucoma if prolonged or severe.



Iris neovascularisation after proton beam radiotherapy for choroidal melanoma. This usually causes neovascular glaucoma requiring enucleation

- Cataract is not uncommon after ocular radiotherapy or intraocular surgery. It is diagnosed in the usual manner.
- Glaucoma can be caused by steroid treatment, vitrectomy and iris neovascularization and requires gonioscopy, as with other causes.
- Diplopia can occur after extraocular muscle disinsertion during plaque or tantalum marker insertion. This usually resolves spontaneously, especially if there is binocular single vision in any direction of gaze.
- Vitreous hemorrhage is common after trans- retinal tumor biopsy and usually resolves spontaneously. After trans-scleral local resection ('exoresection'), vitreous hemorrhage indicates a retinal tear requiring urgent treatment.
- Corneal dellen can develop if the medial bulbar conjunctiva is swollen. This responds to antibiotic ointment applied frequently.
- Scleral melt is a serious complication and can occur if irradiated sclera is exposed (e.g., after conjunctival wound dehiscence). A scleral graft is usually necessary. Some prefer autologous grafts from another part of the same eye.
- Limbal stem cell deficiency can follow radiotherapy or topical chemotherapy.
- Keratopathy can be caused by keratinization of the superior tarsal conjunctiva following proton beam radiotherapy if the upper eyelid margin is included in the radiation field. The patient (or a relative or carer) may be able to wipe the keratin away from the tarsal conjunctiva with a cotton bud.

SYSTEMIC SURVEILLANCE FOR METASTASIS

INDICATIONS

Opinions vary as to which patients should undergo long-term surveillance, which investigations should be performed, by whom, how frequently, and for how long.

Some oncologists recommend surveillance of all patients. After considering the advantages and disadvantages of such management, others restrict this to patients whose risk of metastasis exceeds a specified threshold (e.g., 10% at 10 years), taking account of the sensitivity and specificity of the prognostic and surveillance methods at that time and place. Other important considerations are (a) the patient's preference and (b) the patient's general health and, therefore, the treatment that the patient would receive (i.e., curative or palliative), should metastases ever be detected.

DURATION

After ocular treatment, conditional survival probability generally improves over time, with metastases being detected in approximately 60% of patients within five years of treatment, 20% in the next five years, 10% between 10 and 15 years, and 10% in later years. Metastatic disease tends to develop later in patients with a smaller tumor at the time of treatment and in those whose tumor shows *SF3B1* mutation.

METHODS

- Ultrasonography. In addition to being widely available, relatively inexpensive, and not exposing patients to ionizing radiation, this imaging has a high sensitivity of around 95%, similar to MRI and CT, with a specificity of almost 90% once other lesions, such as cysts and hemangiomas, have been identified by

baseline imaging; however, it requires operator skill and is more challenging in obese patients.

- Magnetic resonance imaging is more sensitive than ultrasonography but much more expensive. Patients who suffer from claustrophobia may not be able to tolerate this investigation.
- Computerized tomography and positron-emission tomography are less sensitive than MRI and expose the patient to ionizing radiation.
- Chest radiography has largely been abandoned for surveillance because, in addition to its radiation hazard, it only rarely detects metastases before liver imaging.
- Liver function tests not sensitive enough to be used alone but can be a helpful adjunct to liver imaging, if levels rise in comparison with baseline results, especially if these exceed the normal range.

For these reasons, many centers rely on liver ultrasonography for surveillance, performing ultrasound-guided biopsy for suspected metastases with magnetic resonance imaging and computerized tomography used to stage the disease if metastases are confirmed.

A tentative generalization, pending further evidence, would involve liver ultrasonography and liver function tests every six-monthly for five years, then once a year for five years, when surveillance is stopped, except in patients whose tumor shows *SF3B1* mutation. Patients with a low risk of metastasis (i.e., less than 10% at 10 years) and those who would be offered only palliative care should metastases ever be detected, would either not undergo any systemic surveillance or would be offered investigations only once a year.

DIAGNOSTIC AND THERAPEUTIC PROCEDURES AT LOCAL HOSPITAL

There are several procedures that could be undertaken safely at the patient's local hospital.

Before any intervention, advice can be obtained from an ocular oncologist, if necessary. In any case, it would be ideal if the ocular oncology center could be informed about any procedures that are performed on patients previously treated at that center, for audit purposes. If any tumor tissue requires histology (e.g., after incisional biopsy of primary acquired melanosis) the pathologist at the local hospital should ideally send the specimen to a specialist ophthalmic pathologist at the ocular oncology center for primary reporting.

CATARACT SURGERY

It should be possible to perform phacoemulsification in the usual manner. Care should be taken if zonules are deficient following iridocyclectomy. Previously treated iris or posterior-segment melanoma is not a contraindication to cataract surgery if the likelihood of active tumor is minimal. This estimate can be provided by an ocular oncologist on request.

Mapping conjunctival biopsies may be performed to exclude minimal residual disease in patients previously treated for conjunctival malignancy.

GLAUCOMA SURGERY

Glaucoma can be managed in the usual manner. If the patient has been treated for an iris or posterior uveal melanoma. If the tumor is sterile it should be safe to perform a drainage procedure, including the insertion of a Baerveldt or other implant. Painful neovascular glaucoma usually requires enucleation.

STRABISMUS SURGERY

Ocular motility disorders can follow muscle disinsertion performed during plaque or

tantalum marker insertion or during trans-scleral local resection.

The muscle surgery can be difficult because of extensive scarring surrounding the muscle and adhering the conjunctiva to the sclera. One method of overcoming these difficulties is to shave the conjunctiva (and perhaps also the extraocular muscle together with surrounding scar tissue), away from the sclera with a Bard-Parker scalpel, advancing or recessing the muscle and surrounding scar tissue as needed.

Radiotherapy can make the conjunctiva friable and the sclera soft and delicate.

After trans-scleral resection, the sclera may be extremely thin in the region of a lamellar scleral flap and may be located beneath the muscle insertion.

Special care must be taken to close the conjunctiva over irradiated sclera, which may melt if exposed, possibly because of wound dehiscence.

TREATMENT FOR MACULAR EDEMA

Macular edema is a common problem after radiotherapy. This is usually treated with intravitreal injections of anti-angiogenic agents (e.g., bevacizumab, ranibizumab, aflibercept) or anti-inflammatory drugs (e.g., triamcinolone). Care must be taken to avoid retinal damage if a bulky tumor is present (e.g., after radiotherapy). The response to these agents varies greatly between patients. In some cases, the edema recurs when this treatment is stopped so that therapy needs to be continued indefinitely.

We have successfully treated a few patients with resistant macular edema by administering transpupillary thermotherapy or photodynamic therapy to the irradiated tumor.

TREATMENT FOR EXUDATIVE RETINAL DETACHMENT

Serous retinal detachment is most likely to develop after radiotherapy of large choroidal melanomas and can develop rapidly. This condition may respond to intravitreal anti-angiogenic therapy (especially aflibercept, in our experience, or steroid therapy, using a corneal contact lens to see the detached retina and to avoid causing iatrogenic rhegmatogenous retinal detachment.

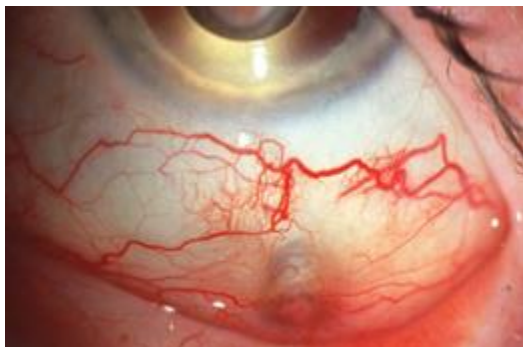Exudative retinal detachment can sometimes be successfully treated by removing the 'toxic tumor' by endoresection or exoresection depending on its size and location.

ENUCLEATION

Enucleation is performed in the usual manner, with surgeons using their preferred orbital implant. Care must be taken not to touch any extraocular tumor nodule, to avoid seeding into the orbit. If the eye is removed for uveal melanoma, genetic typing of the tumor may be useful for prognostication. Fresh or frozen tissue provides better results than formalin-fixed tissue.

REMOVAL OF EXTRUDING TANTALUM MARKER

Tantalum markers threatening to extrude through the overlying conjunctiva should if possible be removed before the conjunctiva ulcerates. Irradiated conjunctiva may be friable, also healing slowly.



Tantalum marker under irradiated conjunctiva following proton beam radiotherapy for choroidal melanoma. Removal of the marker is indicated because of a high risk of conjunctival ulceration and scleral melt. The problem is now avoided by placing markers out of the radiation field.

BIOPSY OF CONJUNCTIVAL PRIMARY ACQUIRED MELANOSIS

Incisional biopsy is required to detect atypia. The procedure is performed under topical anesthesia. Elliptical biopsies are approximately 3 mm long to provide sufficient tissue for histology without requiring suturing. The specimen should be grasped at one point only, to minimize crush artefact. The tissue should be gently placed onto a paper card to avoid scrolling of the specimen. The sample should be transported to the laboratory in formalin.

Incisional biopsy is contraindicated for nodular tumors, because of the risk of seeding tumor cells around the conjunctiva.

EXCISION BIOPSY OF NODULAR CONJUNCTIVAL TUMORS

Malignant nodular conjunctival tumors are best excised by ocular oncologists. If this is not possible, our preferred method is as follows:

- Inject local anesthetic with adrenaline, without the needle touching the tumor, or instill anesthetic drops, with sedation.
- Apply a continuous line of bipolar cautery 2 mm around the tumor margins.
- Excise the tumor, cutting within the cautery line, using blunt-tipped spring scissors, following a no-touch technique and ensuring meticulous hemostasis.
- If the tumor involves cornea, scrape the tumor towards the limbus, after devitalizing the corneal epithelium with 95% alcohol so that it separates easily from Bowman's membrane, which must not be damaged as it is a barrier to intraocular spread.
- Shave the tumor away from the limbus with a Bard Parker scalpel, resecting circumferentially.
- Place the specimen on a card and into formalin, without crushing the tissue with the forceps, marking the card (e.g., by snipping a notch on the card) to orientate the specimen for the pathologist.
- Close the conjunctiva, using fresh instruments, after undermining the conjunctiva widely (i.e., as far as the fornices, avoiding muscle damage).

VITREORETINAL LYMPHOMA BIOPSY

Discuss the biopsy with the pathologist before the procedure so that the laboratory can prepare for analysis and provide the required transport medium. A large, undiluted vitreous sample is needed. If transported without

fixation it must arrive at the laboratory within an hour.

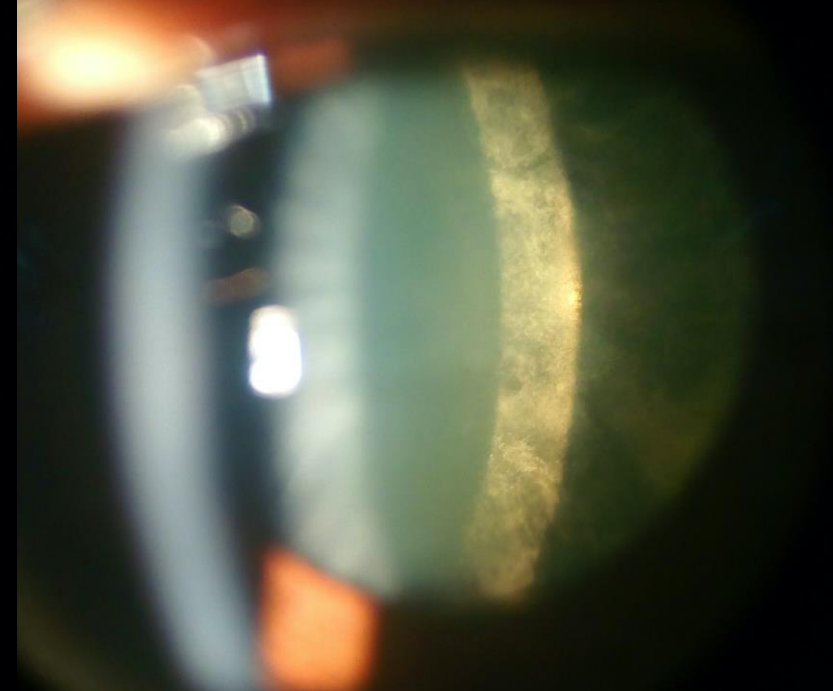
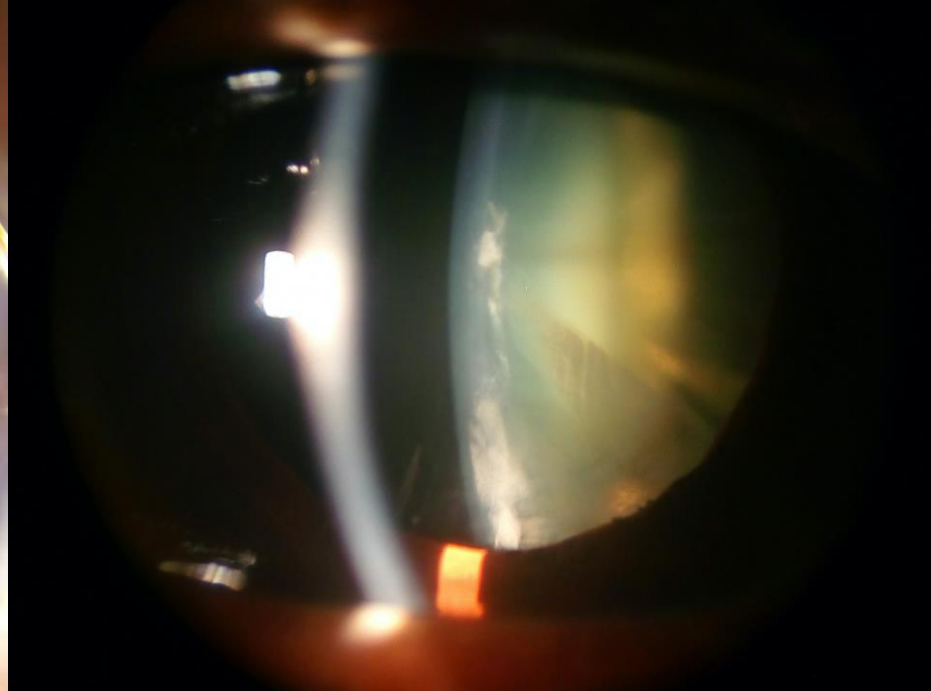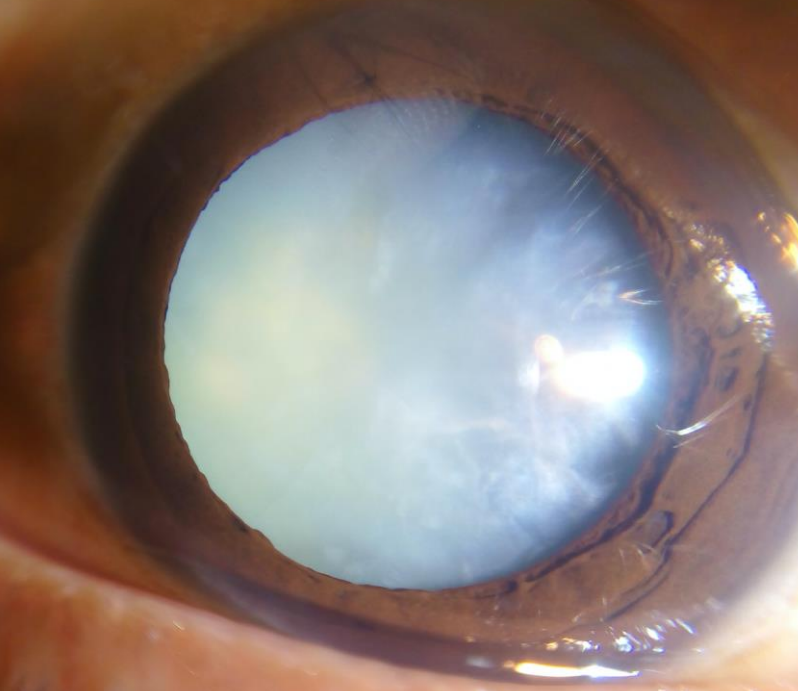
If performing trans-retinal biopsy for a sub-RPE deposit, the sample must be taken from deep inside the tumor, which may consist of necrotic tissue except near the choriocapillaris.

We hope you have found this e-book useful. Please send any comments and suggestions to:
Maria.Fili@regionstockholm.se

Thank you

Sektionen för ögononkologi S:t Eriks Ögonsjukhus

Eugeniavägen 12, 171 64 Solna, Sverige



CATARACTS

- And how to get a satisfied patient

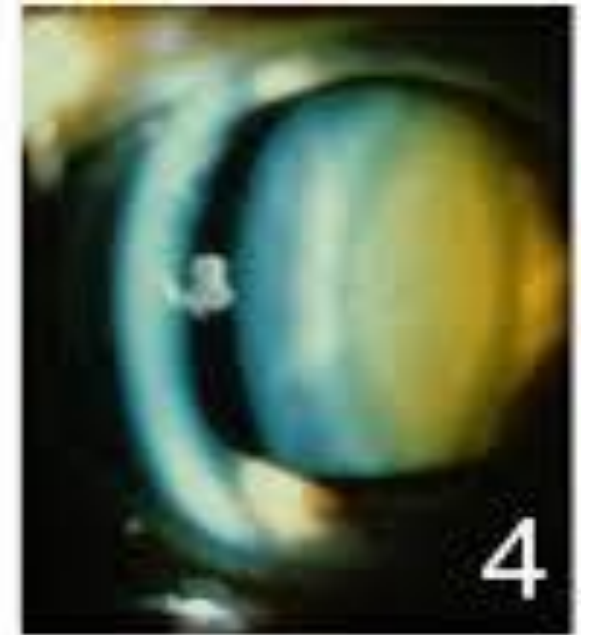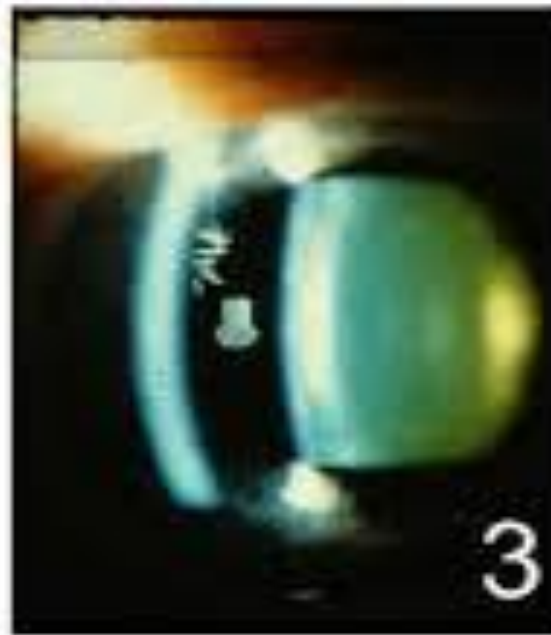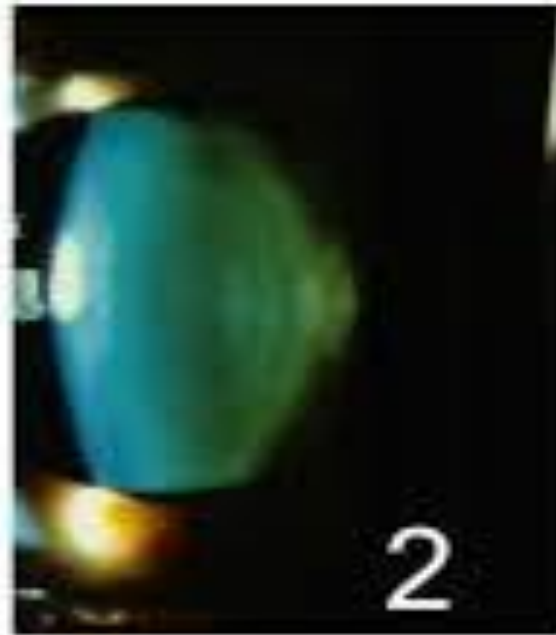
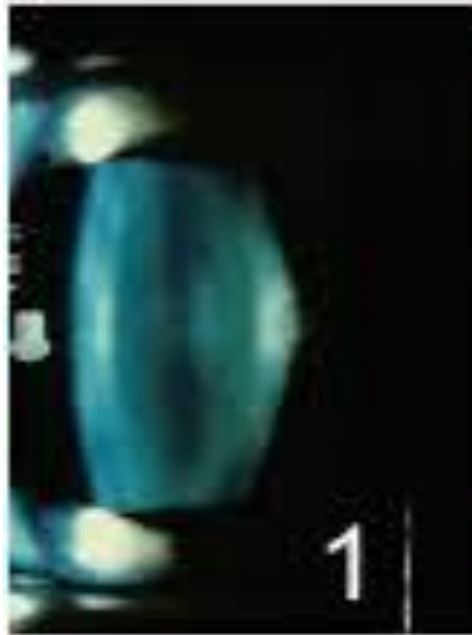Katarina Bartuma, MD, PhD, FEBO

Eye Department, Kristianstad Central Hospital

Ögoncentrum Annedal, Lund

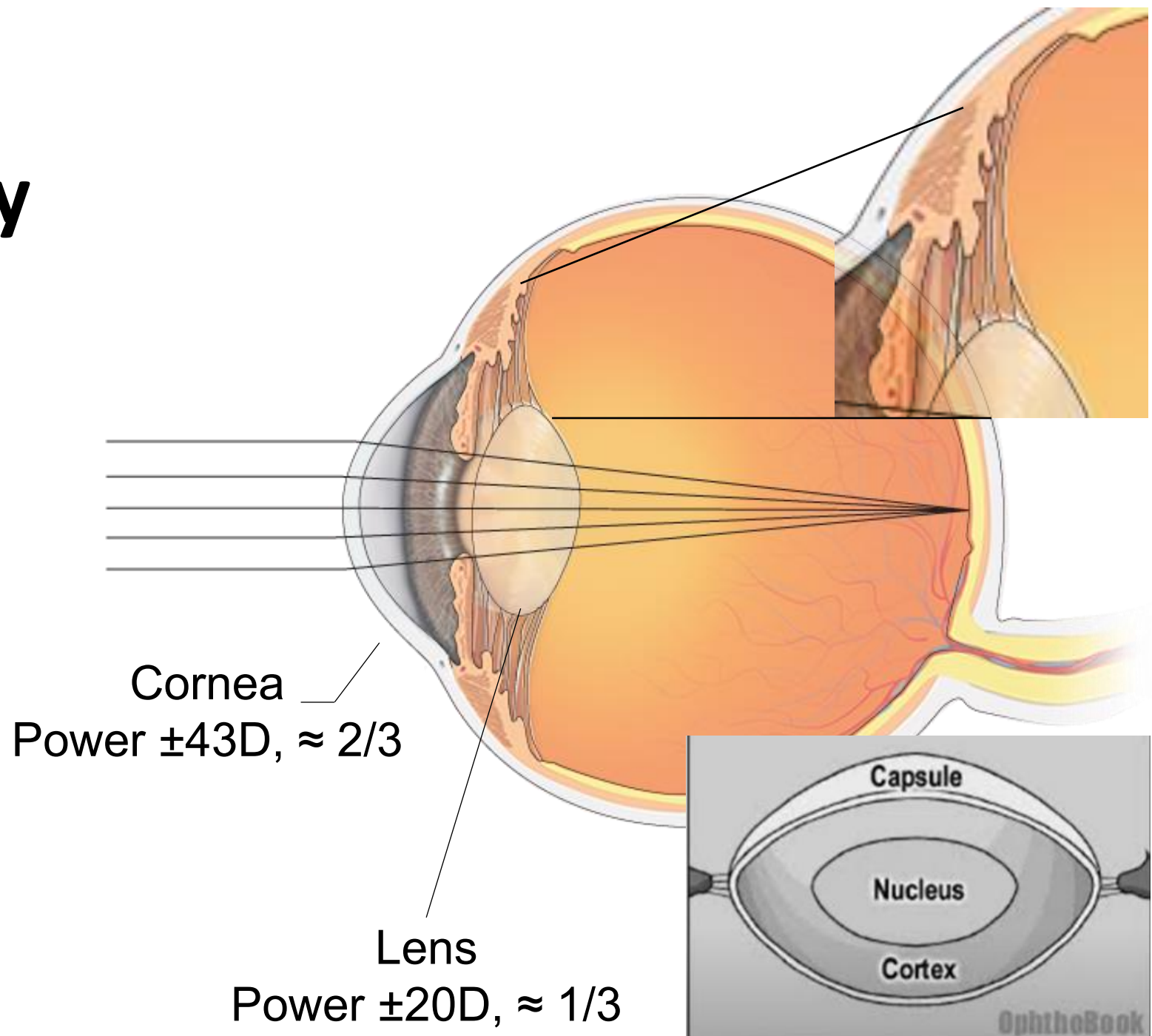
Introduction

- The lens undergoes physiologic changes throughout life
- Cataract: unclear lens that gives rise to visual impairment
- Most common cause of blindness in the world
- Most cost-effective surgery in the world



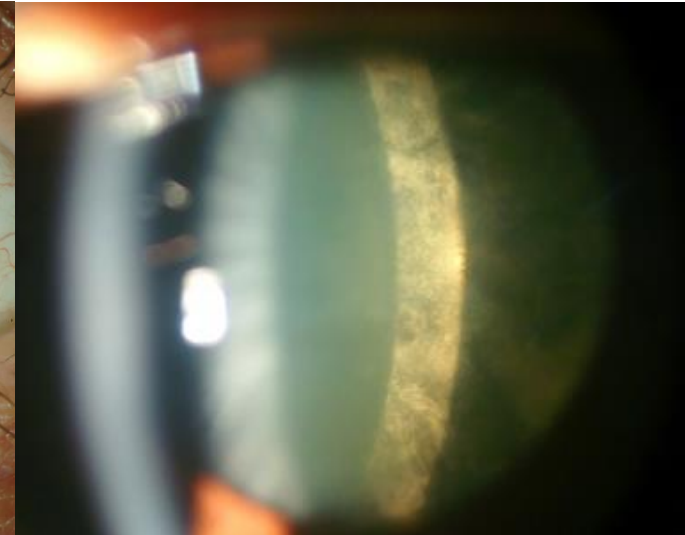
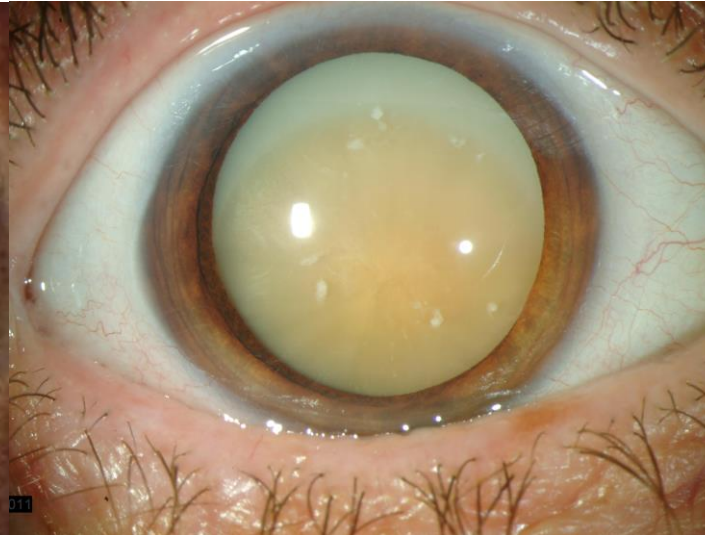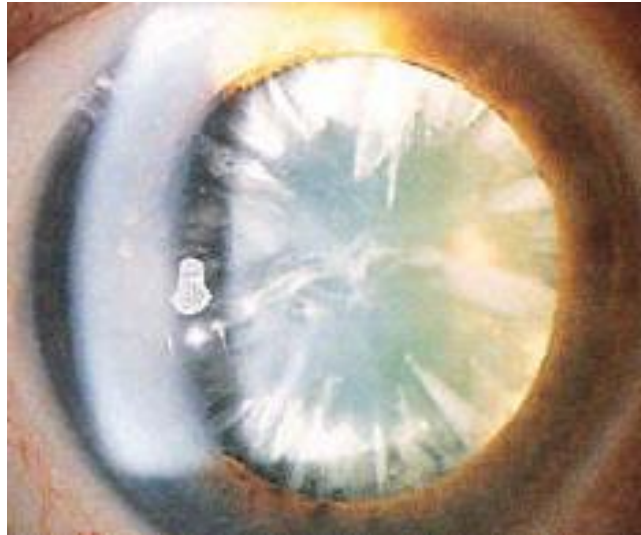
Lens physiology

- Zonules
- Lens capsule
- Lens nucleus
- Lens cortex
- Aims light on the macula



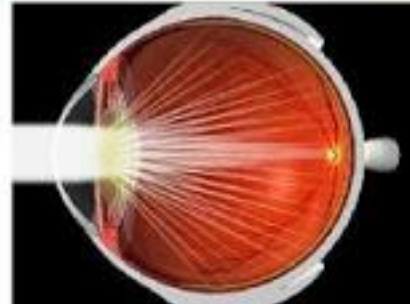
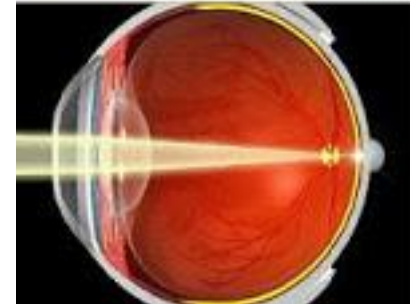
Different types of cataracts

- Cortical cataract 50%
- Nuclear cataract 30%
- Subcapsular cataract 20%



Symptoms

- Slow, gradual, clouded vision at a distance
- Glare, sensitivity to light
- Halos, starbursts around lights
- Developing myopia (nearsightedness)- change glasses often
- Monocular diplopia (double vision in one eye)
- Fading or yellowing of colors
- Painless



What causes a cataract

- Age
- UV-light
- Systemic and metabolic disease: Diabetes, atopic dermatitis
- Other eye diseases: uveitis, retinitis pigmentosa
- Side effects of medicines: cortisone
- Congenital: chromosomal aberrations, intrauterine infections, idiopathic
- Hereditary
- Smoking
- Trauma/ eye surgery
- Radiation

How to get a satisfied patient



Expectations, expectations, expectations!

How to get a satisfied patient

- Things to consider:
- Does the patient want to undergo surgery?
- What is the goal of surgery: increase vision, reduce pressure, improve insight
- Exceptions when the patient is "talked into" undergoing surgery: swelling cataract, pressure reducing surgery, improve insight
- Are there any other reasons for visual decrease


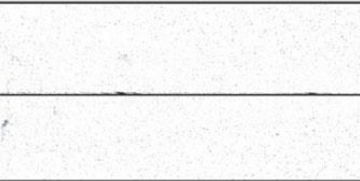


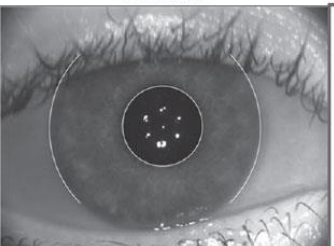
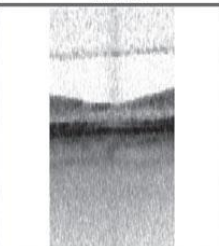
Expectations, expectations, expectations!

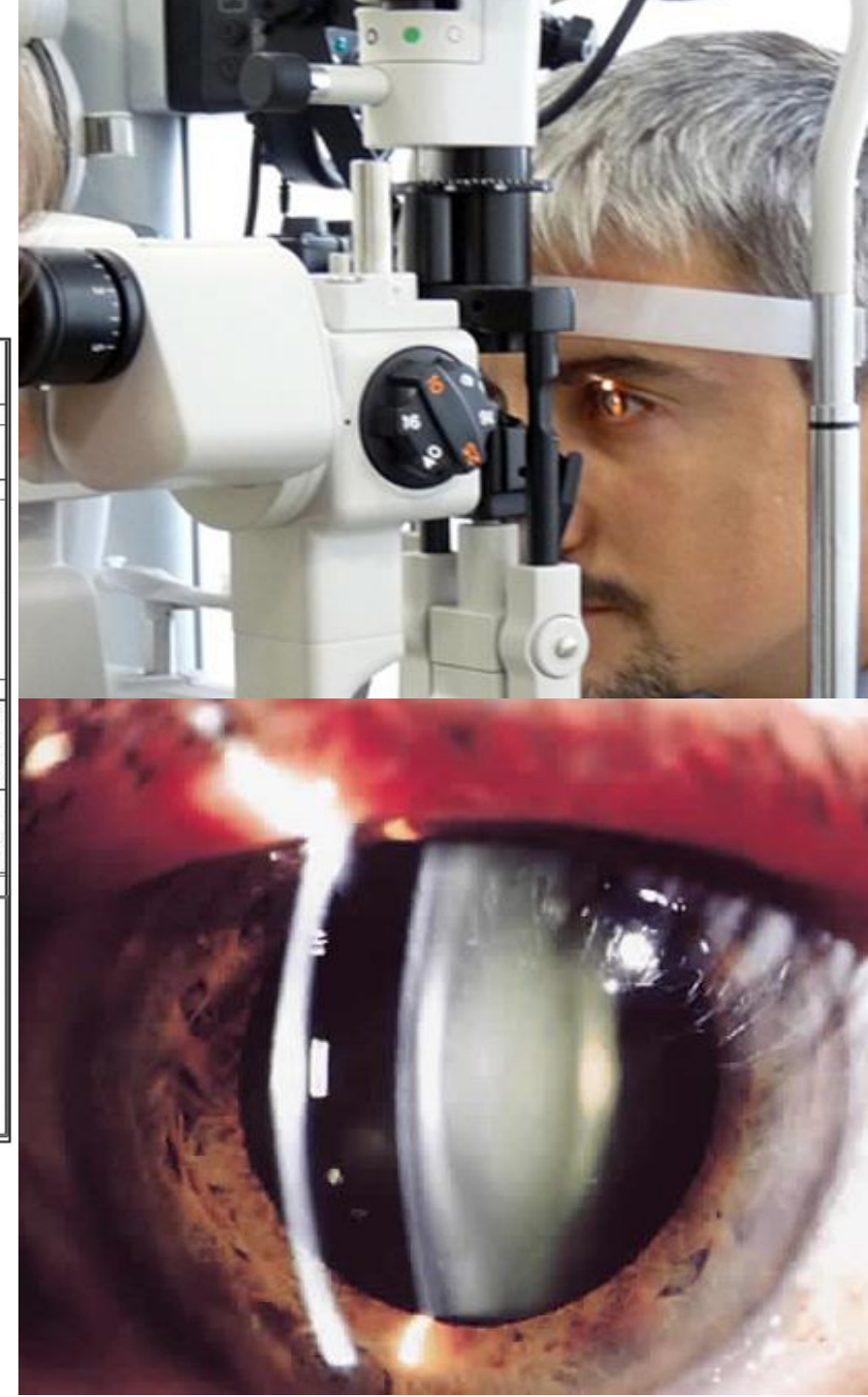
Patient history

- Describe visual problems
- Amblyopia
- Other eye diseases? (glaucoma, retinal disease, cystic macular oedema)
- Trauma?
- Other eye surgery? (refractive surgery, retinal surgery)
- When did the patient receive their first glasses
 - small child <5 years hyperopia
 - 5-16 years myopia
 - 16-20 years astigmatism
 - 50 years and above emmetropia
- Other systemic disease (diabetes, treatment with high levels of cortisone)
- Medication to consider: prostate medication, cordarone
- Can the patient cooperate? (need for anaesthesia, help with post op care)

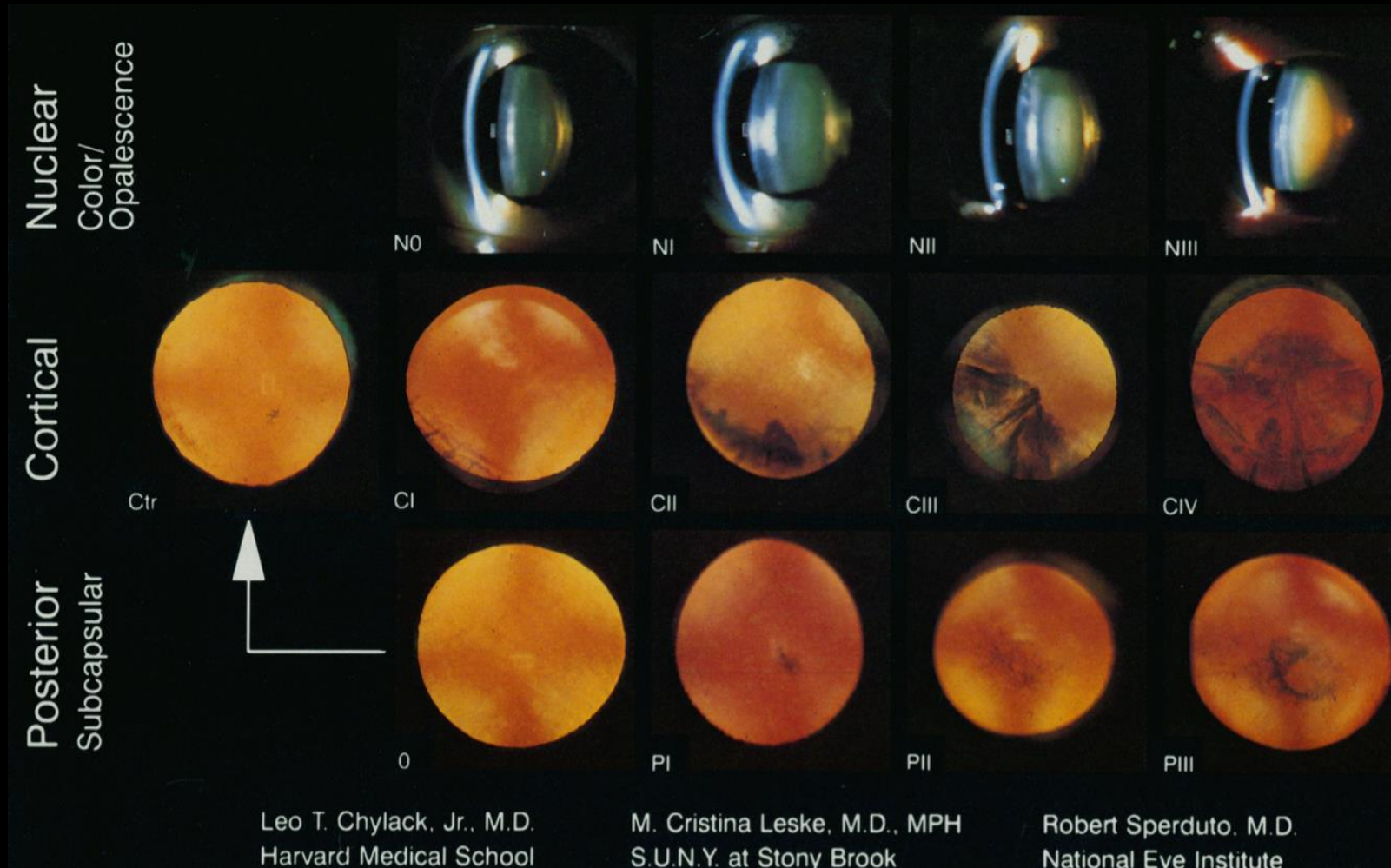
Diagnosis

- Visual acuity with and without glasses
- Glass prescription
- Refraction
- Slit-lamp biomicroscopy
- Biometry
- A-scan ultrasound
- Corneal imaging

OD		Analyze	
right			
Eye status			
LS: Phakic	VS: Vitreous body	LVC: Untreated	
Ref: ---	VA: ---		
Biometric values			
AL: 24.87 mm	SD: 8 μ m	WTW: 12.5 mm	lx: +0.5 mm ly: +0.1 mm
CCT: 534 μ m	SD: 4 μ m	P: 4.7 mm	CW-Chord: 0.1 mm @ 129°
ACD: 4.45 mm	SD: 14 μ m		
LT: 3.80 mm	SD: 15 μ m		
SE: 43.27 D	SD: 0.02 D	TSE: 43.43 D	SD: 0.01 D
K1: 42.83 D @ 179°	SD: 0.03 D	TK1: 43.09 D @ 173°	SD: 0.02 D
K2: 43.73 D @ 89°	SD: 0.02 D	TK2: 43.78 D @ 83°	SD: 0.03 D
Δ K: +0.90 D @ 89°		Δ TK: +0.69 D @ 83°	
B scan			
			
Keratometry	White-to-white	Fixation	
			



Grading of cataracts



Choosing the right IOL (intraocular lens)

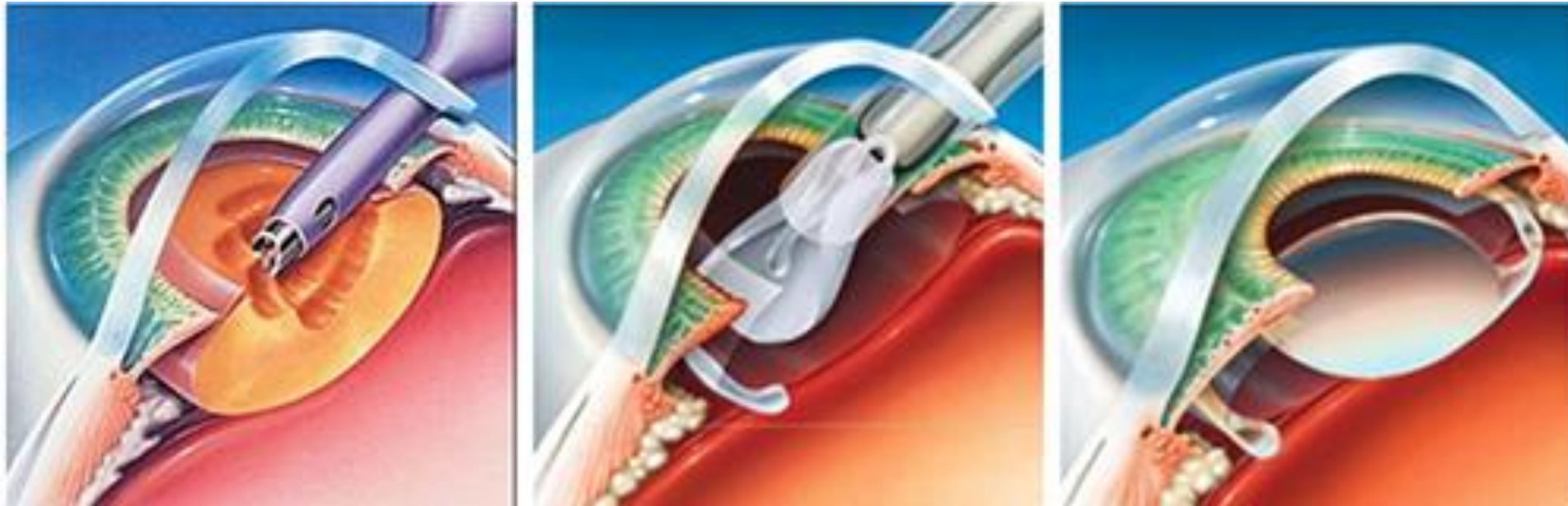- Monofocal
- Monofocal with monovision
- Toric
- Extended depth-of-focus (EDOF)
- Multifocal/trifocal
- Phacic

Is the patient good for surgery

1. Is there a visually significant lens opacity, or other reasons to do surgery
2. Does the lens opacity account for the patients level of vision
3. Is the potential improvement enough to warrant the risks of surgery
4. Can the patient tolerate the surgery and be able to follow postoperative instructions and follow up care

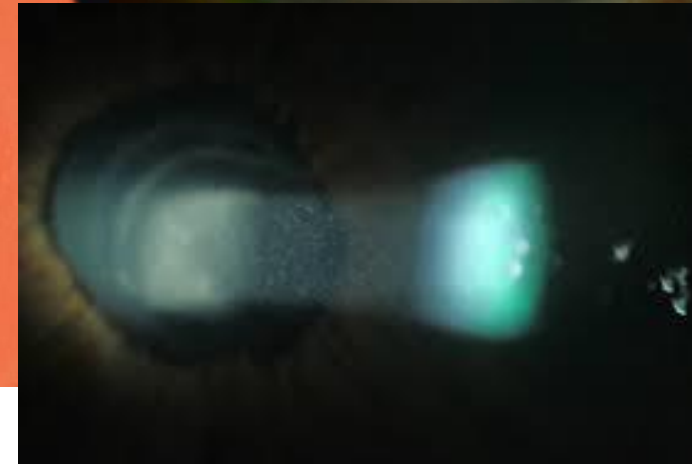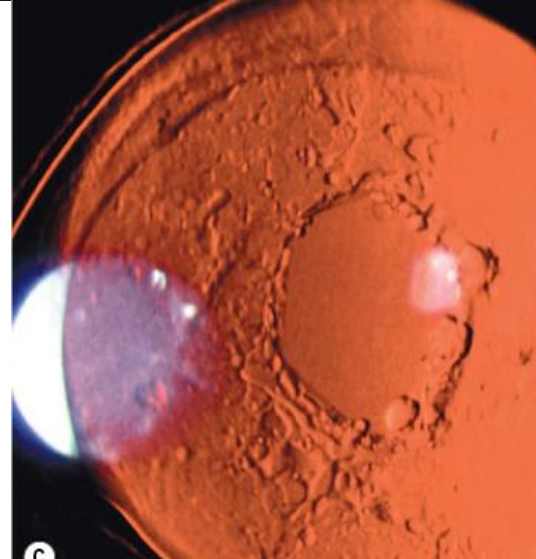
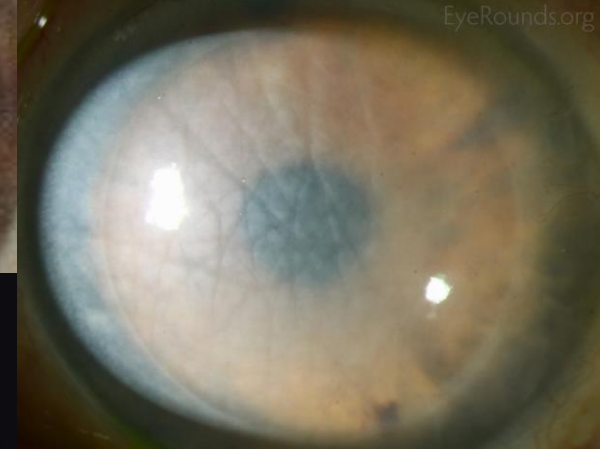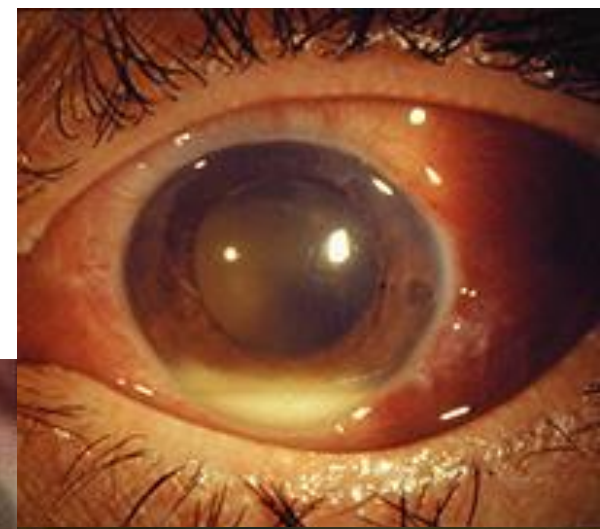
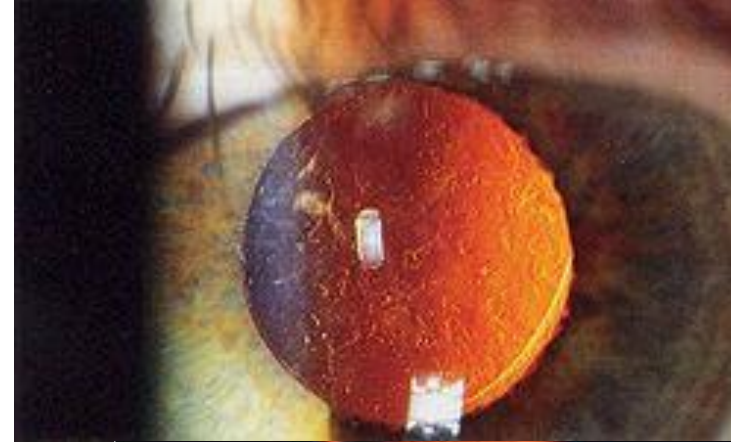
Cataract surgery

- Film <https://www.youtube.com/watch?v=PLSKmeAV43M>

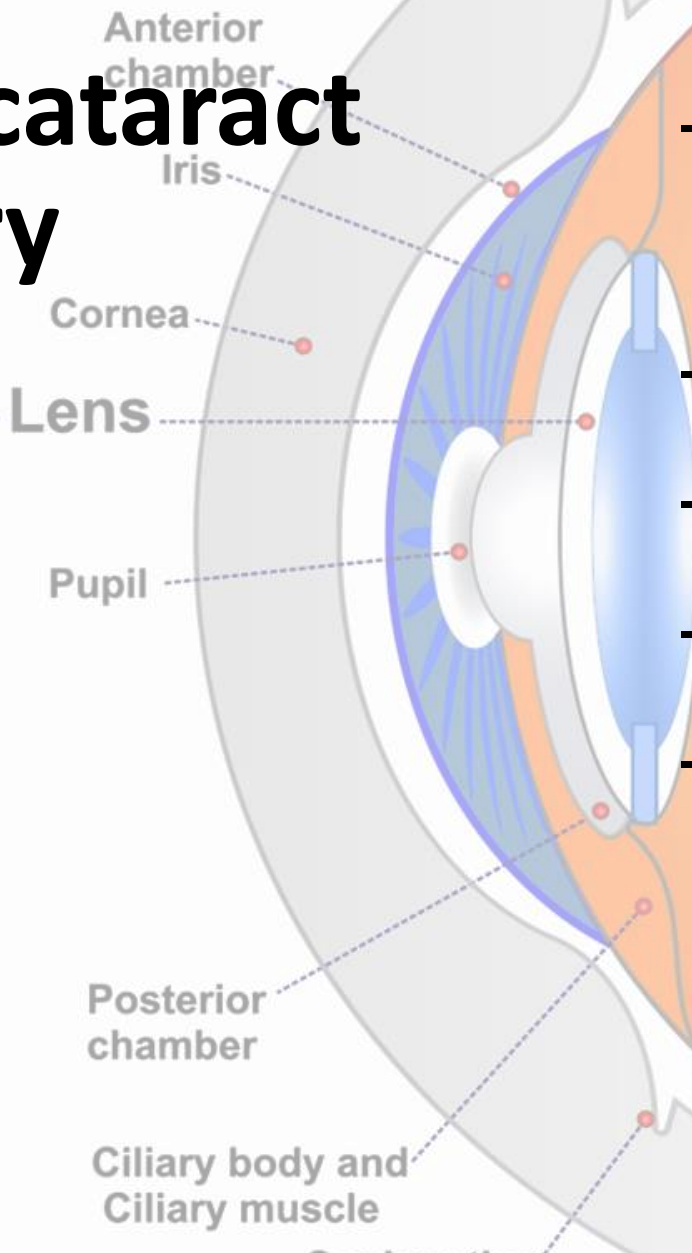



Complications of surgery

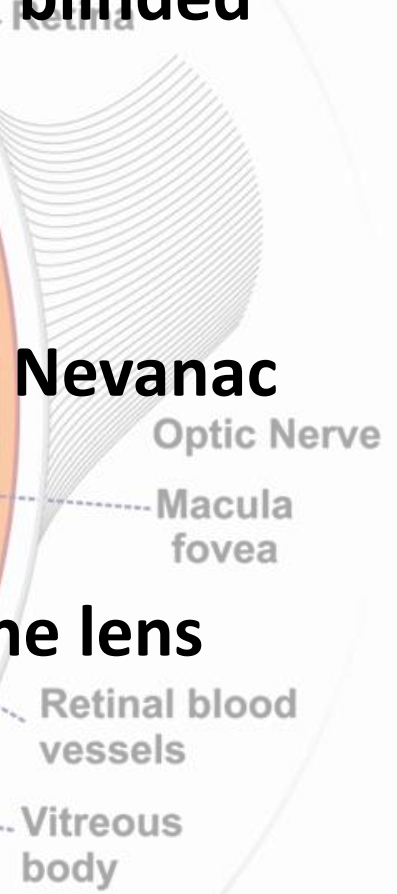
- Endophthalmitis
- Corneal oedema
- Postoperative inflammation
- Postoperative intraocular increased pressure
- Cystic macular oedema
- Posterior capsular opacities (PCO)



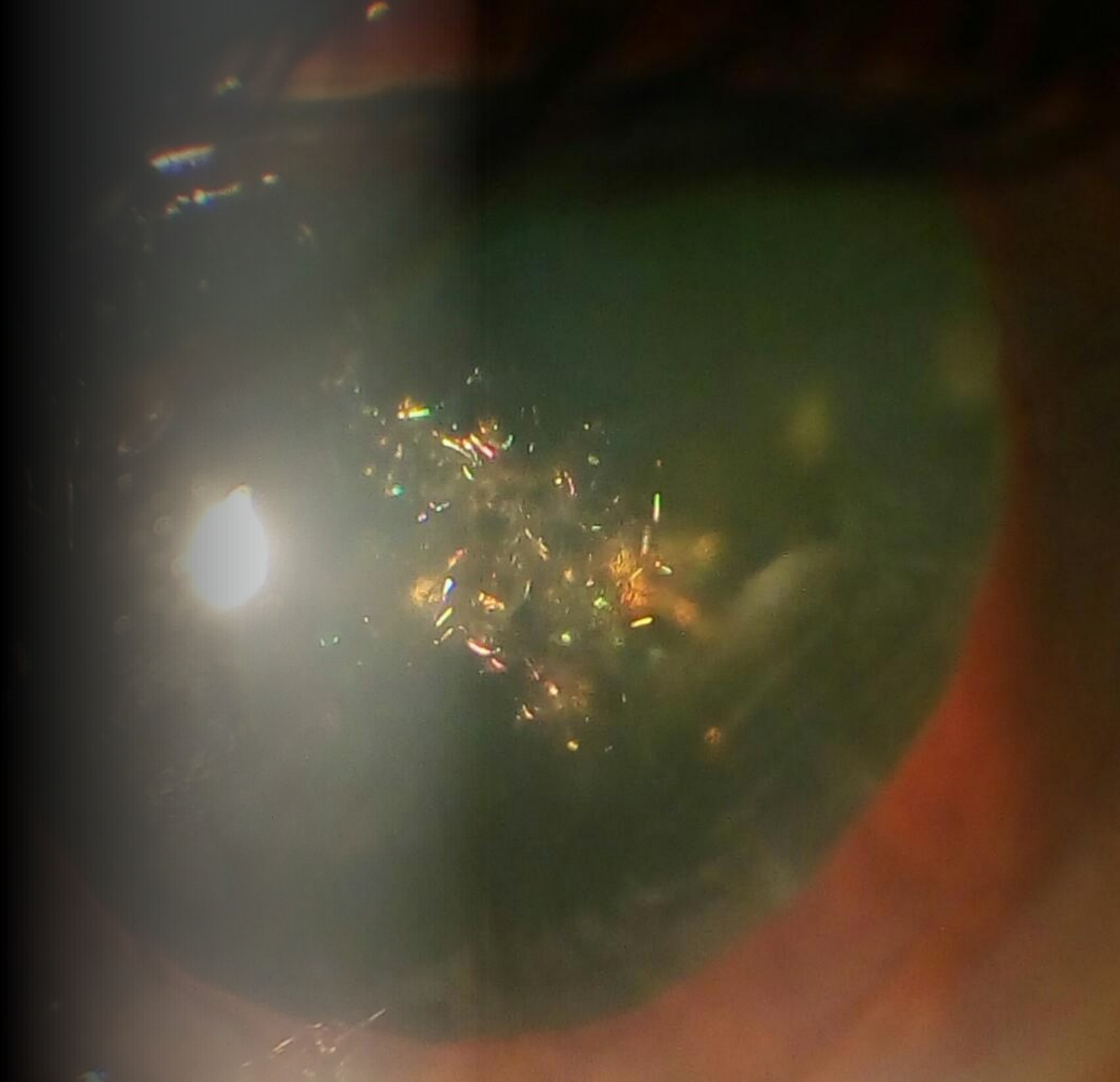
After cataract surgery



- Right after cataract surgery- blinded and blurry vision
- Anti-inflammatory drops
- Dexamethasone, Dicloabac, Nevanac
- Follow up
- 6 weeks following surgery the lens position is stable



THANK YOU



Glaucoma – New Treatments

Dorothea Peters, MD, PhD

Department of Clinical Sciences, Ophthalmology in Malmö, Lund University, Sweden

Department of Ophthalmology, Skåne University Hospital, Lund, Sweden



LUND
UNIVERSITY

 **Skåne University Hospital**



Financial disclosure

- Santen (Speaker honoraria, Consultant)
- Abbvie (Speaker honoraria, Consultant)
- Thea Pharma (Speaker honoraria)

Glaucoma treatment options

- **IOP lowering**
 - Eye drops
 - Laser
 - Surgery
- **Neuroprotection**
 - Citicoline
 - Nicotinamide

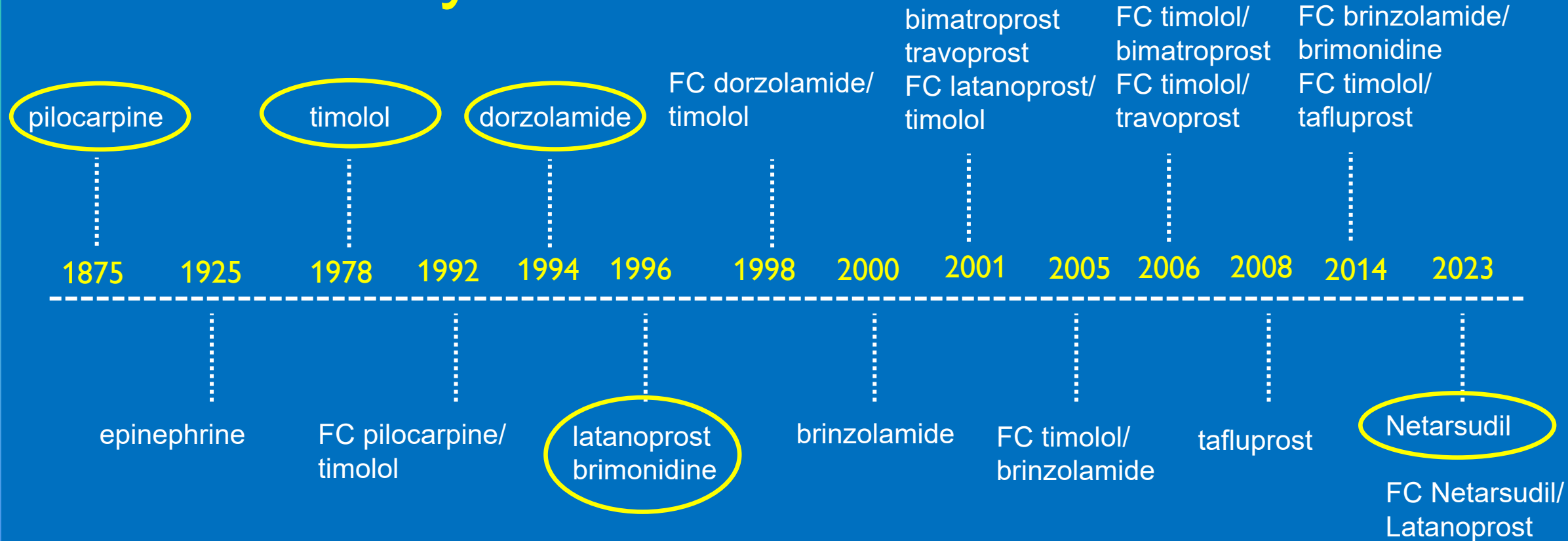
Glaucoma treatment options

- **IOP lowering**

- Eye drops

- New drug – Rho-kinase (ROCK) inhibitor
 - Sustained release drug delivery systems

Glaucoma Treatment – IOP lowering over the last 150 years



FC = fixed combination

Glaucoma treatment options

- IOP lowering
 - Eye drops
 - New drug – Rho-kinase (ROCK) inhibitor
 - Sustained release drug delivery systems

Netarsudil

Netarsudil (Rhokinsa[®]) – no reimbursement in Sweden

FC Netarsudil / Latanoprost (Roclanda[®])

-> IOP lowering due to Rho-kinase inhibition



ROCK-inhibitor and the trabecular meshwork (TM)

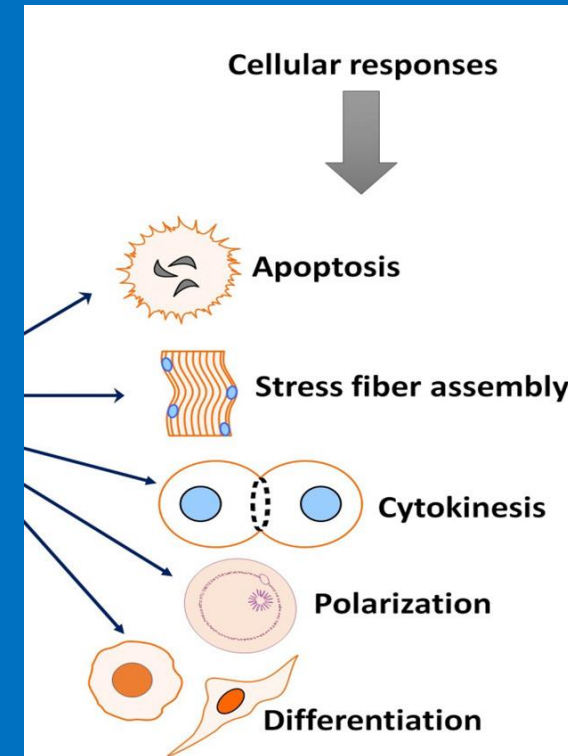
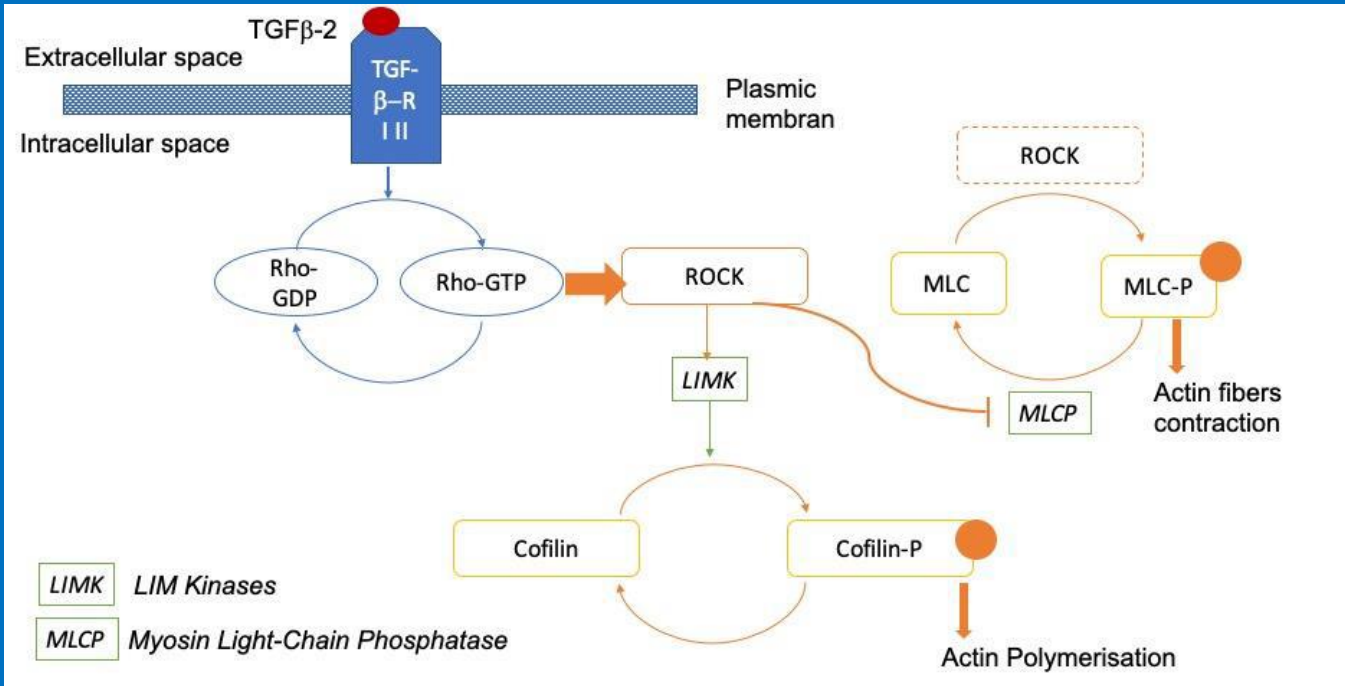


Bild vänster ur: Buffault, J.; Brignole-Baudouin, F.; Reboussin, É.; Kessal, K.; Labbé, A.; Mélik, Parsadaniantz, S.; Baudouin, C. The Dual Effect of Rho-Kinase Inhibition on Trabecular Meshwork Cells Cytoskeleton and Extracellular Matrix in an In Vitro Model of Glaucoma. *J. Clin. Med.* 2022, 11, 1001. License: Creative Commons Attribution (CC BY) license (<https://creativecommons.org/licenses/by/4.0/>)

Bild höger modifierat ur: Saadeldin IM, Tukur HA, Aljumaah RS and Sindi RA (2021) Rocking the Boat: The Decisive Roles of Rho Kinases During Oocyte, Blastocyst, and Stem Cell Development. *Front. Cell Dev. Biol.* 8:616762.

ROCK-inhibitor and the trabecular meshwork (TM)

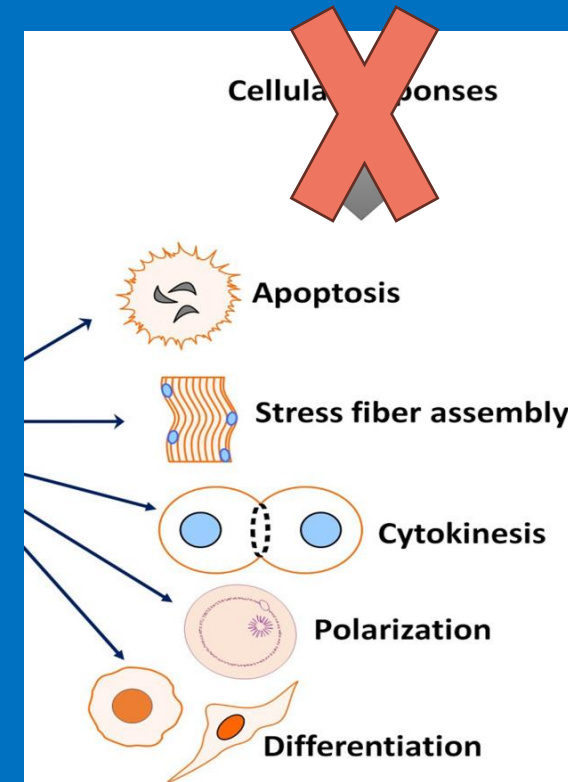
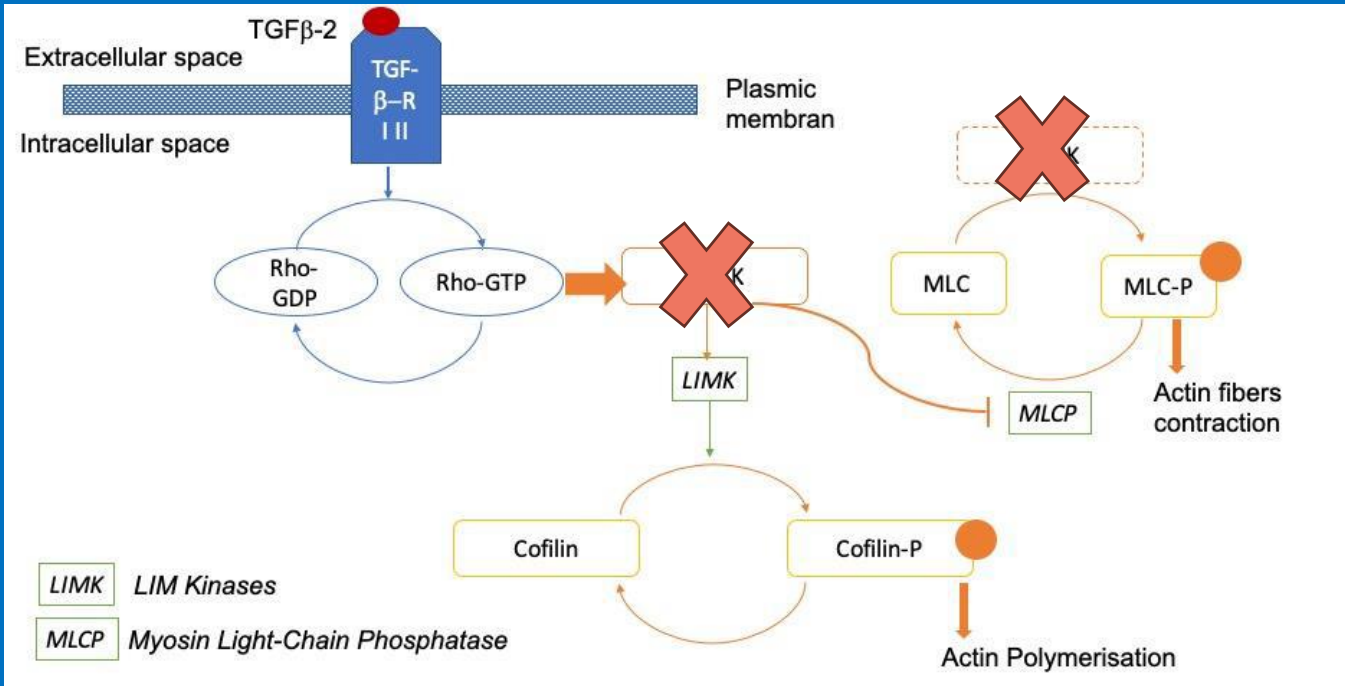
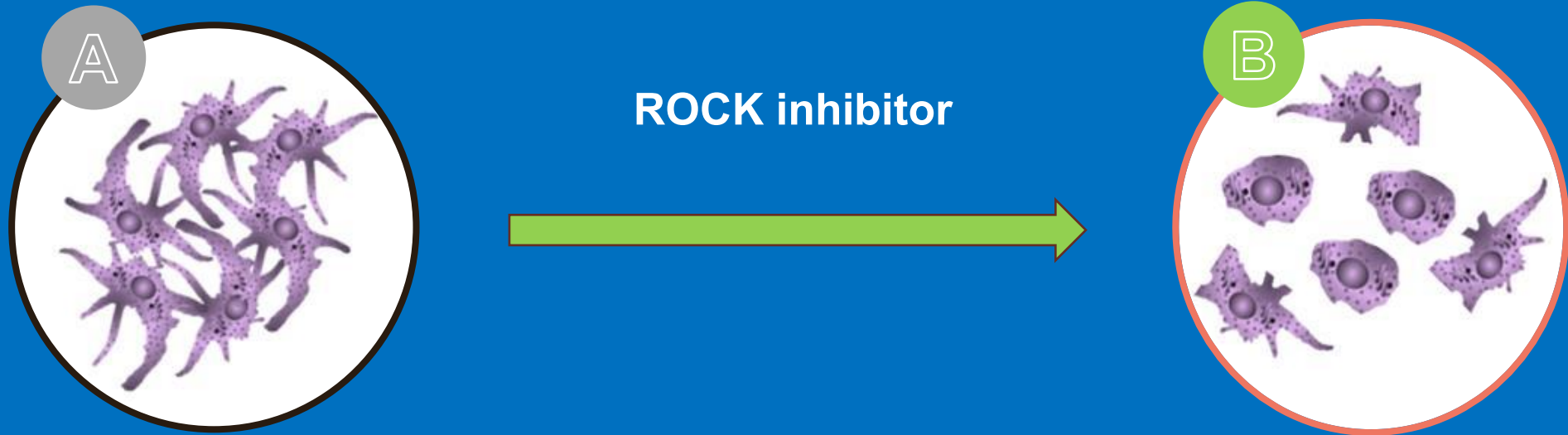


Bild vänster ur: Buffault, J.; Brignole-Baudouin, F.; Reboussin, É.; Kessal, K.; Labbé, A.; Mélik, Parsadaniantz, S.; Baudouin, C. The Dual Effect of Rho-Kinase Inhibition on Trabecular Meshwork Cells Cytoskeleton and Extracellular Matrix in an In Vitro Model of Glaucoma. *J. Clin. Med.* 2022, 11, 1001. License: Creative Commons Attribution (CC BY) license (<https://creativecommons.org/licenses/by/4.0/>)

Bild höger modifierat ur: Saadeldin IM, Tukur HA, Aljumaah RS and Sindi RA (2021) Rocking the Boat: The Decisive Roles of Rho Kinases During Oocyte, Blastocyst, and Stem Cell Development. *Front. Cell Dev. Biol.* 8:616762.

ROCK-inhibitor and the TM



Netarsudil

Randomized, double-masked multicenter study comparing netarsudil with timolol

- NET non-inferior to TIM over 3 months follow-up

Treatment related adverse events:

- Conjunctival hyperemia (NET 16% vs TIM 3.1%) mostly mild to moderate in both treatment arms
- Cornea verticillata (NET 24.5% vs TIM 0%)
- Eye pruritus (NET 7.8% vs BIM 0.9%)

Clinical Trial > Am J Ophthalmol. 2019 Aug;204:97-104. doi: 10.1016/j.ajo.2019.03.002.

Epub 2019 Mar 9.

Once-Daily Netarsudil Versus Twice-Daily Timolol in Patients With Elevated Intraocular Pressure: The Randomized Phase 3 ROCKET-4 Study

Albert S Khouri ¹, Janet B Serle ², Jason Bacharach ³, Dale W Usner ⁴, Richard A Lewis ⁵, Puiwah Braswell ⁶, Casey C Kopczynski ⁶, Theresa Heah ⁶; Rocket-4 Study Group



FC Netarsudil/latanoprost

Randomized, double-masked multicenter study comparing FC netarsudil/latanoprost with FC bimatoprost/timolol

Randomized Controlled Trial > Graefes Arch Clin Exp Ophthalmol. 2024 Jan;262(1):179-190.
doi: 10.1007/s00417-023-06192-0. Epub 2023 Aug 24.

MERCURY-3: a randomized comparison of netarsudil/latanoprost and bimatoprost/timolol in open-angle glaucoma and ocular hypertension

Ingeborg Stalmans^{1,2}, Kin Sheng Lim³, Francesco Oddone⁴, Marek Fichtl^{5,6}, Jose I Belda^{7,8}, Anton Hommer⁹, Guna Laganovska¹⁰, Cédric Schweitzer^{11,12}, Bogomil Voykov¹³, Tomasz Zarnowski¹⁴, Gábor Holló^{15,16}

- NET/LAT non-inferior to BIM/TIM over 3 months follow-up

Treatment related adverse events:

- Conjunctival hyperemia (NET/LAT 30.7% vs BIM/TIM 9%) mostly mild to moderate in both treatment arms
- Cornea verticillata (NET/LAT 11% vs BIM/TIM 0%)
- Eye pruritus (NET/LAT 7.8% vs BIM/TIM 0.9%)

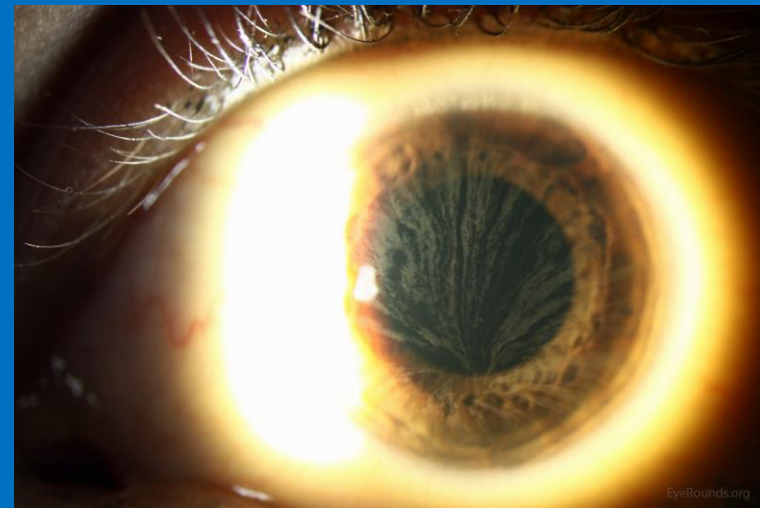
Netarsudil & FC Netarsudil/latanoprost

Pros:

- FC without timolol
- additional IOP lowering mechanism

Cons:

- higher rate of discontinuation with therapy due to side effects
- Cornea verticillata



Photography by Brice Critser. Ophthalmic Atlas Images by [EyeRounds.org](https://www.eyeforall.org/), [The University of Iowa](https://www.uniowa.edu/) are licensed under a [Creative Commons Attribution-NonCommercial-NoDerivs 3.0 Unported License](https://creativecommons.org/licenses/by-nc-nd/3.0/).

Glaucoma treatment options

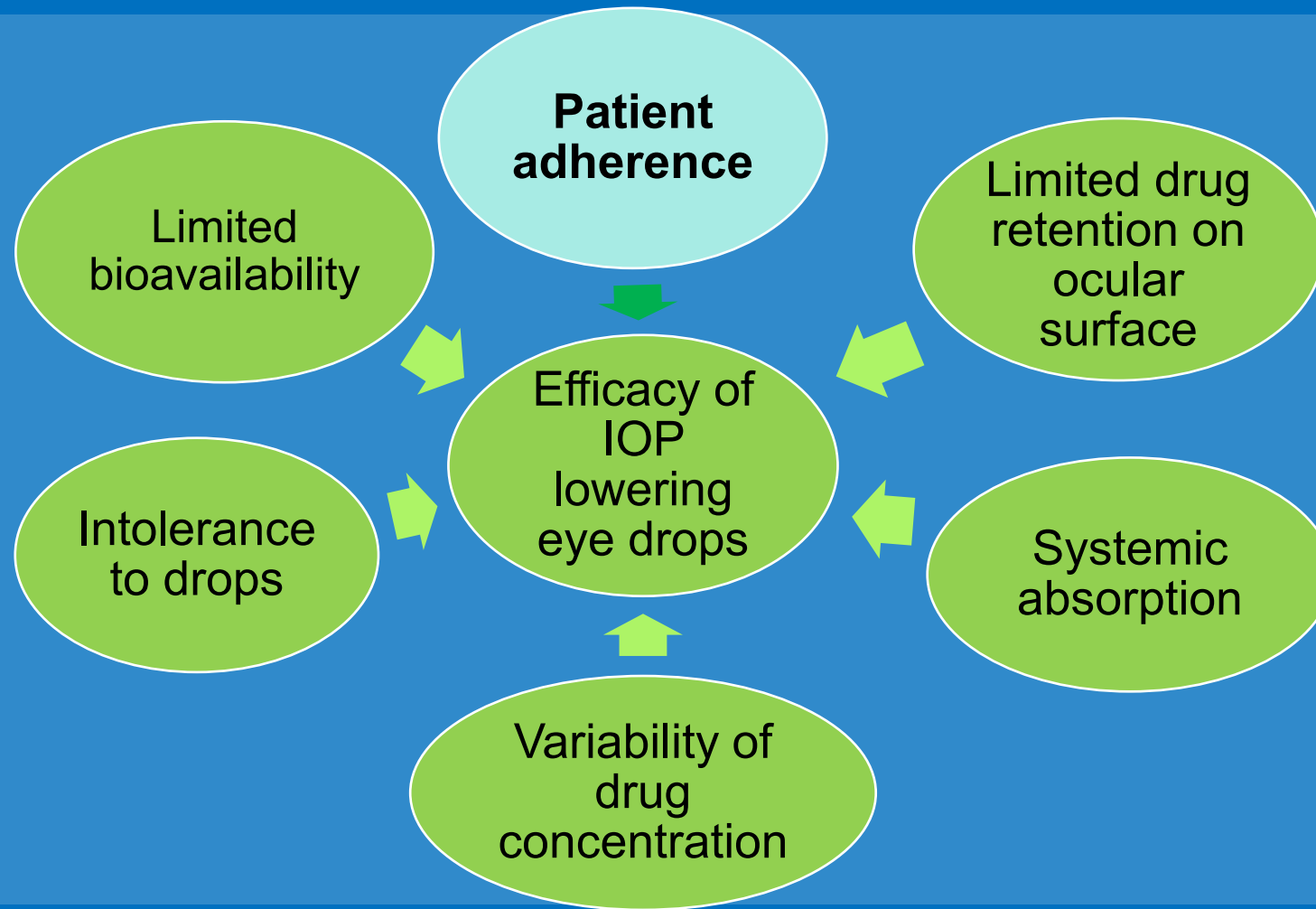
- IOP lowering

- Eye drops

- New drug – Rho-kinasinhibitor

- Sustained release drug delivery systems

Sustained release drug delivery systems – Why?



Sustained release drug delivery systems

- non-degradable devices
- degradable devices

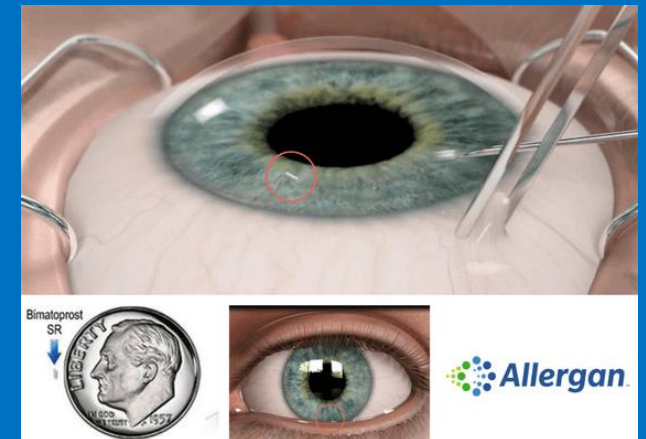Degradable device –

Durysta™ – Bimatoprost SR (AbbVie Inc. North Chicago, Illinois, U.S.A.)

Design: intracameral pellet implant within a biodegradable NOVADUR solid copolymer PLGA matrix platform

- Administered into the anterior chamber with an injector

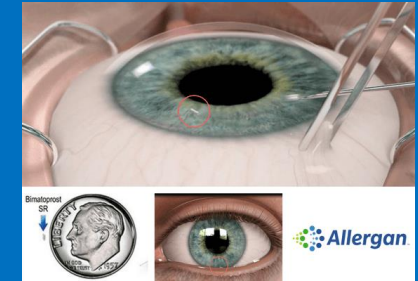Targeted duration: 6 months*



* FDA: 30% IOP reduction over 12- weeks + non-inferior to Timolol

Degradable device –

Durysta™ – Bimatoprost SR (AbbVie Inc. North Chicago, Illinois, U.S.A.)



Pros

- IOP lowering effect over months
- biodegradable
- low levels in off-target extraocular tissue (-> lower risk for orbital fat atrophy)

Cons

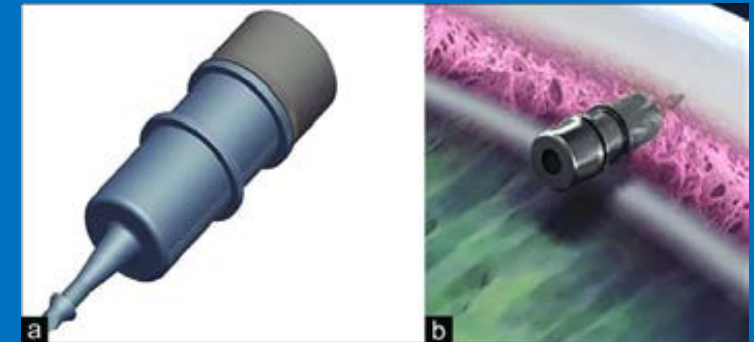
- Invasive
- Risk for endophthalmitis
- Risk of migration
- Conjunctival hyperaemia
- Risk of corneal endothelial cell loss
- Approved for single usage in each patient

Non-degradable device – iDose[®] TR Travoprost intracameral implant (Glaukos, San Clemente, CA, USA)

Design: Titanium implant filled with a travoprost solution covered with a membran

- Intracameral delivery system
- Placed through a small corneal incision
- Anchored to the trabecular meshwork

Targeted duration: 6-12 months*




* FDA: non-inferior to Timolol over first 3 months! 81% without eye drops after 12 months.

Non-degradable device –

iDose[®] TR Travoprost intracameral implant

(Glaukos, San Clemente, CA, USA)



Pros

- IOP lowering effect over months
- no clinically significant corneal endothelial cell loss (36-month Phase 2 data)
- No hyperemia

Cons

- Invasive
- Side effects
 - increased pigmentation of the iris / iritis
 - dry eye
 - increase in IOP
- Risk for endophthalmitis
- Risk of migration/ device dislocation
- Non-degradable – must be surgically removed when depleted



Glaucoma treatment options

- **IOP lowering**
 - Eye drops
 - Laser
 - Surgery

- **Neuroprotection**
 - Citicoline
 - Nicotinamide

Neuroprotection

- Citicoline
- Nicotinamide



Citicoline

Randomized Controlled Trial > J Glaucoma. 2020 Jul;29(7):513-520.

doi: 10.1097/IJG.0000000000001565.

Can Treatment With Citicoline Eyedrops Reduce Progression in Glaucoma? The Results of a Randomized Placebo-controlled Clinical Trial

Luca Rossetti ¹, Michele Iester ^{2 3}, Laura Tranchina ¹, Laura Ottobelli ¹, Giulia Coco ⁴, Elisabetta Calcatelli ⁴, Chiara Ancona ^{2 3}, Paola Cirafici ^{2 3}, Gianluca Manni ^{4 5}

Randomized double-masked placebo-controlled trial

- Citicoline eye drops
- follow-up: 3 years
- indication of less visual field progression when treated with Citicoline

Randomized Controlled Trial

> Graefes Arch Clin Exp Ophthalmol. 2023 Jun;261(6):1659-1668.

doi: 10.1007/s00417-022-05947-5. Epub 2023 Jan 14.

The effect of citicoline oral solution on quality of life in patients with glaucoma: the results of an international, multicenter, randomized, placebo-controlled cross-over trial

Luca Rossetti ¹, Francisco Goni ², Giovanni Montesano ³, Ingeborg Stalmans ⁴, Fotis Topouzis ⁵, Dario Romano ⁶, Eleonora Galantin ⁶, Noemi Delgado-Gonzales ², Sara Giammaria ⁷, Giulia Coco ⁸, Evelien Vandewalle ⁴, Sophie Lemmens ⁴, Dimitrios Giannoulis ⁵, Theofanis Pappas ⁵, Gianluca Manni ⁸

Randomized double-masked placebo-controlled cross-over study

- Citicoline oral solution
- follow-up: 9 months
- slight indication of improved Quality of life when treated with Citicoline

Citicoline

BUT...

> PLoS One. 2023 Sep 28;18(9):e0291836. doi: 10.1371/journal.pone.0291836. eCollection 2023.

Efficacy of citicoline as a supplement in glaucoma patients: A systematic review

Julia Prinz ^{1 2}, Verena Prokosch ², Hanhan Liu ², Peter Walter ¹, Matthias Fuest ¹,
Filippo Migliorini ^{3 4}

Systematic review

- 5 RCT + 5 retrospective studies
- differences in follow-up, IOP-lowering treatment, citicoline therapy regim

Conclusion:

Lack of evidence that citicoline had any significant impact on:

- IOP reduction
- Visual field preservation
- Retinal function
- RGC preservation



Nicotinamide (NAM)

> Invest Ophthalmol Vis Sci. 2019 Jun 3;60(7):2509-2514. doi: 10.1167/iovs.19-27099.

Nicotinamide Deficiency in Primary Open-Angle Glaucoma

Judith Kouassi Nzoughet ¹, Juan Manuel Chao de la Barca ^{1 2}, Khadidja Guehlouz ³, Stéphanie Leruez ³, Laurent Coulbault ⁴, Stéphane Allouche ⁴, Cinzia Bocca ¹, Jeanne Muller ³, Patrizia Amati-Bonneau ^{1 2}, Philippe Gohier ³, Dominique Bonneau ^{1 2}, Gilles Simard ², Dan Milea ⁵, Guy Lenaers ¹, Vincent Procaccio ^{1 2}, Pascal Reynier ^{1 2}

Cohort study

- 34 POAG and 30 control patients
- lower plasmatic NAM levels in POAG compared to controls

Randomized Controlled Trial > Clin Exp Ophthalmol. 2020 Sep;48(7):903-914.

doi: 10.1111/ceo.13818. Epub 2020 Jul 28.

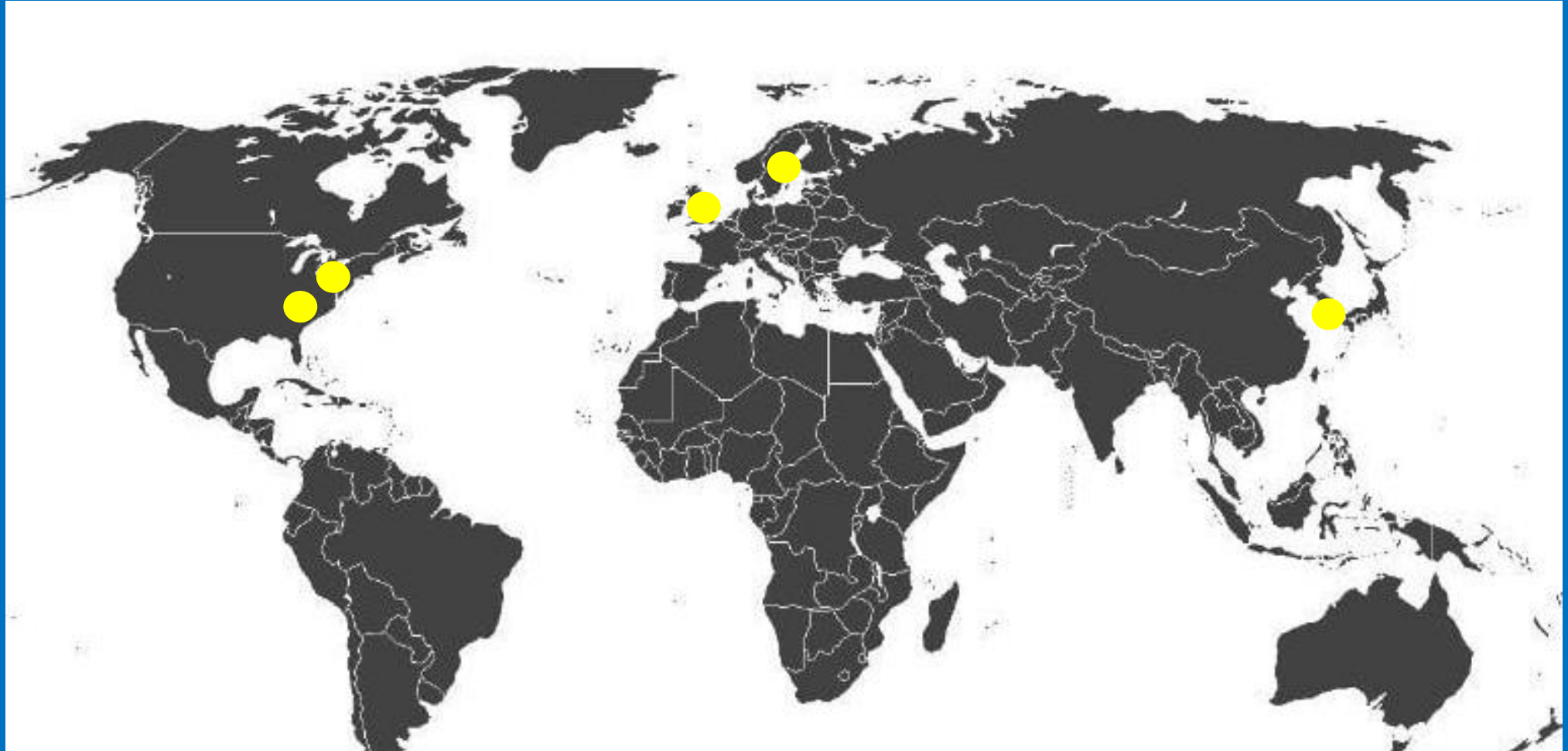
Improvement in inner retinal function in glaucoma with nicotinamide (vitamin B3) supplementation: A crossover randomized clinical trial

Flora Hui ¹, Jessica Tang ^{1 2}, Pete A Williams ³, Myra B McGuinness ¹, Xavier Hadoux ¹, Robert J Casson ⁴, Michael Coote ^{1 2}, Ian A Trounce ^{1 2}, Keith R Martin ^{1 2 5}, Peter van Wijngaarden ^{1 2}, Jonathan G Crowston ^{1 2 6 7}

Cross-over double-masked randomized clinical trial:

- follow up: 3 months
- NAM additional to IOP-lowering treatment
- Improvement in RGC function (ERG)

Nicotinamide (NAM) – Ongoing research



Picture from skolbilder.com

Take home messages

- very few new IOP lowering eye drugs during the last 25 years
- sustained release drug delivery systems
 - non-degradable devices
 - travoprost filled TM implant
 - degradable devices
 - intracameral pellet implant (Bimatoprost)
- Neuroprotection – a possible new/ additional treatment for glaucoma



THANK YOU!



LUND
UNIVERSITY

 **Skåne University Hospital**

Keratitis vs keratoconjunctivitis

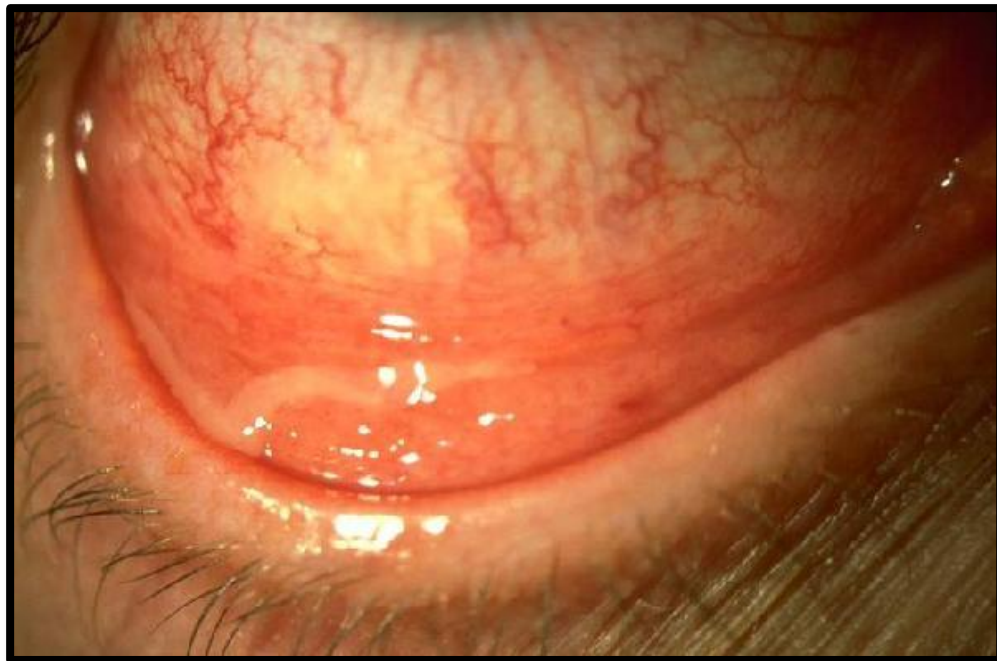Nordic congress Ophthalmic Nurses 2024

Emma Nivenius MD PhD S:t Eriks Eye Hospital

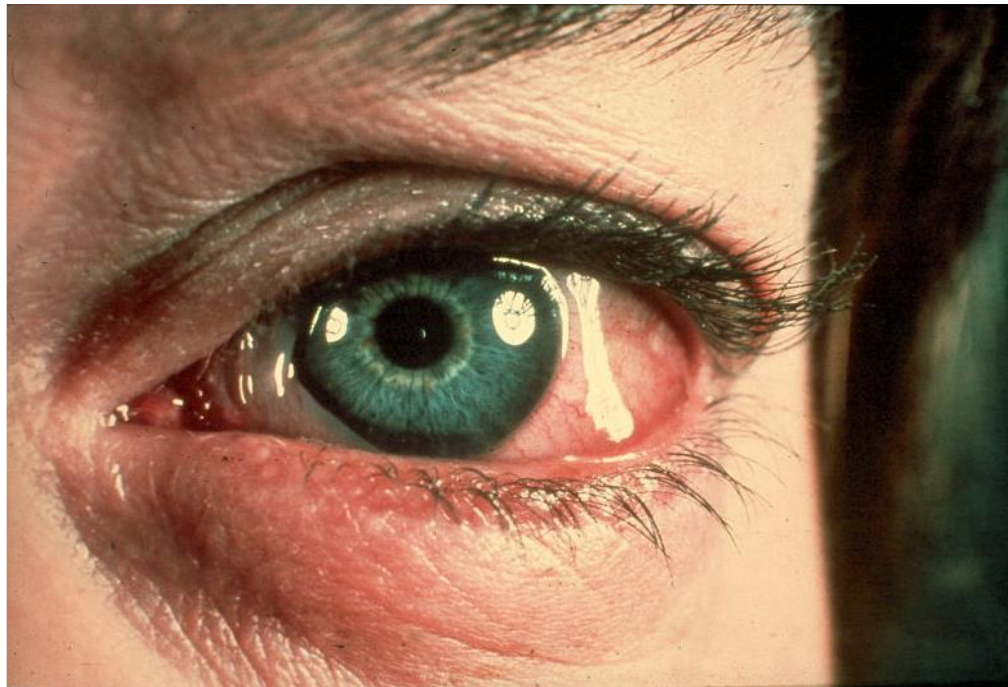Ocular surface "itis"

- Conjunctivitis
- Keratitis
- Keratoconjunctivits

Infectious conjunctivitis



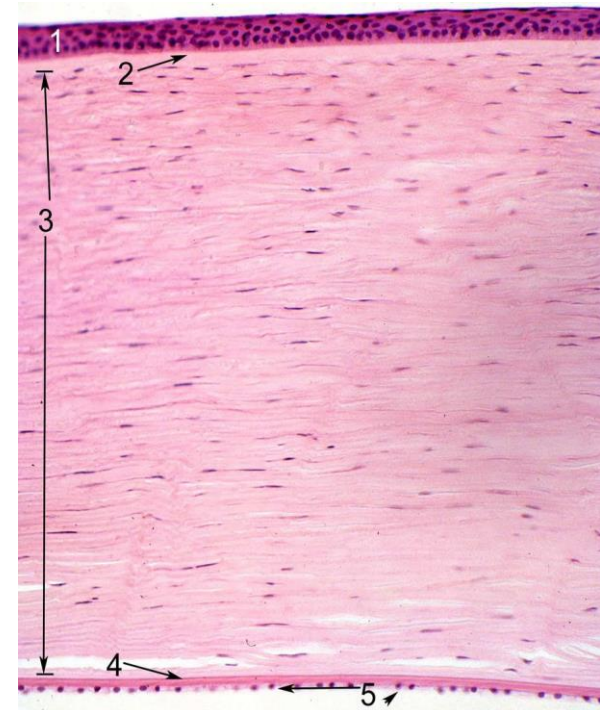
Allergic conjunctivitis



Corneal layers

- 1 Epithelium 0,05mm
- 2 Bowman´s layer
- 3 Stroma 0,5 mm
- 4 Descemet´s membran
- 5 Endothelium

The part of the body with most nerves



Symptoms keratit and keratoconjunctivitis

Varying degree of:

- Discomfort, foreign body sensation, pain
- Light sensitivity
- Conjunctival injection
- Discharge
- Blurry vision/visual impairment
- Keratoconjunctivitis often both eyes, keratitis often unilateral

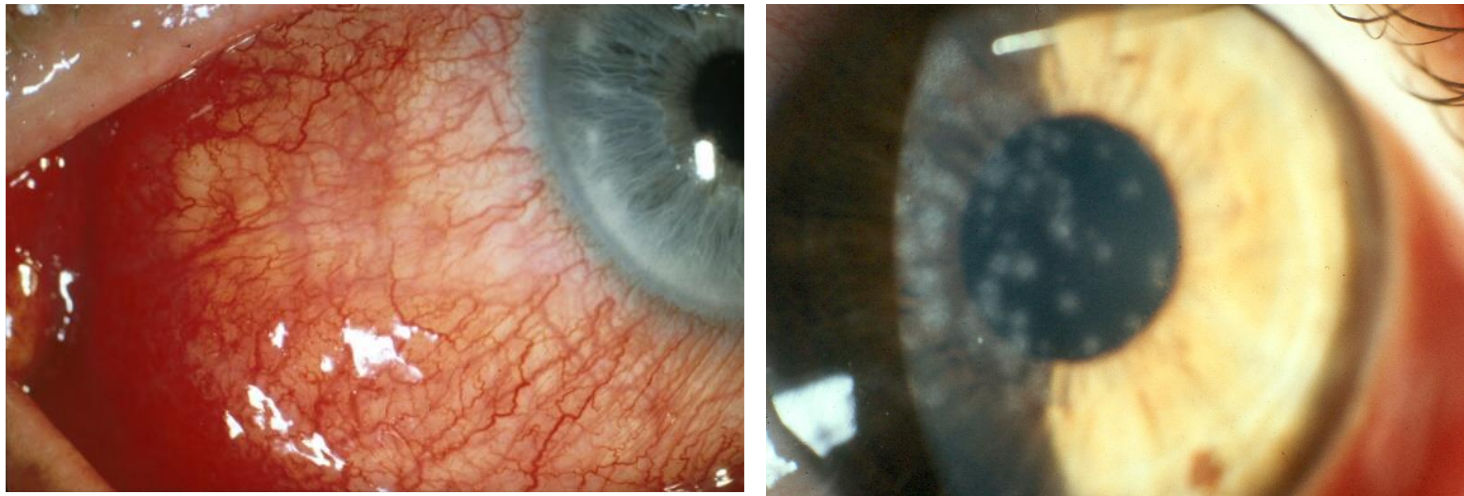
Keratoconjunctivitis

- Can be non-infectious
 - Allergic; vernal keratoconjunctivitis and atopic keratoconjunctivitis
 - Dry eyes- keratokonjunctivitis sicca
 - Exposure/neurotropic keratokonjunctivitis (often unilateral)
- Can be infectious
 - Adenovirus most common
 - Chlamydia (almost always unilateral)
- Superficial keratitis
- Can be acute or chronic

Adenoviral keratoconjunktivitis

- Epidemic keratoconjunktivitis "Pink eyes"
- Common cause of keratoconjunktivitis
- Often first one and after 2-3 days the other eye
- Sometimes very swollen eyelids
- Watery discharge
- **CONTAGIOUS!**
- No targeted treatment
- Normally 2 weeks for recovery
- Hygiene and moisturing drops

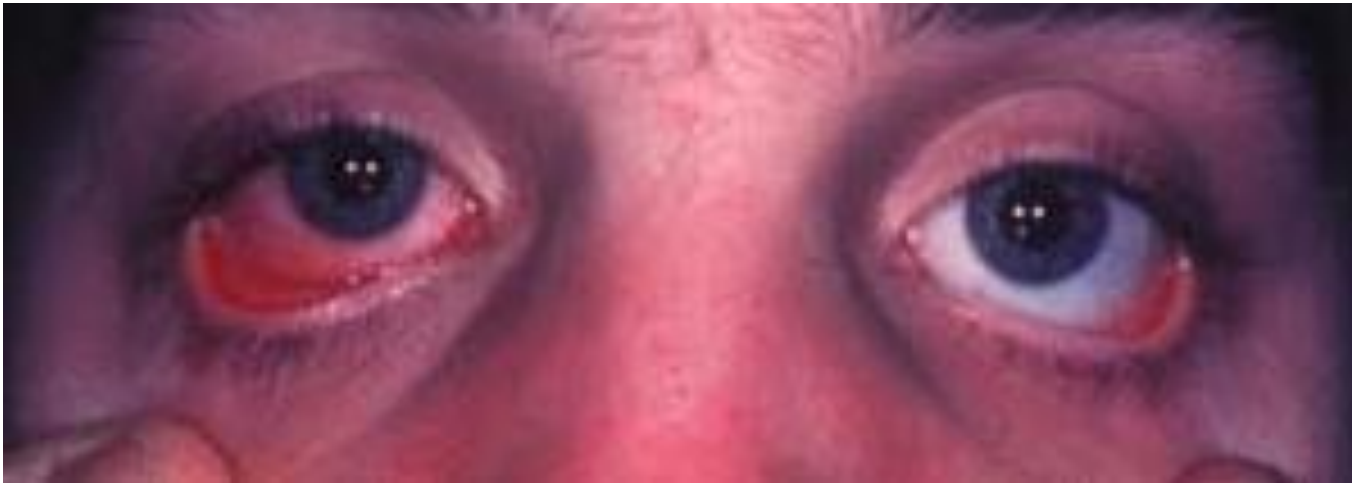Adenoviral keratoconjunctivitis



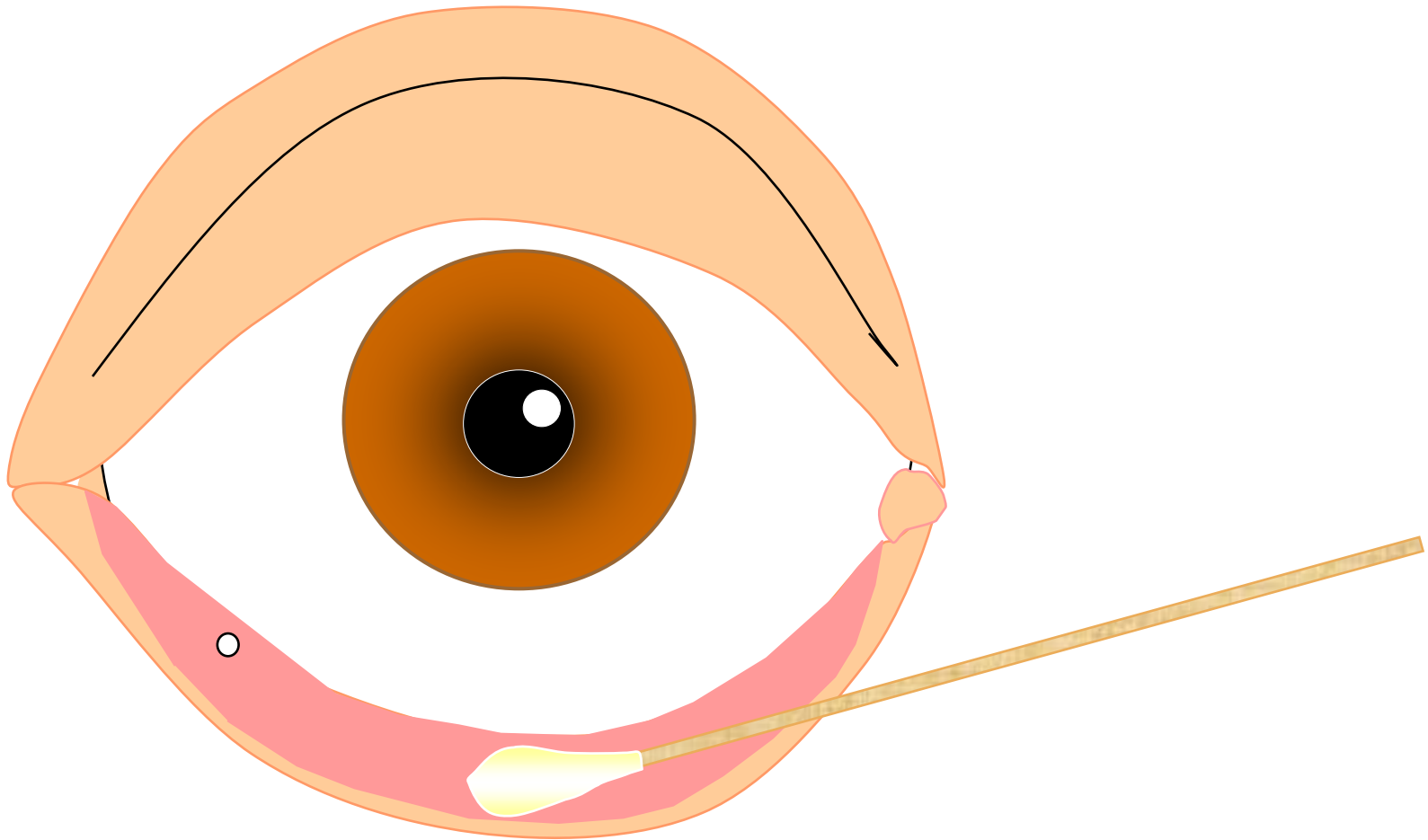
- Rapid tests – low specificity
- PCR-test if atypical
- If severe subepithelial infiltrates; cyclosporine drops or tacrolimus drops/ointment

Clamydia keratoconjunctivits

- Young adults
- Sexually transmitted
- Unilateral
- Often 2-3 weeks of symptomes
- PCR-test



Conjunctival swab for culture



Keratitis

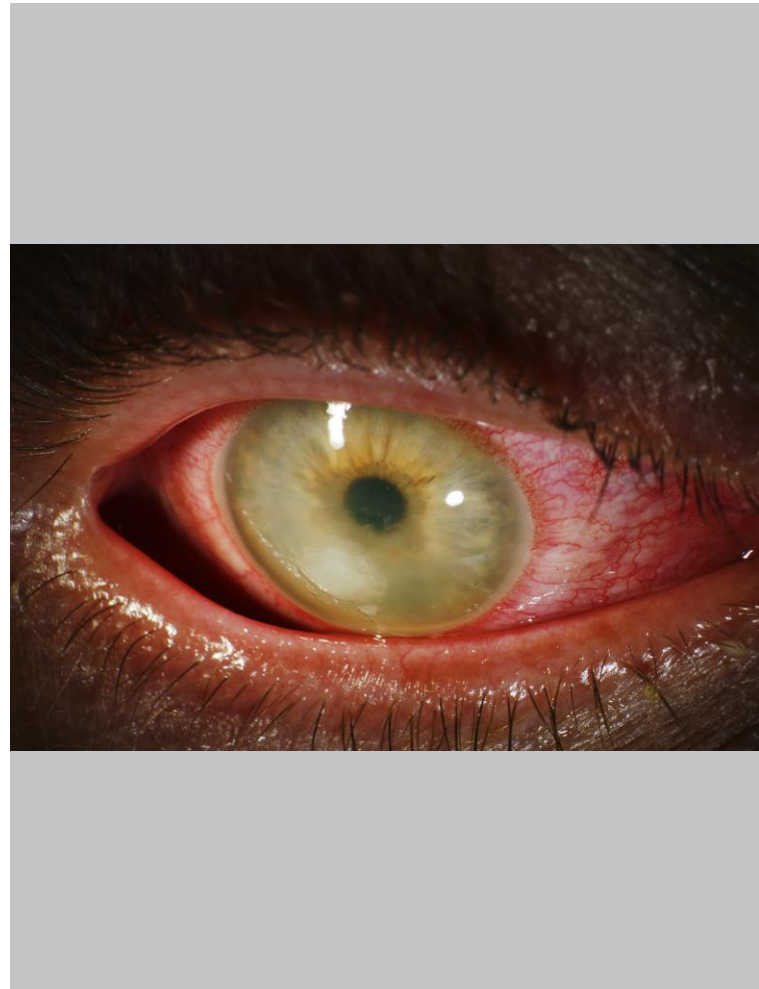
- Infectious or not?
 - What part of the world
 - Patient history
 - Patient risk factors
 - Rheumatic disease?
 - Scin disease?
 - Ocular risk factor
 - Presentation of the keratitis
 - Cultures/PCR/confocal microscope



Keratitis

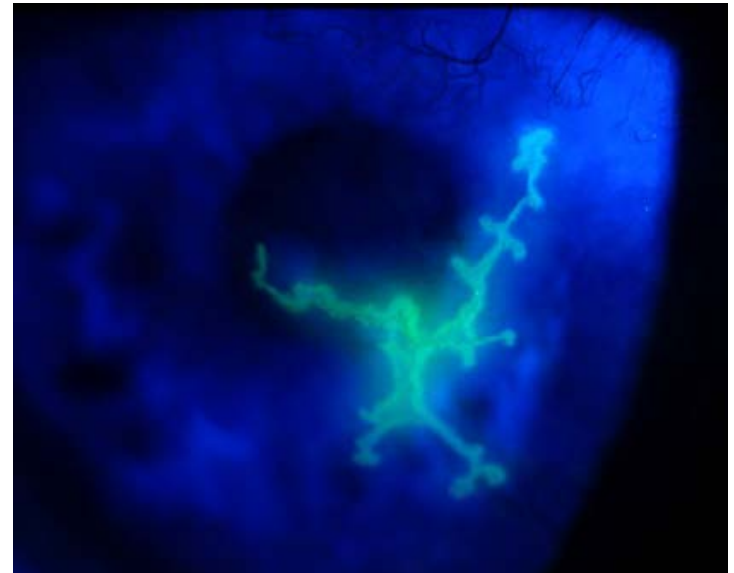
- Bacterial 40-50%
- Viral 30-40%
- Fungal 1%
- Protozal <1%
- (sterile 10-25%)

Ibrahim et al. **Incidence of Infectious Corneal Ulcers, Portsmouth Study, UK** J Clin Experiment Ophthalmol 2012

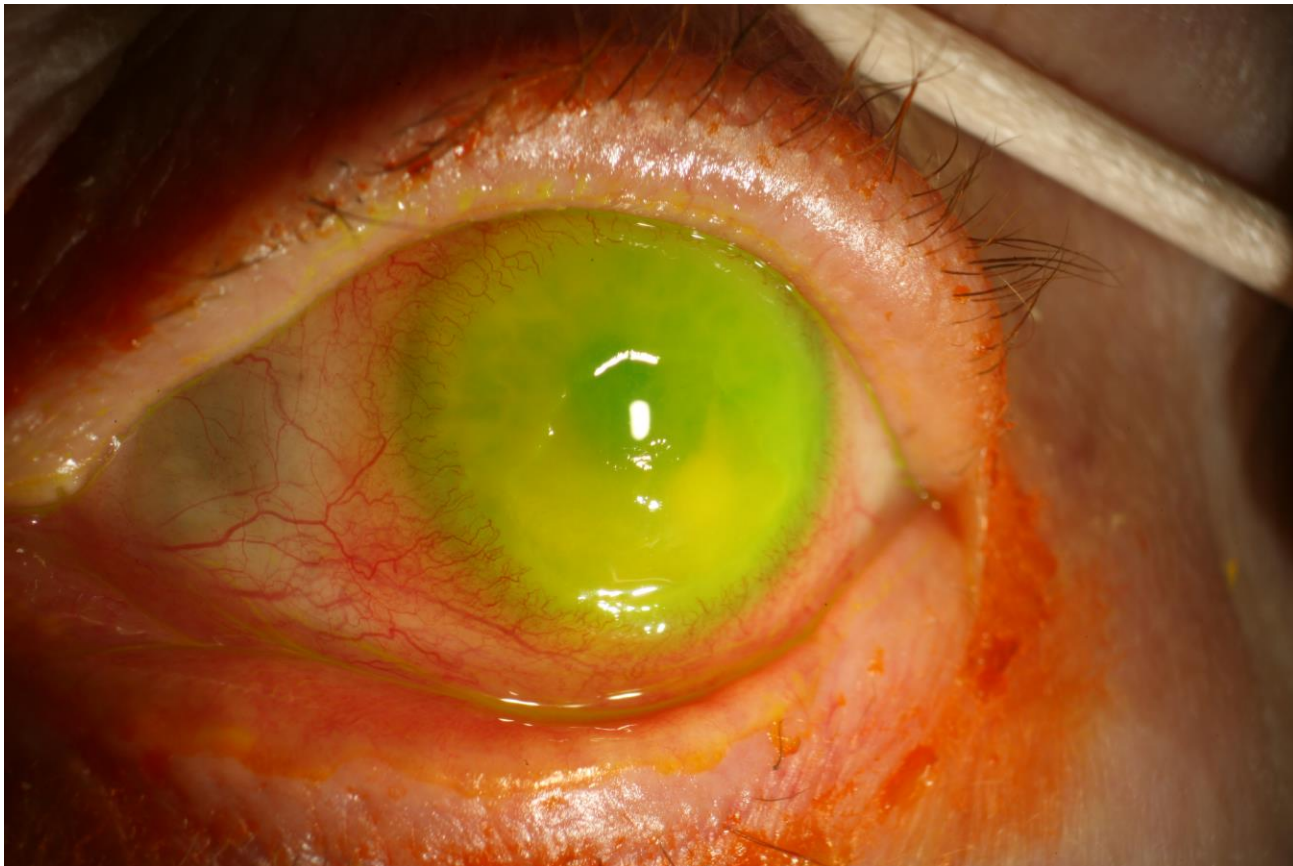


Viral keratits

- Virus
 - Adenovirus
 - Herpes simplex virus
 - Varicella virus (herpes zoster)
- Risk factors
 - Known disease
 - Immunosuppression
 - Atopic dermatitis
- Tests
 - PCR



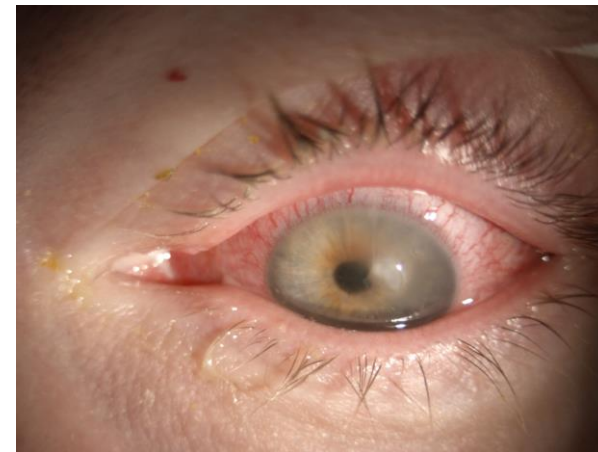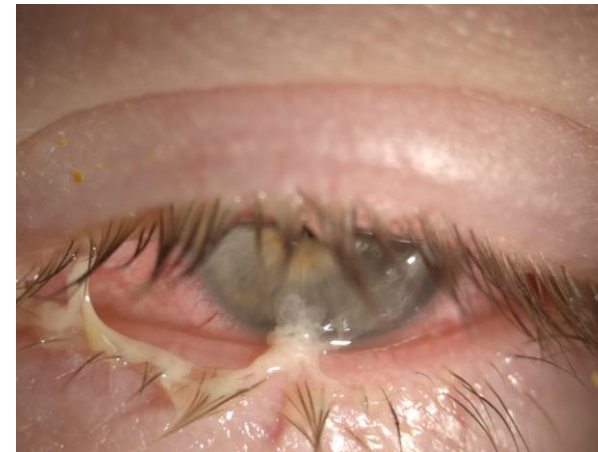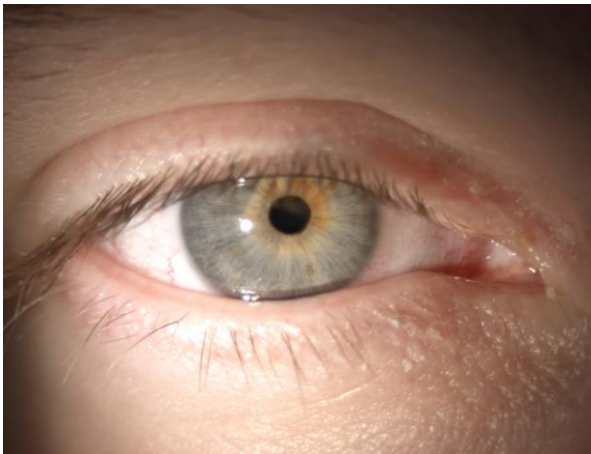Corneal sensibility



Microbial keratitis –risk factors

- Epithelial defect
 - Contact lenses
 - Dry eyes
 - Lagophthalmus
 - Decreased sensibility
 - Trauma
 - Corneal surgery
- Generall risk factors
 - Immunosuppression, drug abuse, age

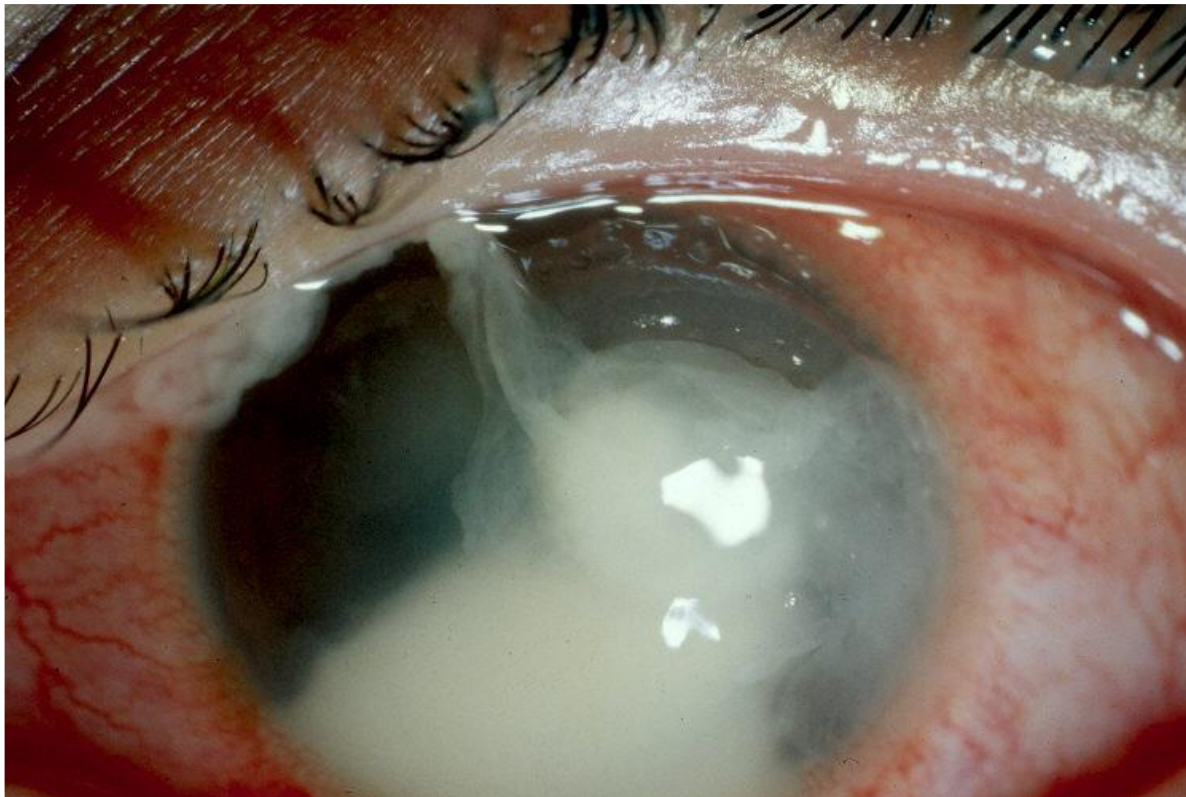
40-year old man, pain since 1 day



Right eye no problems
Left eye, light sensitive, pain,
discharge and white spot on
cornea

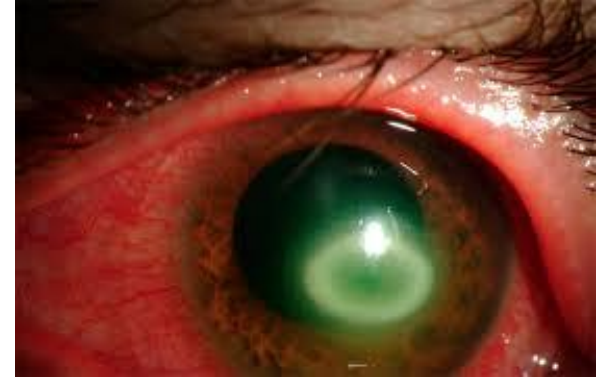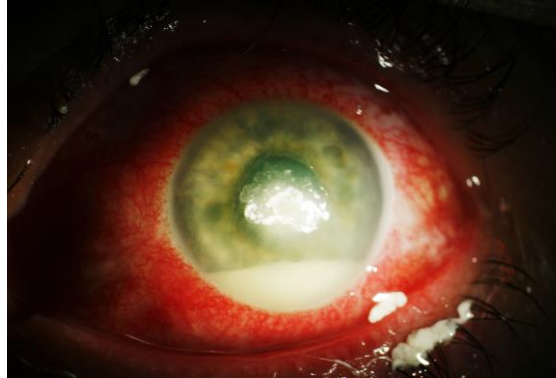
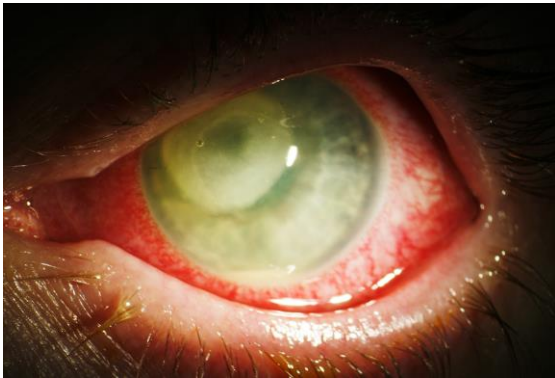
23-year old woman, 3 days pain

-This is the reason for the need of quick management i keratitis!

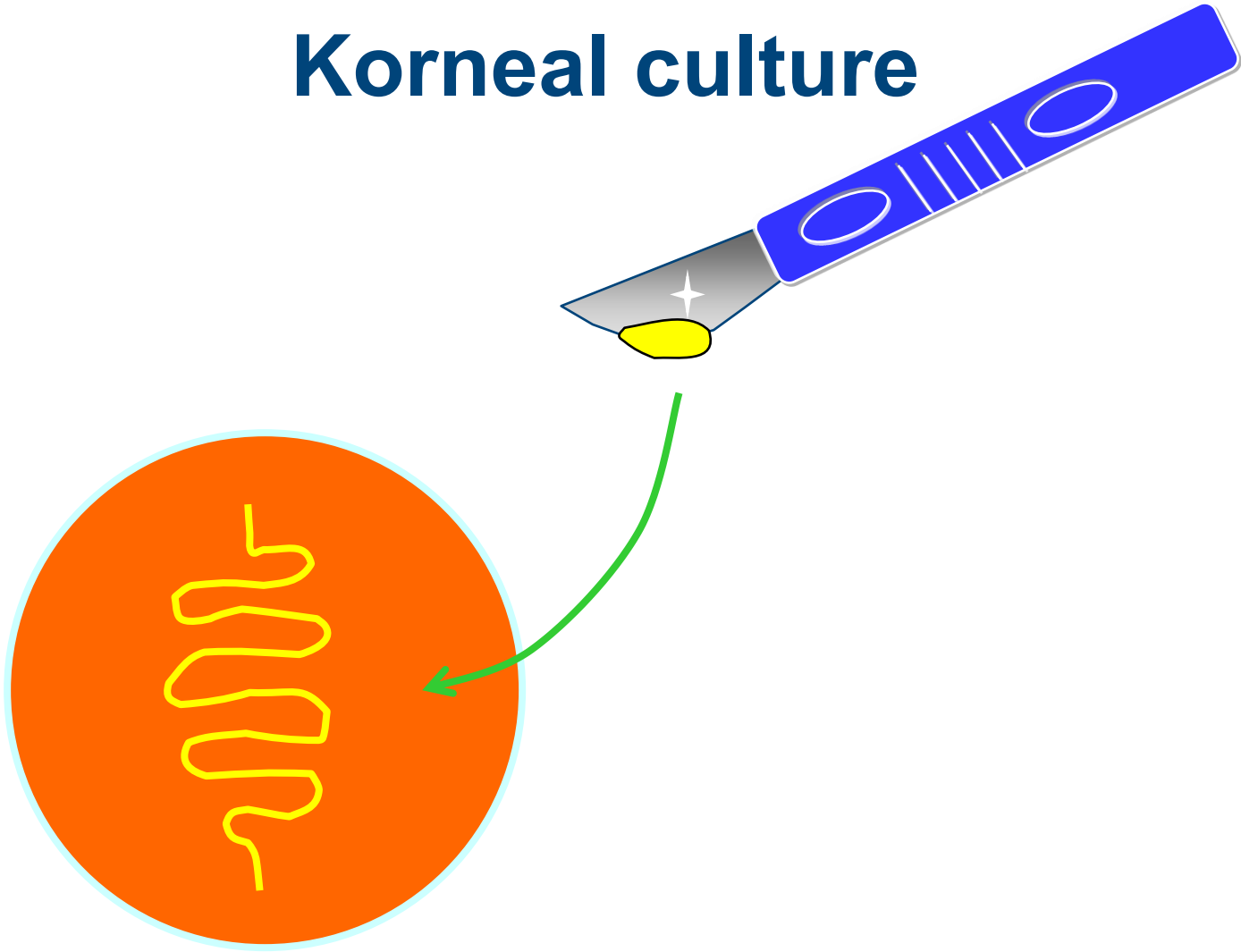


Keratitis left eye

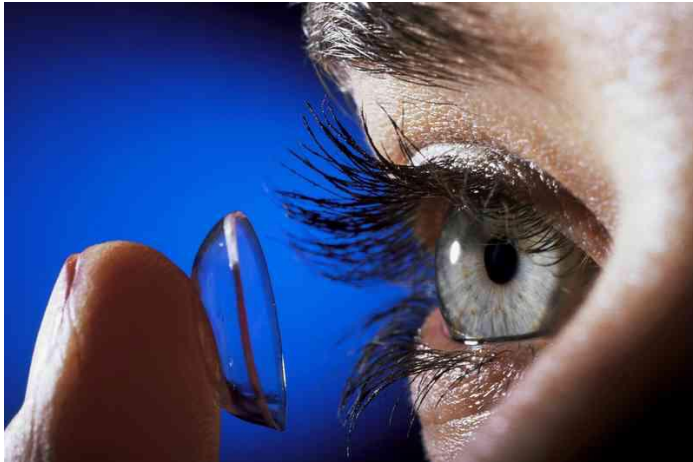Patient history and cultures/PCR necessary for diagnosis



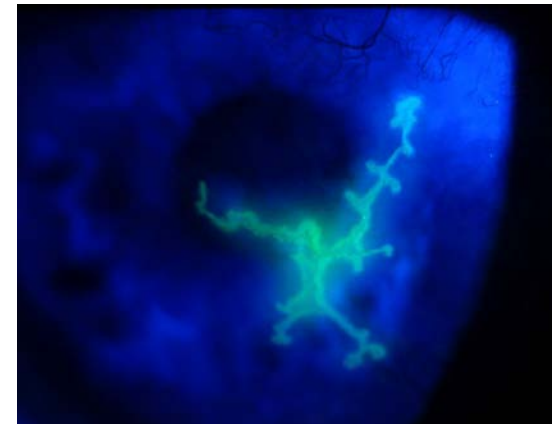
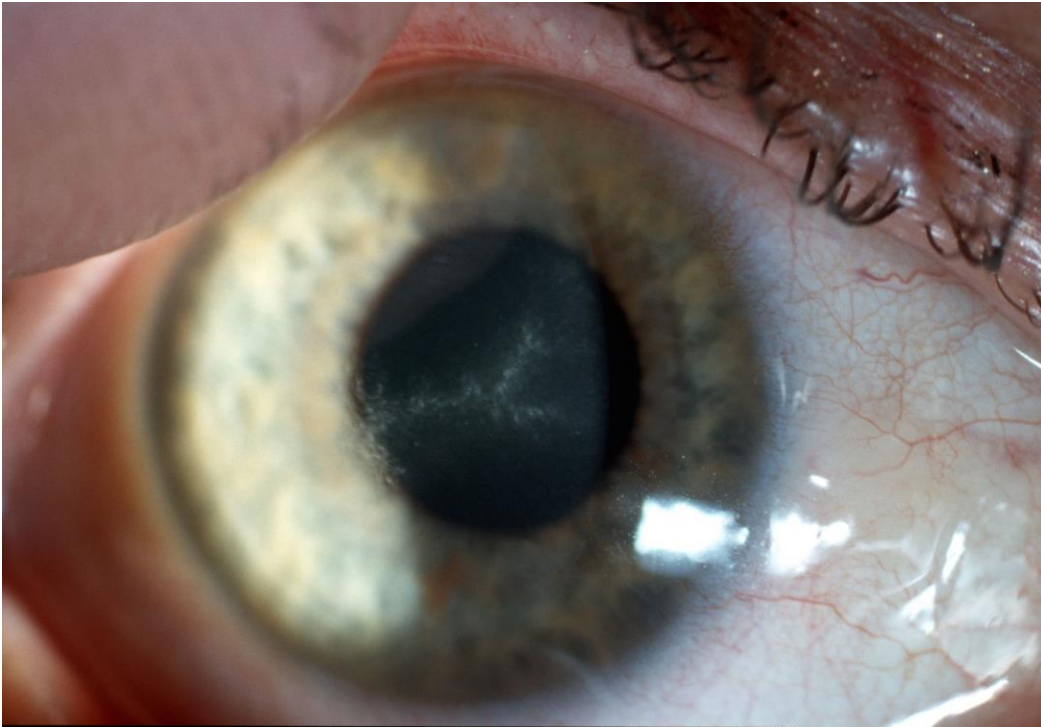Korneal culture



Acanthamoeba keratitis



Acanthamoeba keratitis versus HSV



Management in suspected microbial keratitis

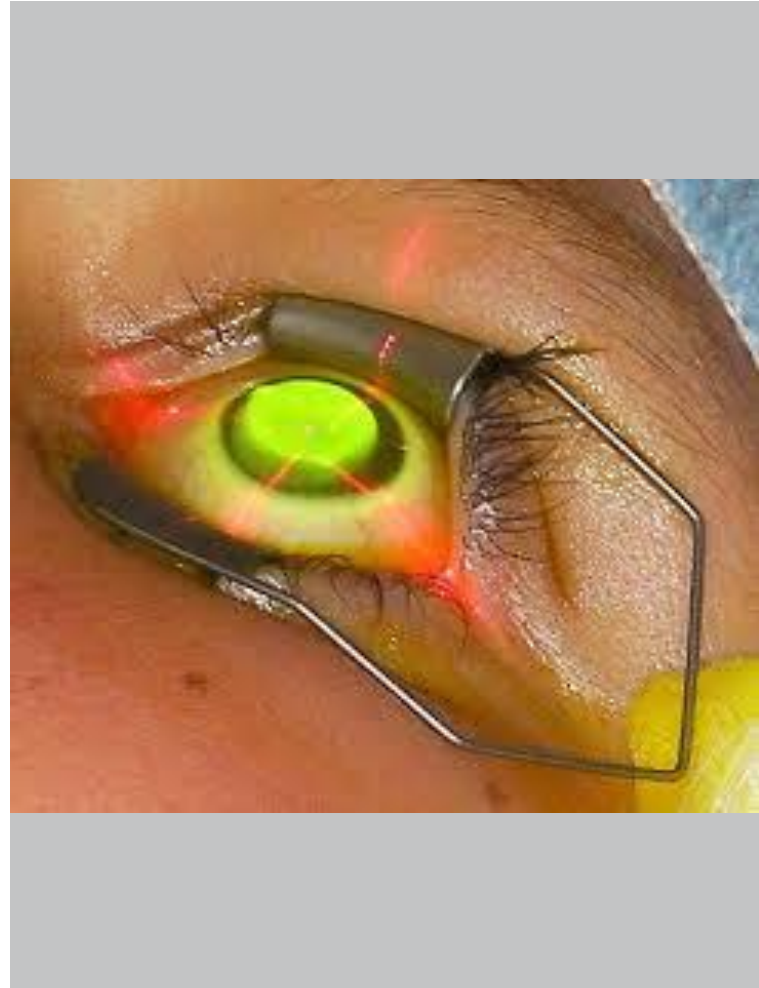
- Identify the enemy
 - Corneal scrapings for culture
 - If suspected fungi take double plates for culture
 - PCR
 - If suspected acanthamoeba special culture/ PCR/ confocal microscopy

Management in suspected microbial keratit

- Kill the enemy!
 - Always initiate empirical treatment
 - Broad spectrum antibiotics covering both gram negative and gram positive bacteria.
 - At St Eriks Ögonsjukhus
 - Fluoroquinolon and Cloramfenikol drops
 - Intense treatment 2-3 days, adjusted therapy after culture results
 - Targeted treatment for fungai or acanthamoeba


PACK-CXL

- Photoactivated chromophore for infectious keratitis
- Several case reports
- Herpes contraindicated
- No consensus yet
 - Which cases will benefit
 - Which microbes are susceptible
 - Which settings are the best
 - Which chromophore is the best



To summarize

- Patient history, symptoms and duration of symptoms will guide
- **Conjunctivitis**
 - Selflimiting, infections seldom need for treatment
- **Keratokonjunctivitis**
 - Acute – often viral
 - Semi-acute think of chlamydia - PCR
 - Chronic - often keratoconjunctivitis sicca
- **Keratitis – sight threatening**
 - Inflammatory in systemic disease
 - Infectious keratitis, almost always unilateral
 - Try to identify the microorganism
 - Start empiric treatment!



Gene Therapy in Retinal Diseases

Hammurabi Bartuma
MD, PhD, FEBO

Financial disclosure

A hand in a white glove uses tweezers to hold a red and white molecular model against a blue and white molecular model. The background is dark with a grid pattern.

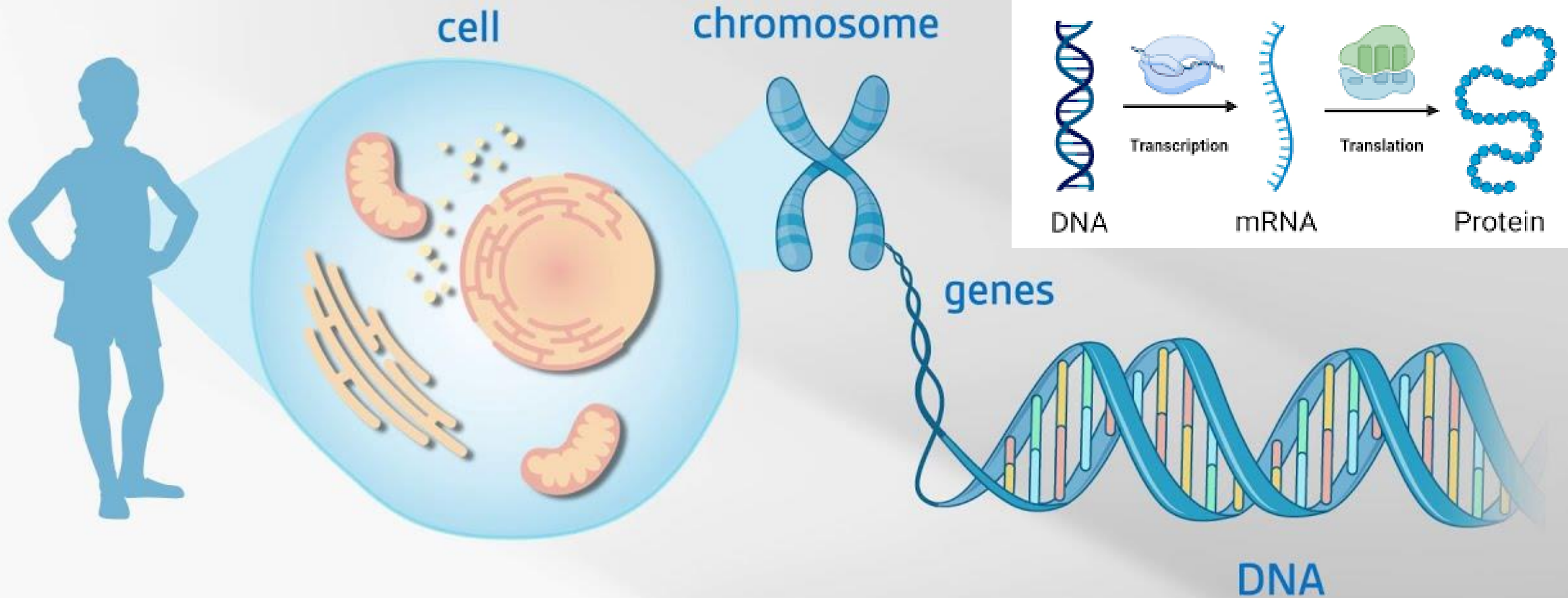
- No conflict of interest

Overview




- Genetic
- Gene therapy
- Different vectors
- Benefit of the eye
- Ongoing gene therapy trials in Ophthalmology
- Summary

Genetic

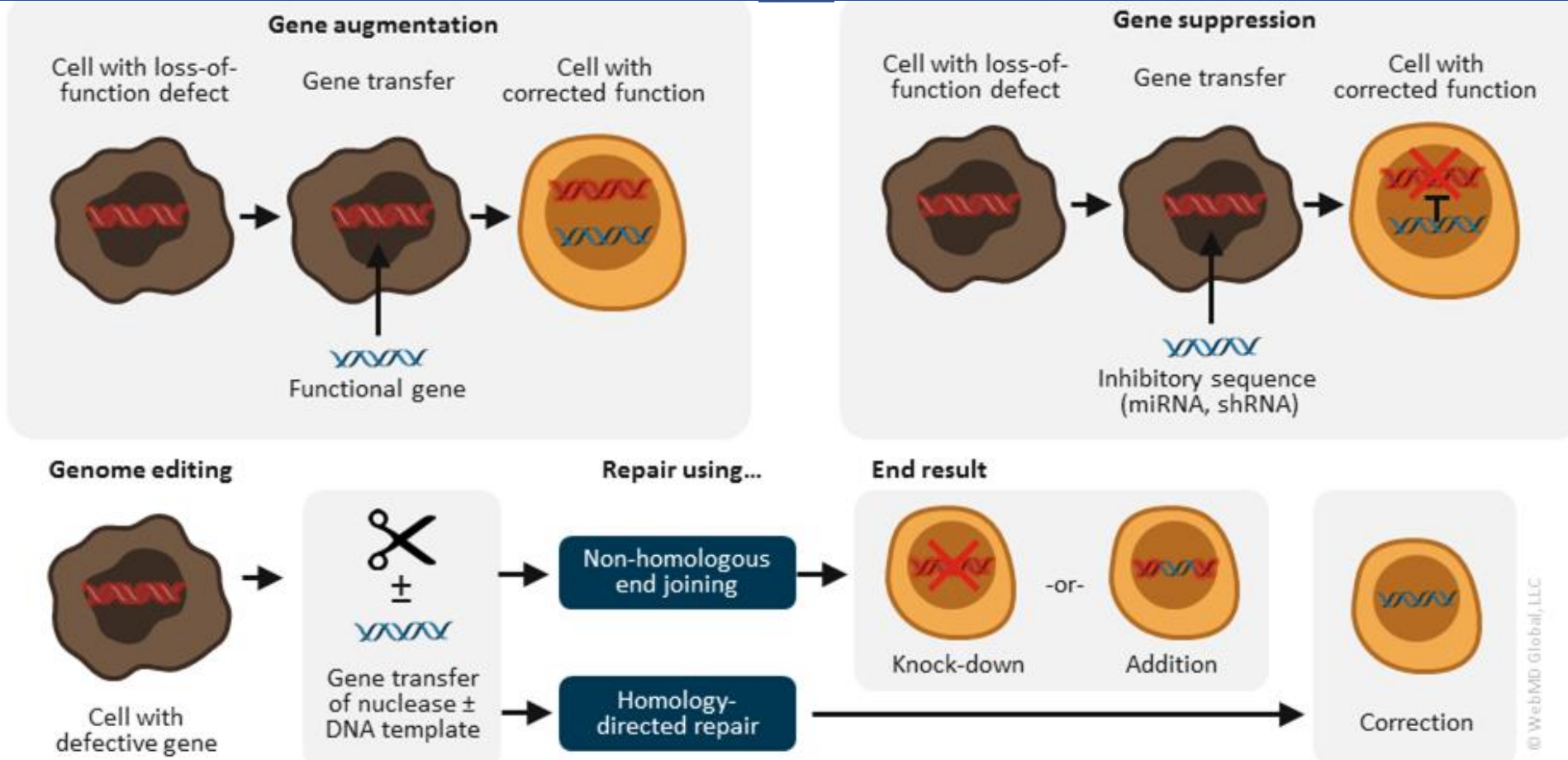


Gene therapy

- Treatment with genetic material – DNA/RNA
- Mutated/Non-functional gene -> functional gene
- Reduce the production of disease-causing protein
- Help cells produce proteins that help the immune system fight disease
- Possibility of curing chronic diseases
- Primarily focused on monogenetic diseases
- Development in the area is progressing rapidly



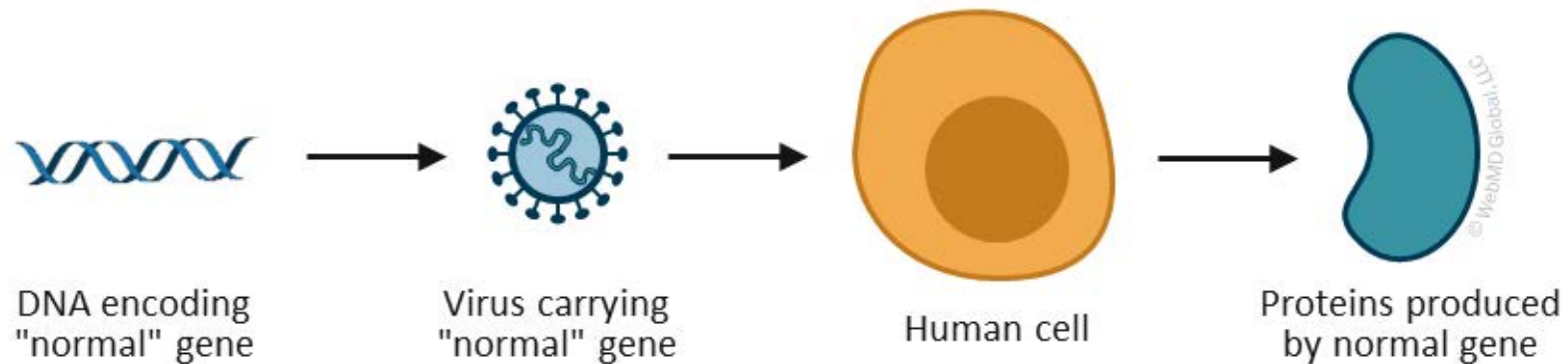
The evolving role of gene therapy



The goal of gene therapy is to restore normal cellular function

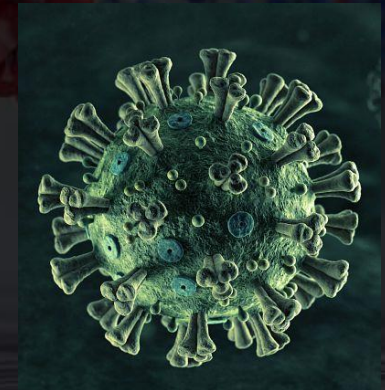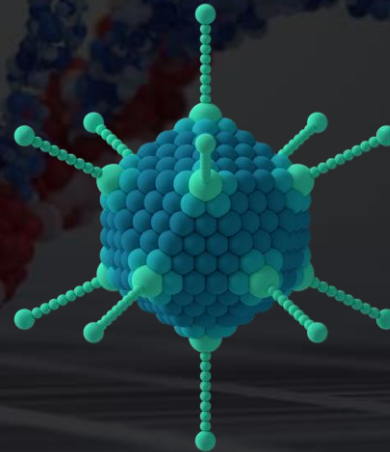
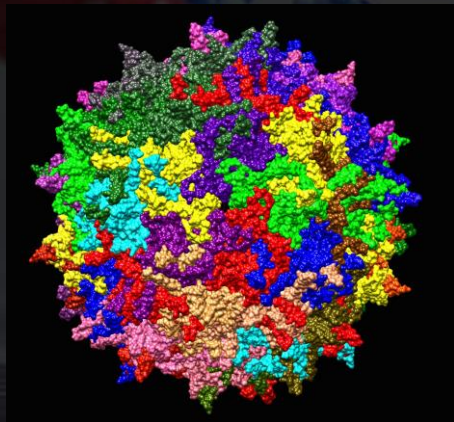
Vectors in gene therapy

- Gene therapy involves use of a vector to carry the gene of interest into the host cell
- Vectors:
 - DNA
 - Nanoparticles
 - Virus
- Viruses are the most used in clinical gene therapy



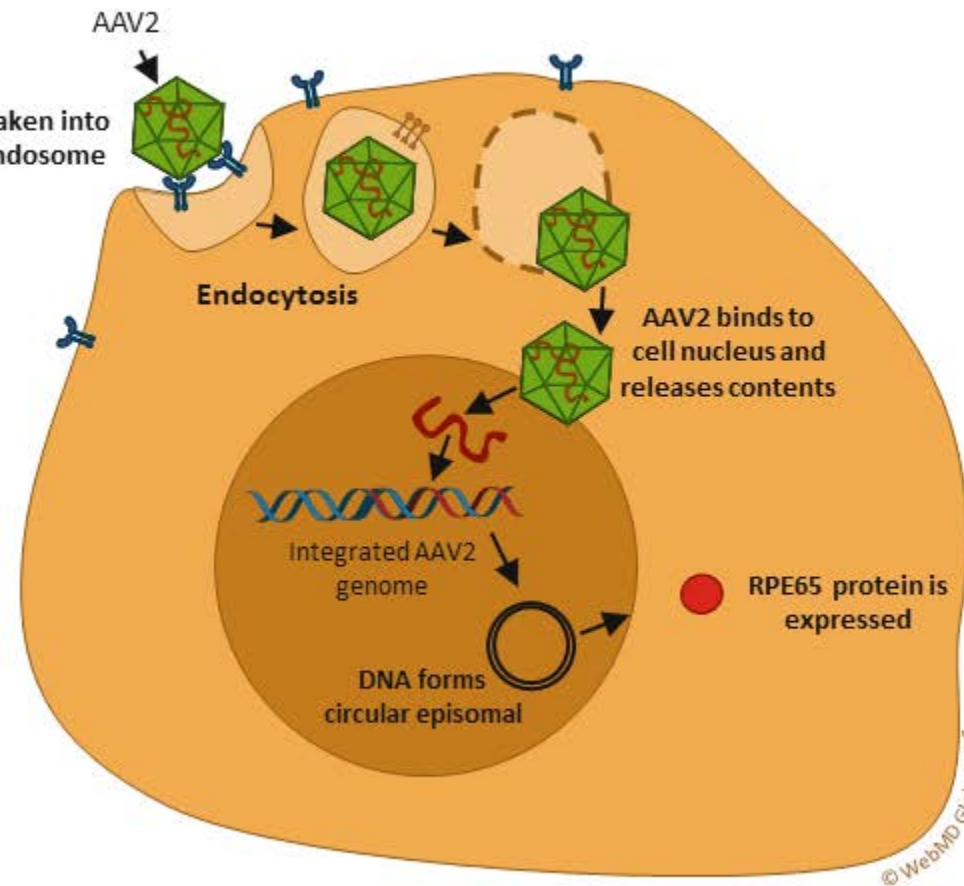
Virus vectors

Characteristic	AAV	Adenovirus	Lentivirus
Contagiousness	Low	Low	Low
Stability	Good	Good	Good
Packaging Capacity (kb)	5	36	8
Immunoreactivity	Low	High	Low
Episomal	Yes	Yes	No



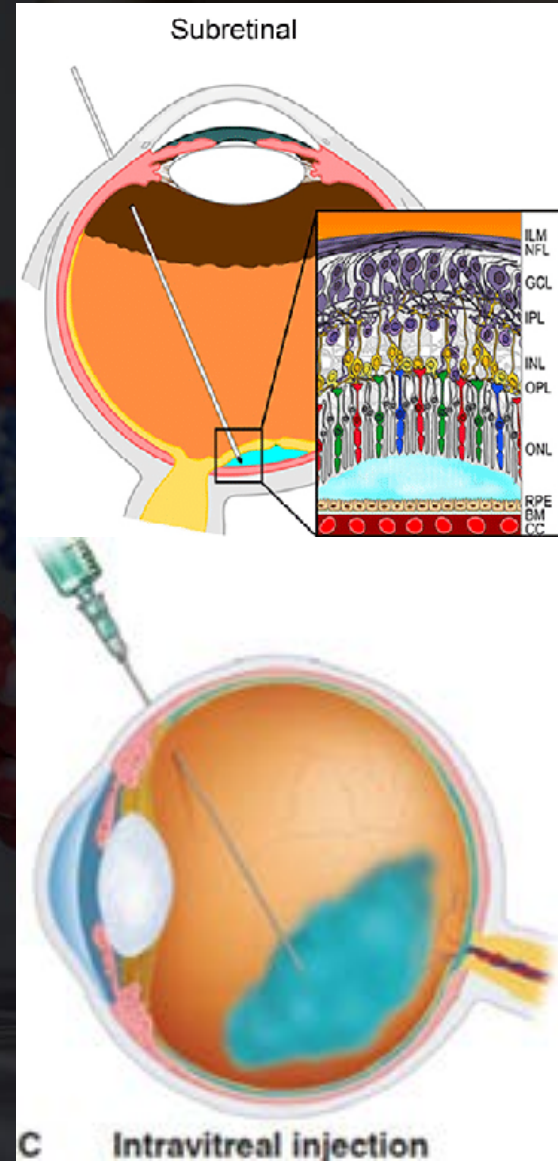
AAV – Adeno-Associated Virus

- AAV is particularly well-suited for gene therapy because it is nonpathogenic, nonimmunogenic and episomal. It does not integrate into the host DNA, but rather remains separate inside the nucleus where it is effectively expressed and translated into protein



Benefit of using the eye for gene therapy

- Easily accessible
 - Possibility to treat focally
 - Study the effect of the treatment
- Minimizes the systemic impact of the therapy
- Small organ
- Small volume of the substance is needed – reduces the challenge of producing the substance
- Immune privileged organ



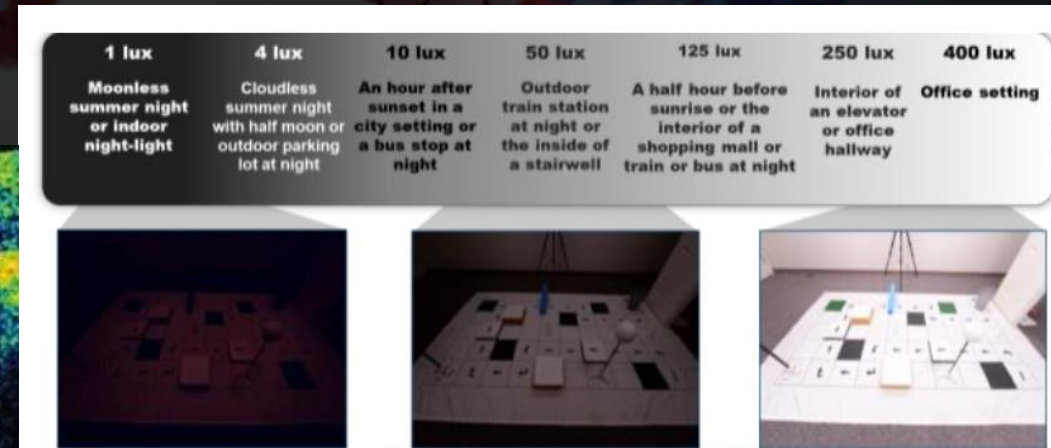
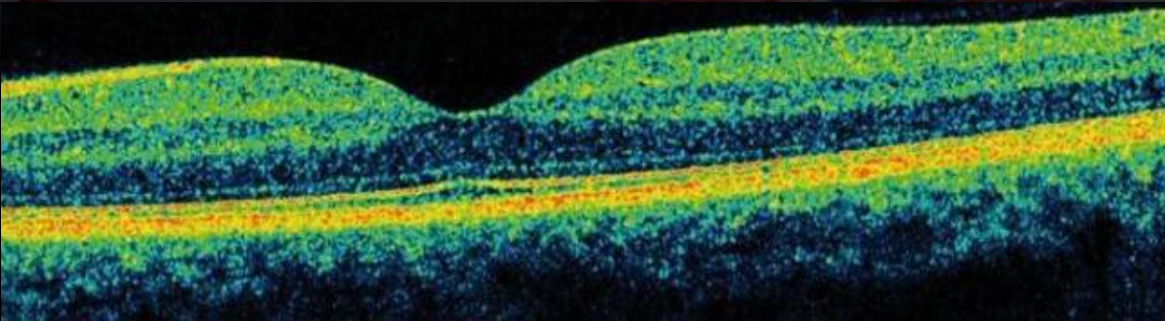
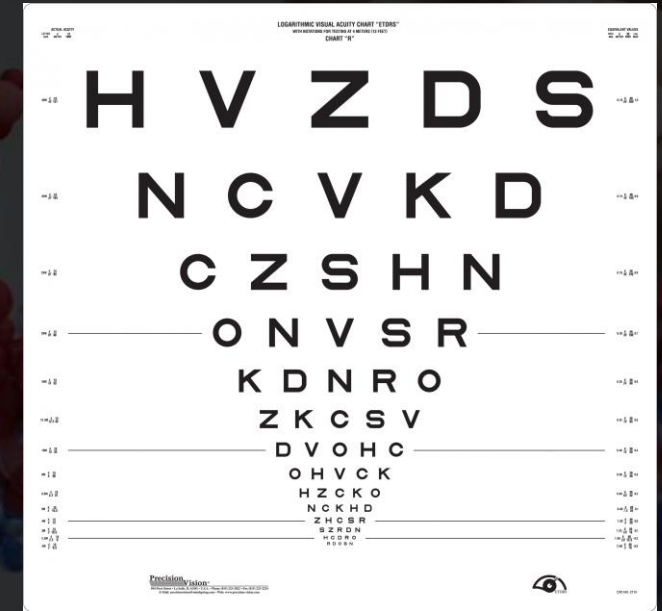
Who and how

- Inheritable retinal degeneration
- Leber's hereditary optic neuropathy
- Other monocular genetic defects

- Good collaboration with colleagues such as geneticists, paediatricians etc
- Referral to subspeciality (ERG)
 - Visual acuity, visual field, color vision, full-field ERG, multifocal mfVEP
 - Blood sampled for gene analysis – 322 genes

How to evaluate the effect of the treatment

- ETDRS
- OCT macula + angiography
- Color vision testing
- Visual field
- ERG
- Multi-Luminance Mobility Test - MLMT



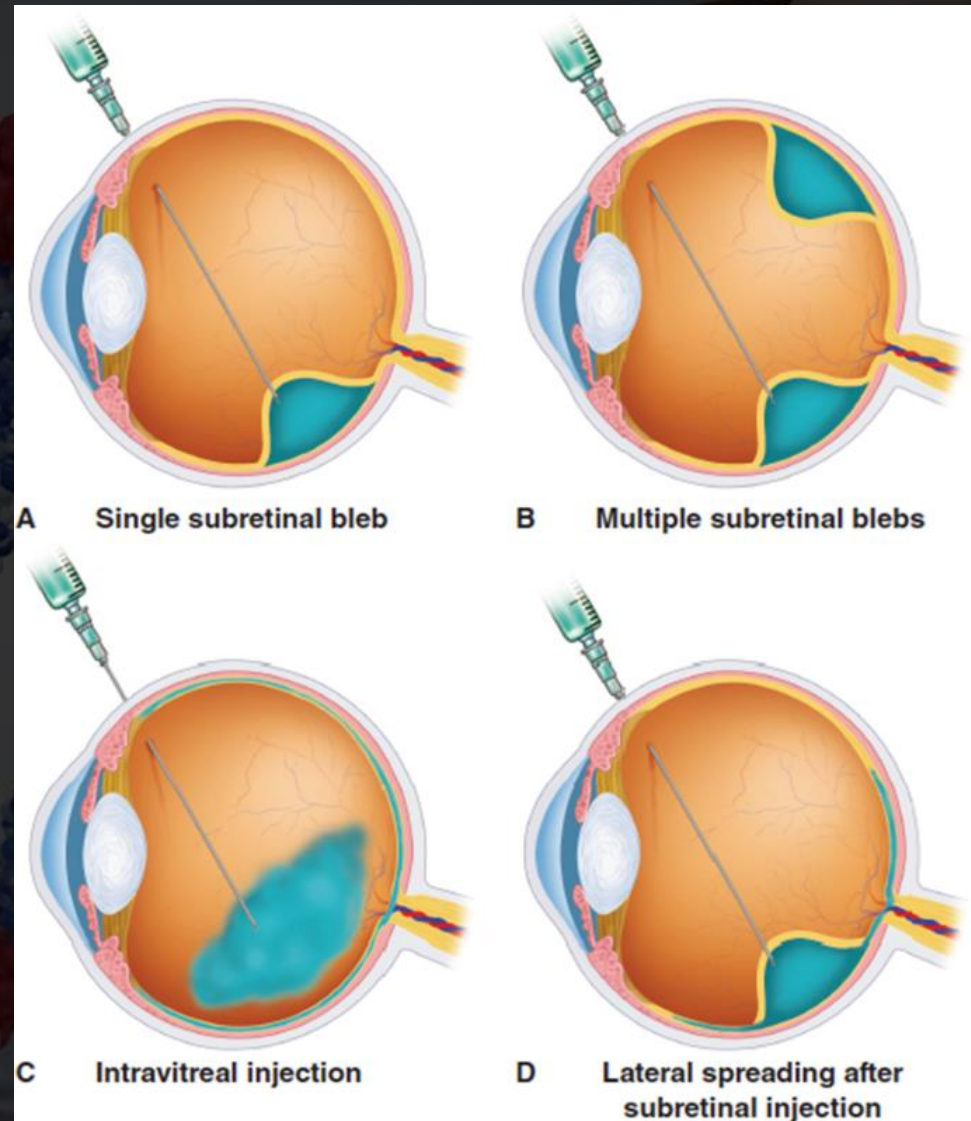
Age limitations?

- More important to find out if the cells have a potential for treatment than the patient's age
- OCT is the best way to find out if photoreceptors are present, indicating that RPE is treatable
- OCT should be combined with testing of the entire visual field to find out if a viable retina is present and if the patient will benefit from the treatment



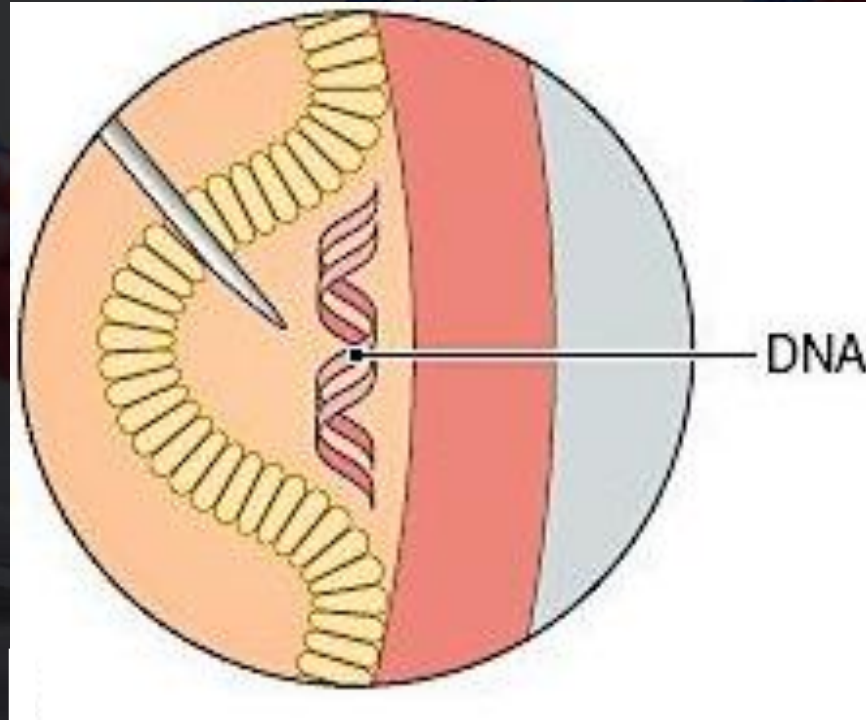
Does the degeneration continue after gene therapy?

- Subretinal injection with a bleb, limited area treated, degeneration continues outside the bleb
 - Several injections needed to treat the entire retina
- IVT treats the entire retina - theoretically the degeneration is inhibited – No evidence yet

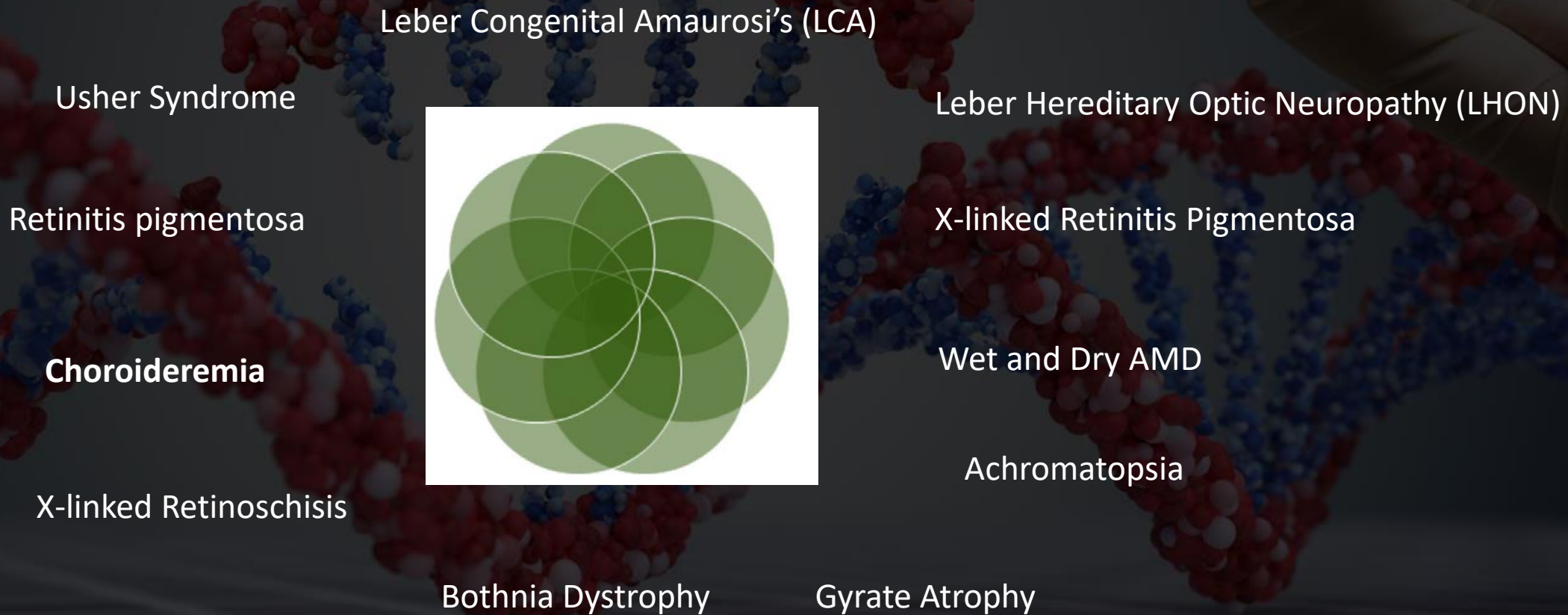


How long will the treatment last?

- Possibly forever or as long as the cells in which the therapy works are viable

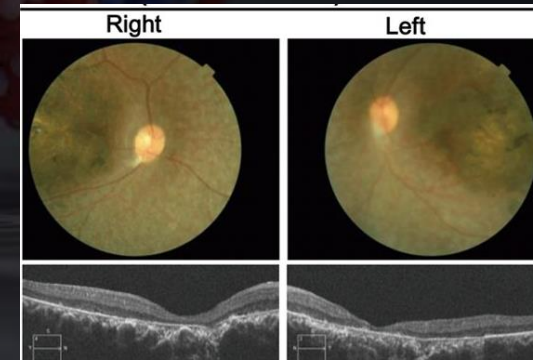
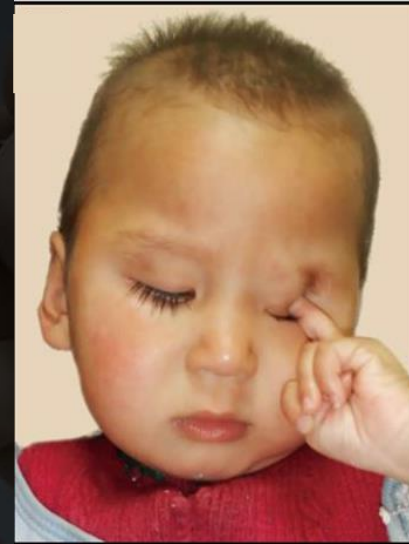

Almost 100 ongoing clinical trials – 12 eye diseases



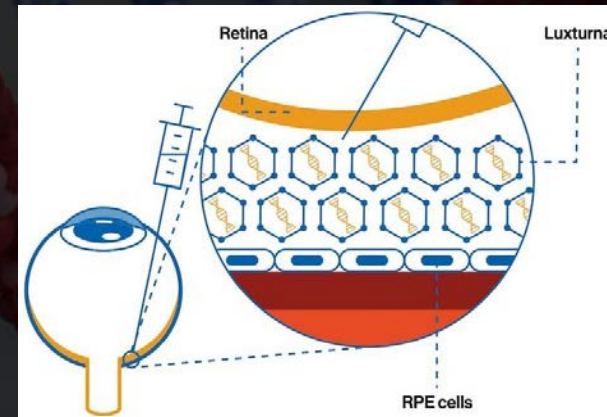
Leber Congenital Amaurosis (LCA)

- Autosomal recessive
- 17 phenotypes involving several genes
 - RPE65, GUCY2D, SPATA7, CRX etc
- Important for the development of the retina
- Nystagmus, lagging or missing pupillary light-reflex, severe visual defect, photophobia, high hyperopia, oculo-digital signs
- Retina: initially normal, later hyperpigmentation and atrophy
- Severe visual loss or blindness
- 10% of pediatric blindness



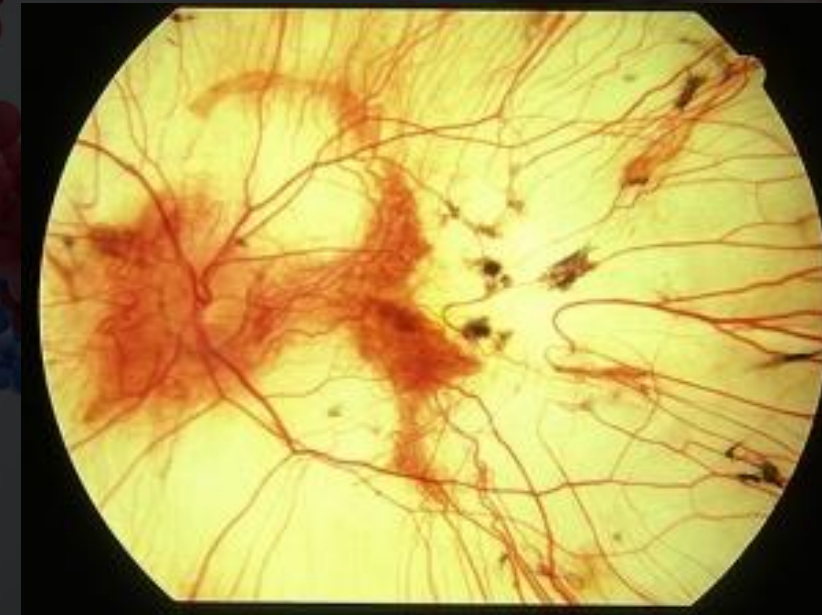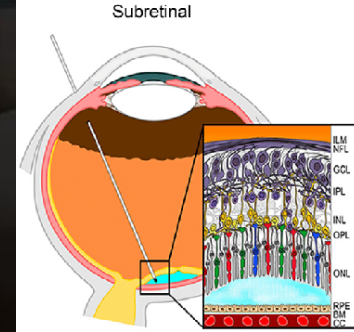
LCA- Gene Therapy

- Luxturna
- Approved in 2021
- Double mutation on *RPE65* gene
- Normal photoreceptors
- Gene therapy with a normal copy of *RPE65* gene
 - AAV2
 - Subretinal injection
- Showed significantly improved navigation
- Continued effect of treatment 3 years later

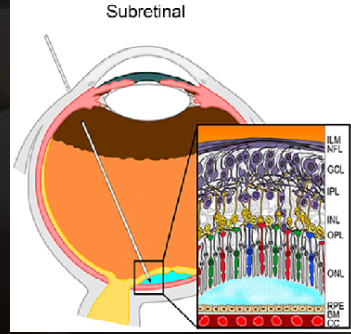


Choroideremia

- Mutation in the *CHM* gene – codes for *RPE1* – intracellular transport
- Nyctalopia – tunnel vision – worse vision
- Progressive visual loss
- X-linked recessive
- Men
- 4% of all blindness
- Subretinal injection of AAV2-REP1
- Maintained and in some cases improved vision
- Long-term follow-up is required



Wet and Dry AMD



- Wet AMD with CNV

- Subretinal injection with virus vector resulting in anti-VEGF production

- ADVM-033 (AAV-Afibcept)

- Treatment is tolerable
 - 60% injection-free after 1 year

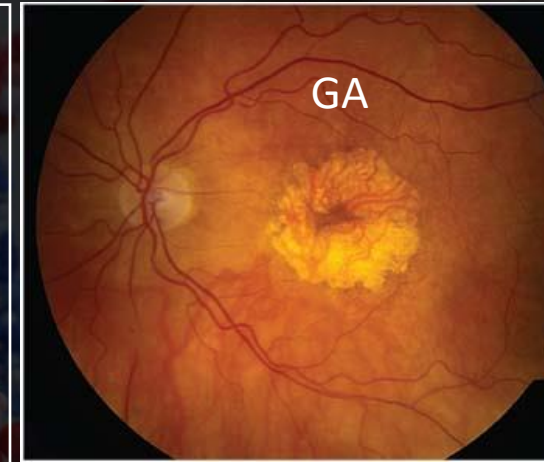
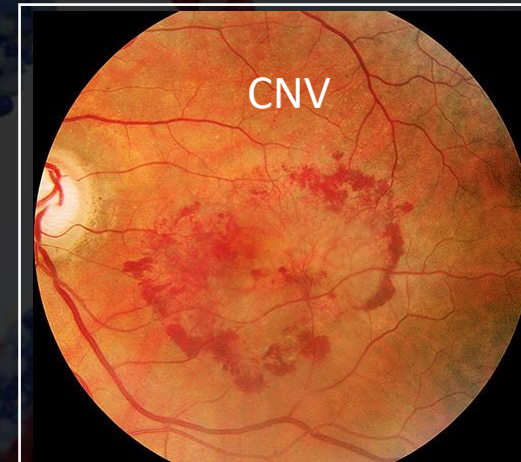
- RGX-314 (AAV-monoclonal anti-VEGF antibody)

- Treatment is tolerable
 - 80% reduction of anti-VEGF injection

- Dry AMD with GA

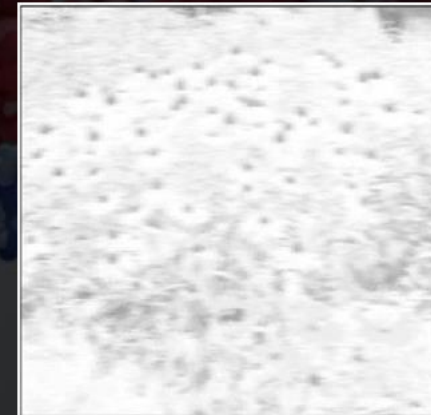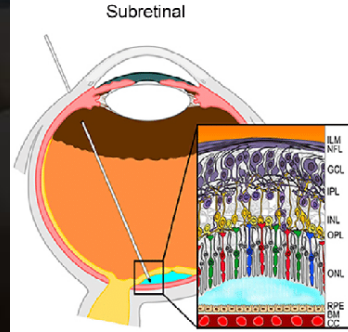
- AAV-CAGsCD5 – Block the formation of membrane attack complex, a part of complement system

- S:t Eric Eye Hospital



Achromatopsia

- Unusual bilateral autosomal recessive retinal diseases
- Mutation in one of six genes
 - *CNGA3* & *CNGB3*
- Affects all three cones
- Poor central vision, photophobia, hemeralopia, severe loss of color vision
- Subretinal injection – AAV – *CNGA3/CNGB3*
- Secure and Tolerable
- Vision becomes better but is not maintained – recruit younger patients



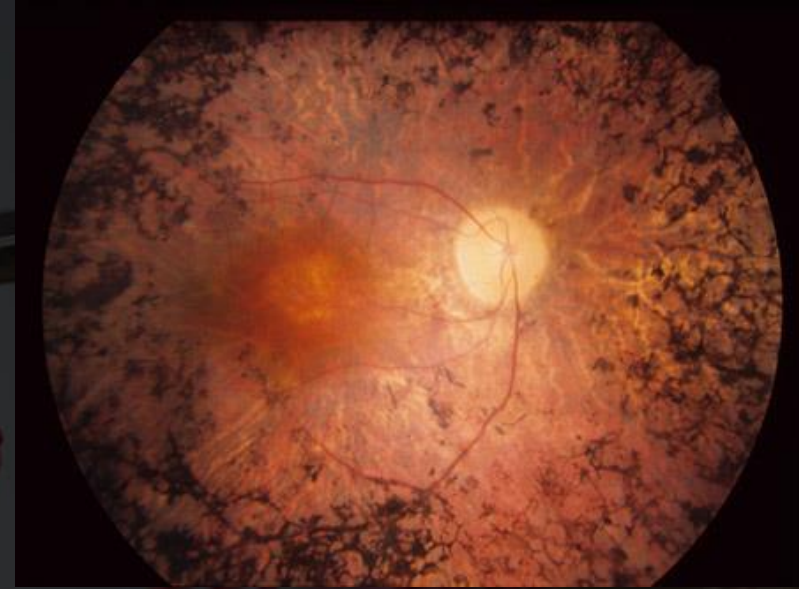Achromatopsia



Normal Vision

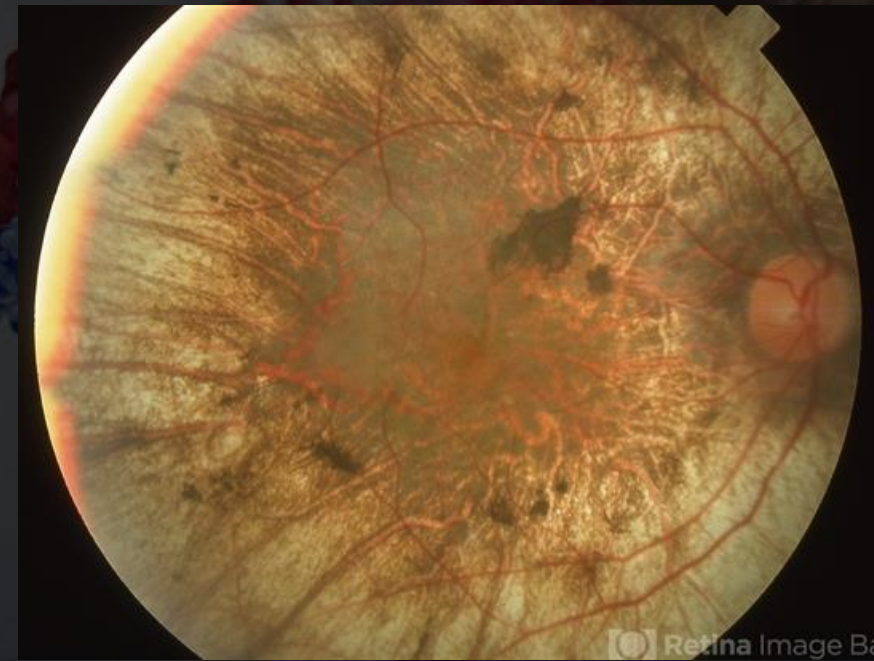
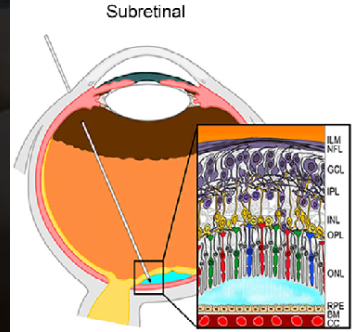
Retinitis pigmentosa

- Clinical and genetic heterogeneous disease
 - Only eye involvement or associated with a syndrome
- Inherited retinal disease
- Progressive dysfunction of rods, in the end degeneration of cones and RPE cells
- Nyctalopia and progressive visual field loss



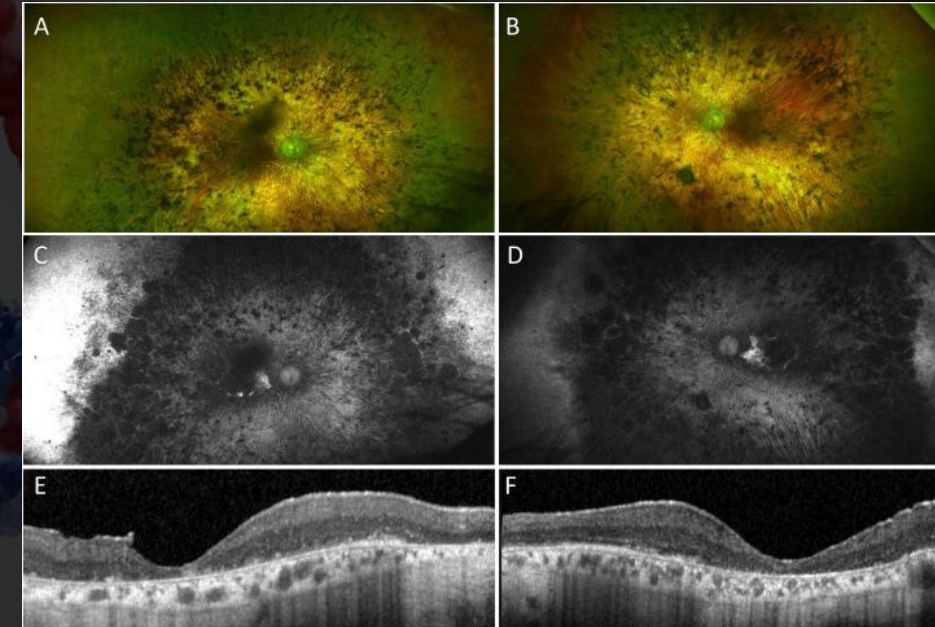
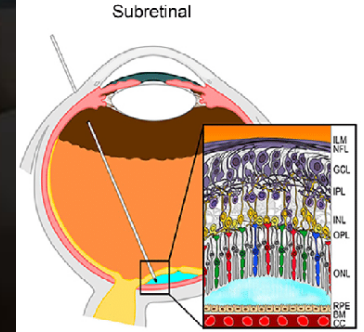
X-linked Retinitis Pigmentosa

- Mutation in retinitis pigmentosa GTPase regulator (*RPGR*) gene
- Most common - 10-20% of all RP
- Most severe phenotype
- Early onset and fast progression to blindness
- No available treatment



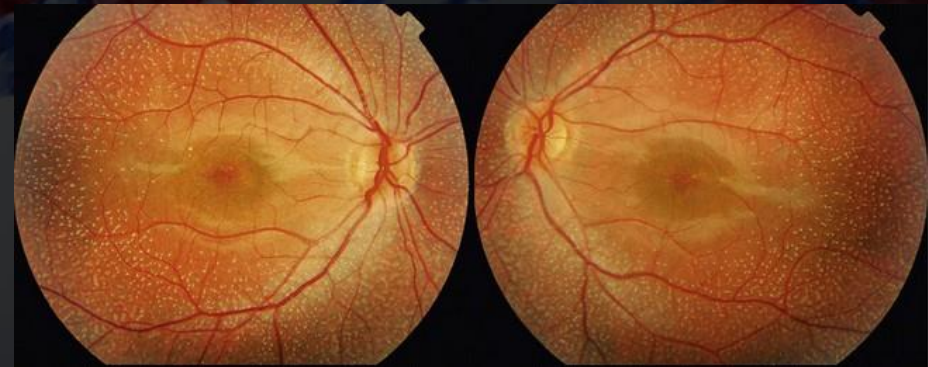
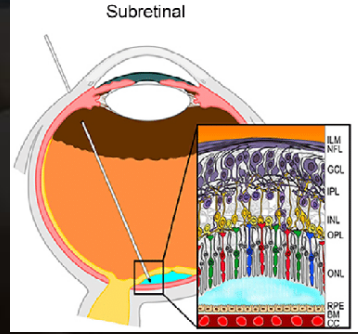
X-Linked Retinitis Pigmentosa

- Several clinical trials
- AAV8-RPGR
- Subretinal injection
- No significant difference
- Patient experiences subjective improvement
 - Better navigation
 - Manage better in dim-light
 - Feels better to be outside in the dark



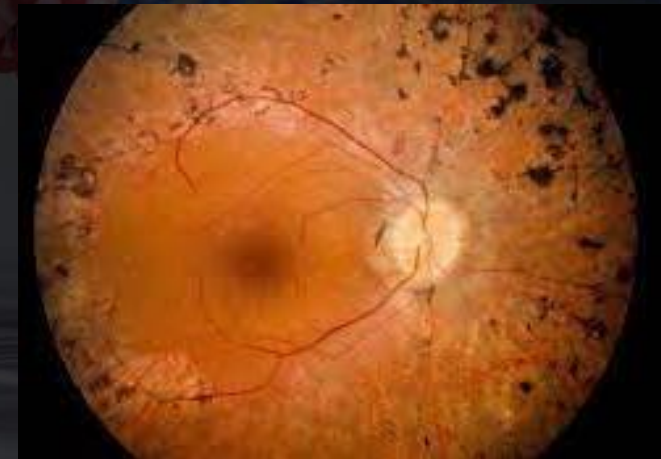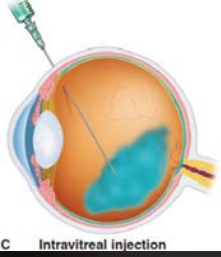
Bothnia Dystrophy

- Autosomal recessive
- High prevalence in north of Sweden
- Early onset of nyctalopia -> macular degeneration and loss of sight in adulthood
- Mutation of *RLBP1* gene
- A form of RP
- Gene therapy CPK850 – S:t Eric Eye Hospital
- Subretinal injection – 15 patients



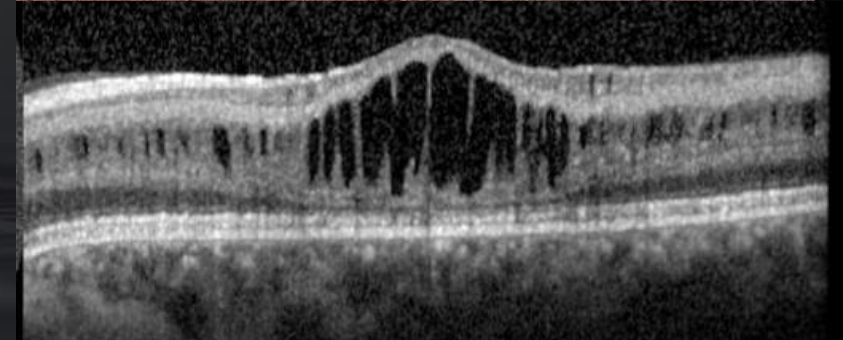
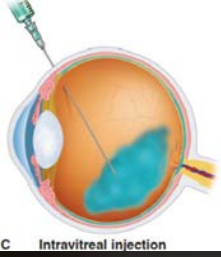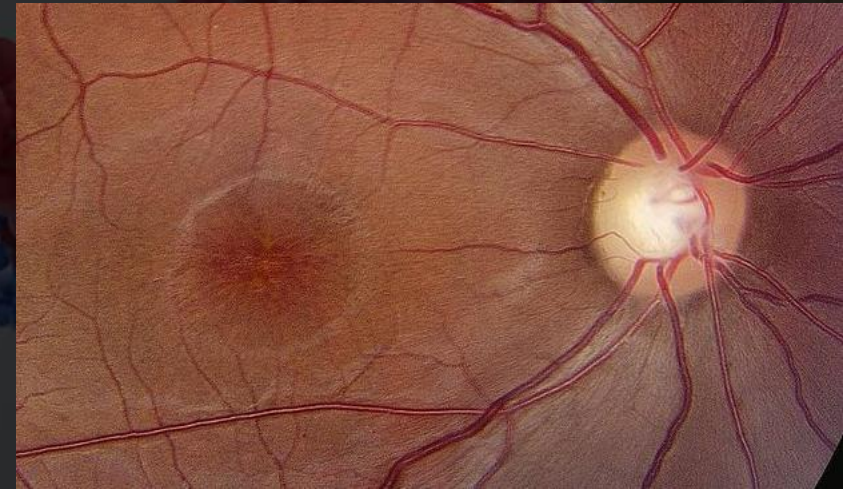
Usher Syndrome

- Unusual autosomal recessive retinal disease - a form of RP
- Progressive visual- and hearing loss
- 3 subtypes
- Gene Therapy – Subtype 2 – mutation in exon 13 of *USH2A* gene
- Repeated IVT every 6 months – RNA antisense oligonucleotide
- No results yet

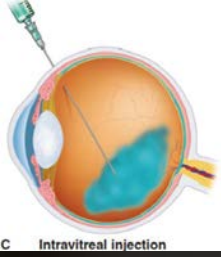


X-linked Retinoschisis

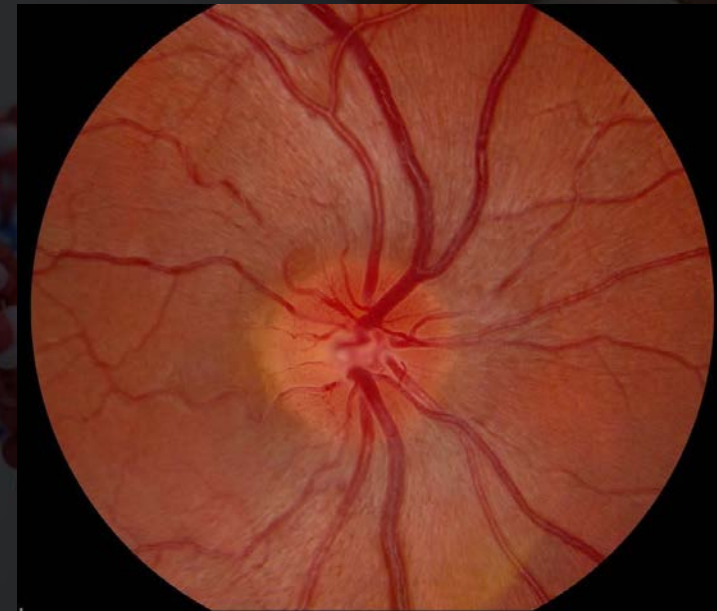- Mutation of *RS1* gene -> abnormal function of retinoschisis protein -> separation of neuroretina, usually in the macula region -> vision decrease
- Young males
- Intravitreal injection - AAV-RS1
- Study test tolerability, dose, vision, OCT, ERG
 - Tolerable
 - One year data
 - No effect on vision, OCT or ERG



Leber Hereditary Optic Neuropathy (LHON)

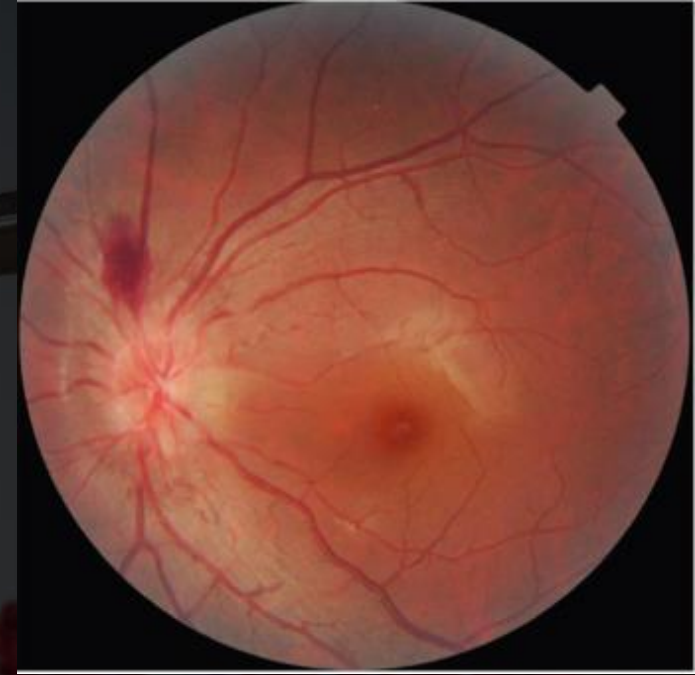

- Rare, maternally inherited mitochondrial mutation
- Most common in young men
- Blindness initially in one eye, but shortly afterwards also in the other eye
- Optic nerve involvement - variable phenotype
- AAV-ND4 gene
- Intravitreal injection
- The virus vector -> retinal ganglion cell -> is transcribed -> transported to the mitochondrion



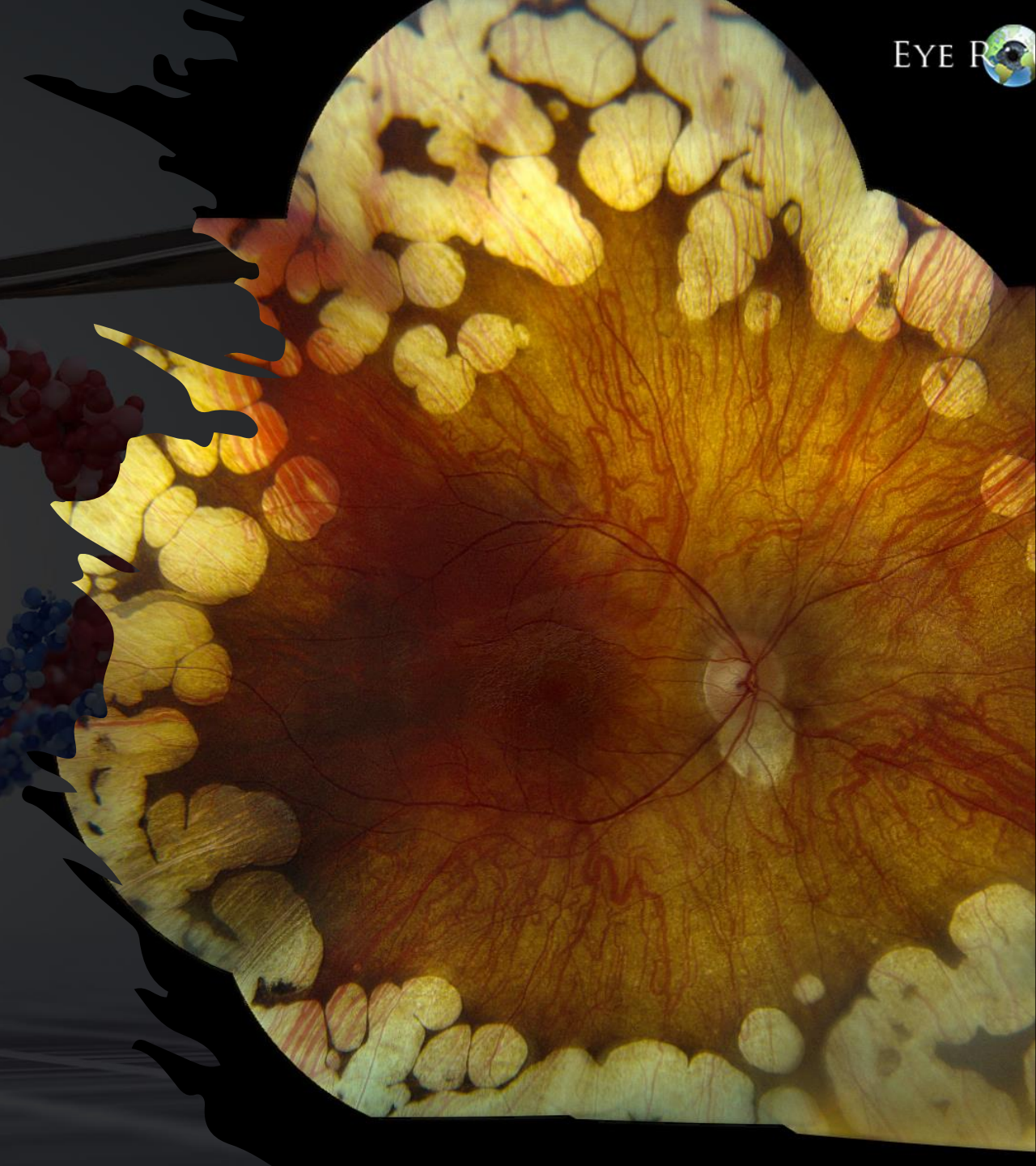
LHON

- 50 injections in one eye and placebo in the other
- 48 bilat injections
- Median duration of vision loss; 8 months
- Those who were injected in one eye also had an effect in the other eye -> difficult to interpret the results
- Improved vision by 3 lines
- Better results were hoped for
- Early treatment did not show better results



Gyrate Atrophy

- Unusual autosomal recessive retinal disease
- Progressive chorioretinal degeneration, early onset cataract and myopia
- Nyctalopia appears around 10 years of age
- Lack of OAT enzyme -> 20 fold increase of ornitin in plasma
- There is a treatment
 - Amino acide tablets
 - Diet low in protein, fruits and vegetables
 - No more then 200 calories/day from fat and carbohydrates



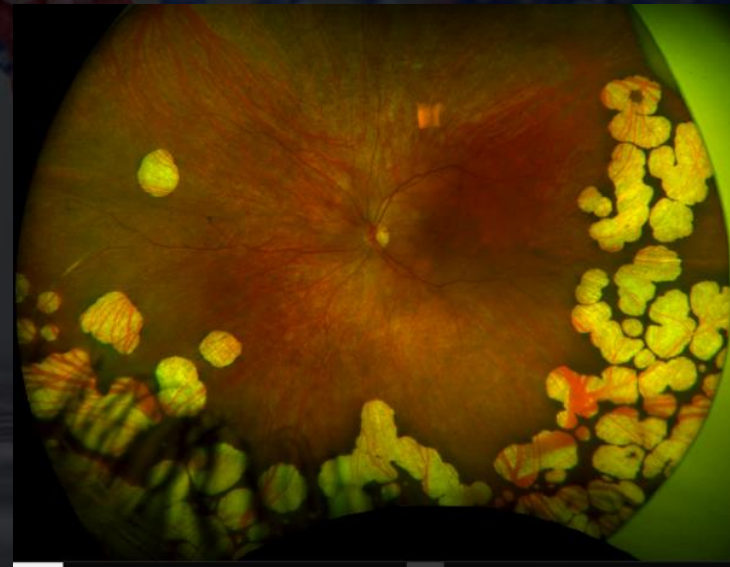
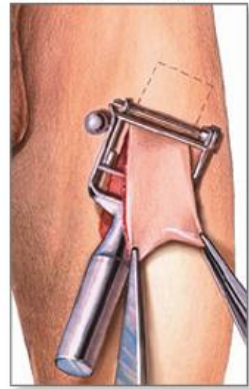
Gyrate Atrophy

- Skin biopsy from thigh 5x5 cm
- Keratinocytes are harvested, cultivated and normal OAT gene is implanted with retrovirus
- Keratinocytes with normal OAT gene are engrafted back to the thigh

Study design

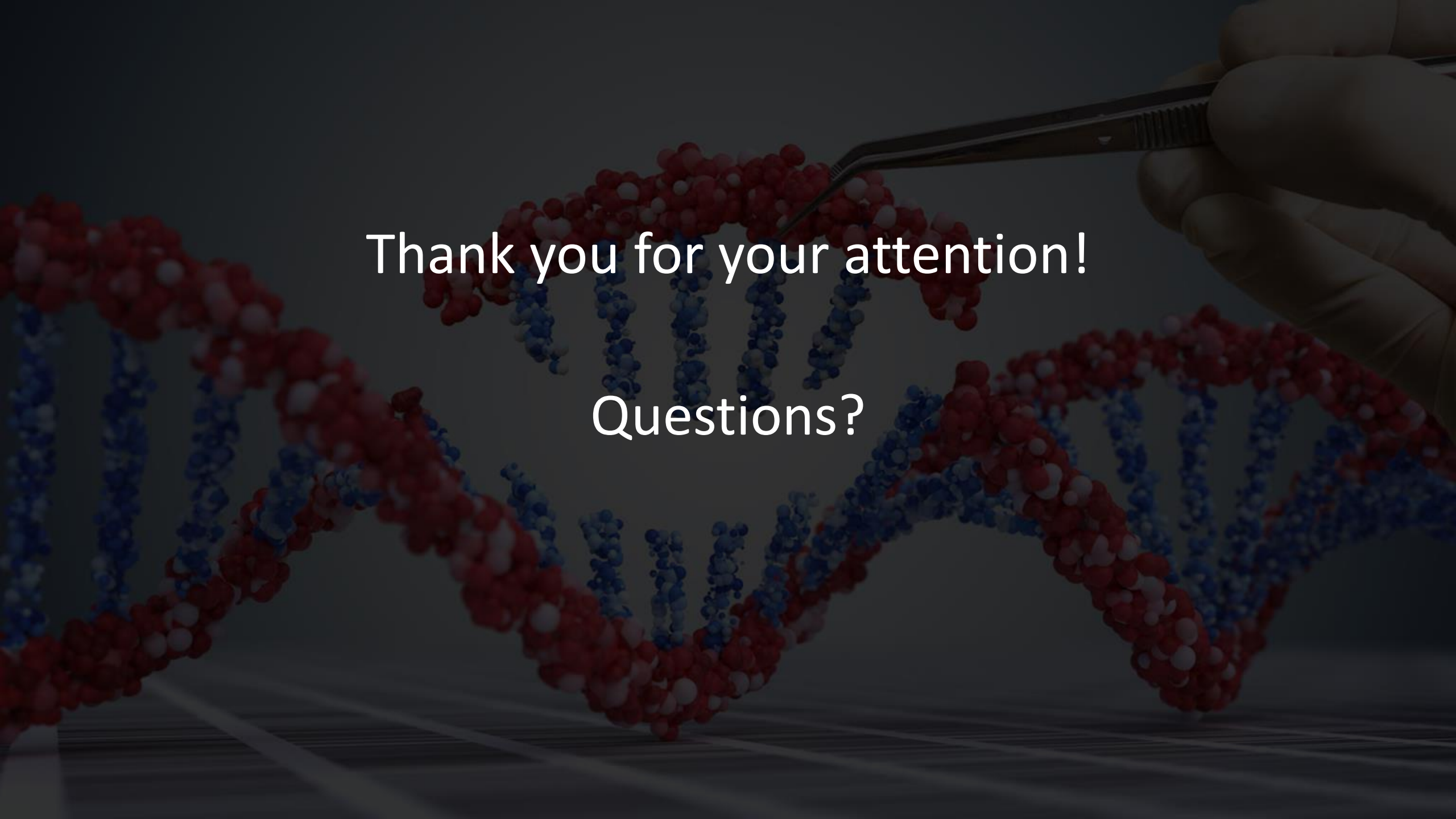
1. Can the cells express the gene
2. Amount and duration of expression
3. Are the levels enough to lower ornithin level in serum
4. Effect in the eye

Graft taken from patient's healthy skin



In Summary

- We are entering a new era where patients with known genetic defects will be able to receive treatment in the future
- Luxturna – a milestone that shows that these treatments will be increasingly developed in the future
- Approved by both FDA and EMA
- 10 eye conditions are included in clinical studies with Gene Therapy
- It is important that these patients are cared for correctly

A hand in a white glove is using tweezers to hold a DNA double helix model. The model is composed of red and white spheres forming the sugar-phosphate backbone, and blue spheres representing nitrogenous bases. The background is dark and slightly blurred, showing a grid pattern.

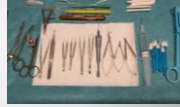Thank you for your attention!

Questions?

Glaucoma surgery



Jesper Leth Hougaard
Consultant and senior surgeon, PhD
Dept. of Ophthalmology
Skåne University Hospital
Malmö
Sweden



 Skåne University Hospital

Financial disclosure

- AbbeVie/ALLERGAN – Honoraria for lecturing/presentations and for advisory board
- No personal financial interest in any of the products mentioned

 Skåne University Hospital

The goal of glaucoma surgery

- To lower the intraocular pressure!
- to lower the risk of further glaucomatous visual damage
- to reduce the need of medication



Glaucomatous damage to the optic nerve head is unfortunately not reversible!
Need to do surgery before it's too late



 Skåne University Hospital

The goal of glaucoma surgery

VFI The percentage left of a full visual field

28 mmHg

12 - 14 mmHg

Age

Indications for glaucoma surgery

- When medication or laser trabeculoplasty do NOT prevent a **clinically significant** loss of visual function
- When the treated intraocular pressure is at a level that inevitably will result in loss of visual function
- When the treatment stabilizing the visual function is not tolerated (local or systemic side effects)
- When the risk of losing visual function after surgery is not greater than the risk without surgery

BASELINE visual fields

Feb. 2012 VFI 72%

Mar. 2015 VFI 57%

Oct. 2021 VFI 42%

AGE: 62 y

Likely progression

The physiological outflow

Anterior chamber

Trabecular meshwork

Angle

Fluid exits here

Conjunctiva

Fluid forms here

Schlemm's Canal

Cornea

Pupil

Lens

Ref: National Eye Institute, National Health Institute. (modified)

1. Increase the outflow
2. Reduce the production of fluid

Anterior chamber
 Cornea
 Pupil
 Iris
 Lens
 Meshwork
 Angle
 Fluid exits here
 Conjunctiva
 Fluid forms here

Ref: National Eye Institute, National Health Institute

Skåne University Hospital

1. Increase the outflow

Anterior chamber
 Cornea
 Pupil
 Iris
 Lens
 Meshwork
 Angle
 Fluid exits here
 Conjunctiva
 Fluid forms here

Ref: National Eye Institute, National Health Institute

Skåne University Hospital

Micro Invasive Glaucoma Surgery (MIGS)
 most often combined with cataract surgery

- **Implants/Stents**

 IStent
 Other: e.g. Hydrus
 Ref: Gans
- **Tissue excision/disruption**

 NEW WORLD
 KDB: Kahook Dual-Blade
 Other: e.g. Omni, Trabectome, GATT
 -if- or just dilatation of the Schlemm's canal

1. Increase the outflow

Anterior chamber
 Cornea
 Pupil
 Iris
 Lens
 Meshwork
 Angle
 Fluid exits here
 Conjunctiva
 Fluid forms here

Ref: National Eye Institute, National Health Institute

Skåne University Hospital

Non-penetration glaucoma surgery
 Difficult surgery
 Few surgeons in Sweden

Establish an outflow canal from the Schlemm's canal to drain the aqueous from the eye

Leaving the flow resistance of the meshwork reduce the risk for postoperative hypotony

1. Increase the outflow

Filtering glaucoma surgery

- Filtering stents/Minimally Invasive Bleb Surgery (MIBS):
 - XENAM5/63 (implanted from the inside)
- Preserflo (implanted from the outside)

Ref: National Eye Institute, National Health Institute

Skåne University Hospital

1. Increase the outflow

Traditional filtering glaucoma surgery

- Trabeculectomy

Ref: National Eye Institute, National Health Institute

Skåne University Hospital

TUBE surgery

Tubes/shunts with a valve:

- Ahmed

Tubes/shunts without a valve:

Plate position under the muscles:

- E.g. Baerveldt and Paul (the thinned tube diameter)

Plate position between the muscles

- E.g. Molteno

Ref: <https://www.willhays.org/glaucoma-tube-shunt/>

Skåne University Hospital

1. Increase the outflow

Anterior chamber
Cornea
Pupil
Iris
Lens
Meshwork
Angle
Fluid exits here
Conjunctiva
Fluid forms here

Suprachoroidal MIGS surgery

MINIJECT

Ref: National Eye Institute, National Health Institute

Ref: ISAR MEDICAL

Skåne University Hospital

2. Reduce the production of fluid

chamber
Cornea
Pupil
Iris
Lens
Meshwork
Angle
Fluid exits here
Conjunctiva
Fluid forms here

Cyclophotocoagulation

- E.g. Diode laser externally applied

Ref: ISDOX

Ref: T. Agreus et al.

- Other methods: e.g. micropulse cyclophotocoagulation

Ref: National Eye Institute, National Health Institute

Skåne University Hospital

When should different methods be used?

Traditional order of surgery for the standard patient

Use of cytostatics
e.g. mitomycin

MIGS?
e.g. Miniject, KDB or Omni, phako

Supra-choroidal implant
e.g. Miniject

MIBS
e.g. KDB or Preserflo

Phaco (Shunt)

Cyclophotocoagulation

EFFECT vs. RISK

The less glaucomatous damage the higher priority of safety when choosing treatment/surgical option
- often at the cost of efficacy

Skåne University Hospital

The major obstacle to surgical success

FIBROSIS = scar formation

To prevent it (in filtering surgery):

- use of cytostatic MMC at the site of surgery in filtering surgery
- many control visits after surgery
- intense cortisone drop treatment after surgery
- break down scar formation with "needling" and the use of cytostatic 5-FU
- pressure lowering eye drops in Shunt/Tube surgery if pressure rises




Before the surgery

Important to plan the surgery in agreement with the patient

- What to expect - depending on the surgery!
- What are the patients able to manage on their own/with assistance?

- NO improvement of visual function (if not combined with phako!)
- Complication risks (balanced towards risk of glaucomatous damage)
- Surgery is almost always done in local anaesthesia
- ± frequent steroid eye drops before and/or after the surgery?
- ± adjust antidiabetic medications preoperatively?
- ± reduced number of, or off IOP lowering medications?
- ± frequent control visits (and for how long)?
- ± physical restrictions?



Postoperative complications

Too low pressure (seriously a risk for damage to the retina):

- Too much outflow/hypofiltration?** - Cycloplegia? Bandage contact lens? Reduce cortisone? Surgery?
- Leakage?** - Antibiotics and bandage contact lens? Cycloplegia? Reduce cortisone? Surgery?
- Stent erosion through conjunctiva?** - Antibiotics and surgery!
- Ciliary body shutdown?** - Cycloplegia? Wait and see?
- (Cyclo)atropia (cliff)?** - Wait and see? Laser? Surgery?

Too high pressure (a risk for optic nerve head):

- Too little outflow/hypofiltration?
- Relaxing/needling/pulling of retina
- Malignant glaucoma? - Iridotomy? Press.
- Choroidal bleeding? - Pressure lowering e.g. OSUNROL/MANNITOL/GLYCEROL? Surgical drainage??

Other changes may include:

- Dissected Maculae folds**
- Shallow or flat anterior chamber**
- Retinal folds or vitreous colima**
- Choroidal detachment**

optic nerve head:

- vent reasons?
- g drops? Revisions/new surgery?
- L/GLYCEROL? Vitrectomy?

Infection:

- In the drainage bladder/bleb (blebitis) - unusual
- In the eye (endophthalmitis) - very rarely

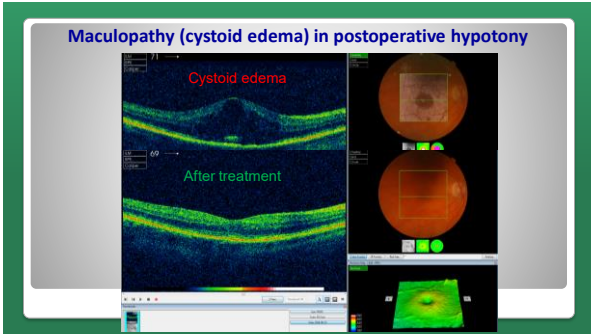
Cataract formation:

- often reversible

Diplopia (Tubes/shunts):

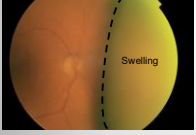

- often reversible
- Corneal endothelial cell loss/dyscompaction
- Mostly a problem in tube surgery





Leakage/hyperfiltration and hypotony

Below:
 A patient with too much outflow and detachment of the choroid (swelling) after trabeculectomy
 The IOP is often < 4-6 mmHg

Skåne University Hospital

Postoperative complications

Too low pressure (primarily a risk for damage to the retina):
 Too much outflow/hyperfiltration? - Cycloplegia? Bandage contact lens? Reduce cortisone? Surgery?
 Leakage? - Antibiotics and bandage contact lens? Cycloplegia? Reduce cortisone? Surgery?
 Stent erosion through conjunctiva? - Antibiotics and surgery!
 Glaucoma shutdowns? - Cycloplegia? Wait and see?
 Cyclodialysis cleft? - Wait and see? Laser? Surgery?

Too high pressure (a risk for damage to the glaucomatous optic nerve head):
Too little outflow/hypofiltration? Stops at different levels for different reasons?
 Microsurgical (re)setting (pulling) of releasable sutures? Pressure lowering drops? Revision/new surgery?

Malignant glaucoma? - Iridotomy? Pressure lowering e.g. DIAMOX/MANNITOL/GLYCEROL? Vitrectomy?
Choroidal bleeding? - Pressure lowering e.g. DIAMOX/MANNITOL/GLYCEROL? Surgical drainage??

<p><u>Infection:</u> In the drainage bladder/bleb (blebitis) - unusual In the eye (endophthalmitis) - very rarely</p>	<p><u>Cataract formation:</u> often reversible</p> <p><u>Diplopia (Tubes/shunts):</u> often reversible</p> <p><u>Corneal endothelial cell loss/dyscomformations:</u> Mostly a problem in tube surgery</p>
---	--

Skåne University Hospital

Postoperative complications

Too low pressure (primarily a risk for damage to the retina):
 Too much outflow/hypofiltration? - Cycloplegic? Bandage contact lens? Reduce cortisone? Surgery?
 Leakage? - Antibiotics and bandage contact lens? Cycloplegic? Reduce cortisone? Surgery?
 Stent erosion through conjunctiva? - Antibiotics and surgery!
 Oily body shunt(s) - Cycloplegic? Wait and see?
 (Cycloalysis clut?) - Wait and see? Laser? Surgery?

Too high pressure (a risk for damage to the glaucomatous optic nerve head):
 Too little outflow/hypofiltration? Stops at different levels for different reasons?
 Massage/needling/pulling of releasable sutures? Pressure-lowering drops? Revision/new surgery?
 Malignant glaucoma? - Miotics? Pressure-lowering e.g. DIAMON/MANNITOL/GLYCEROL/Vitrectomy?
 Choroidal bleeding? - Pressure-lowering e.g. DIAMON/MANNITOL/GLYCEROL? Surgical drainage??

Infection:
 In the drainage bladder/bleb (blebitis) - unusual
 In the eye (endophthalmitis) - very rarely
TREAT even a simple conjunctivitis with AB in these patients!

Cataract formation:
Diplopia (Tubes/shunts):
 often reversible
Corneal endothelial cell loss/dyscompaction:
 Mostly a problem in tube surgery



Important to identify significant postoperative complications!

A focused anamnesis:

Constant or increasing pain and/or visual impairment

Foreign body sensation without constant visual impairment

+/- redness +/- infektion

A reliable measurement of the visual acuity:

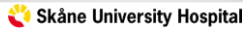A reliable intraocular pressure measurement:

ALL patients MUST be tested for glaucoma postoperatively!

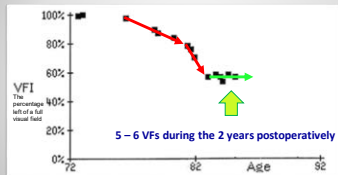
Remember that a very low IOP can be okay in patients with a thin cornea and that a pressure of e.g. 9 mmHg can be too low in patients with a thick cornea!

Remember to calibrate the tonometer!

DO NOT use different methods to measure the pressure from time to time!



Evaluate the postoperative rate of visual field progression



Important to confirm that the new IOP level provide an acceptable ROPI!

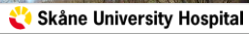

Summary

- The many new techniques give surgeons multiple opportunities to help the glaucoma patient
 - Important to personalize the surgery in agreement with the patient
 - Important to identify postoperative complications as early as possible



Thank you for the attention
Time for questions!



Nordic Congress for Ophthalmic Nurses

Education in the Nordic countries Panel discussion

Financial disclosures:

Fagligt Selskab for Øjensygeplejersker



DASYS - Dansk Sygepleje Selskab (The Danish Nursing Society)



DASYS
Dansk Sygepleje Selskab

DSR - Dansk Sygeplejeråds Stipendiefond



Presentation

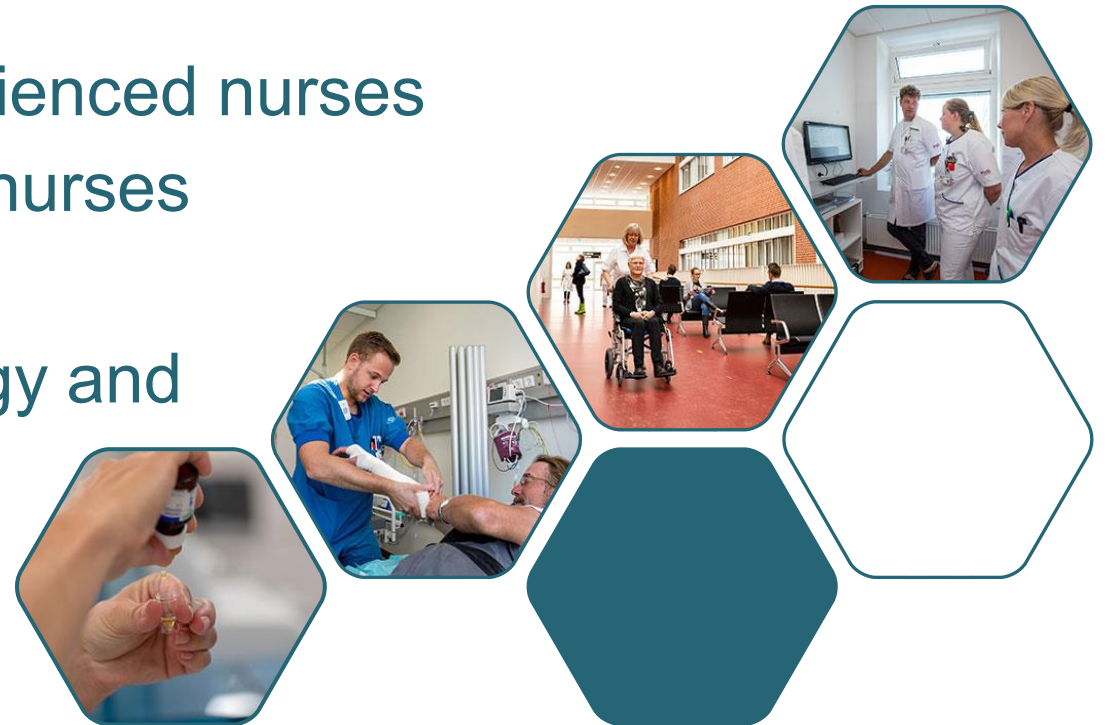Louise Bystrup, RN, MPH (Master of Public Health),
Responsible for Clinical development (Udviklingsansvarlig sygeplejerske)
at Department of Ophthalmology, Aarhus University Hospital
Director of Education in Ophthalmic Nursing Care
(Programansvarlig for Videreuddannelse i Oftalmologisk Sygepleje)

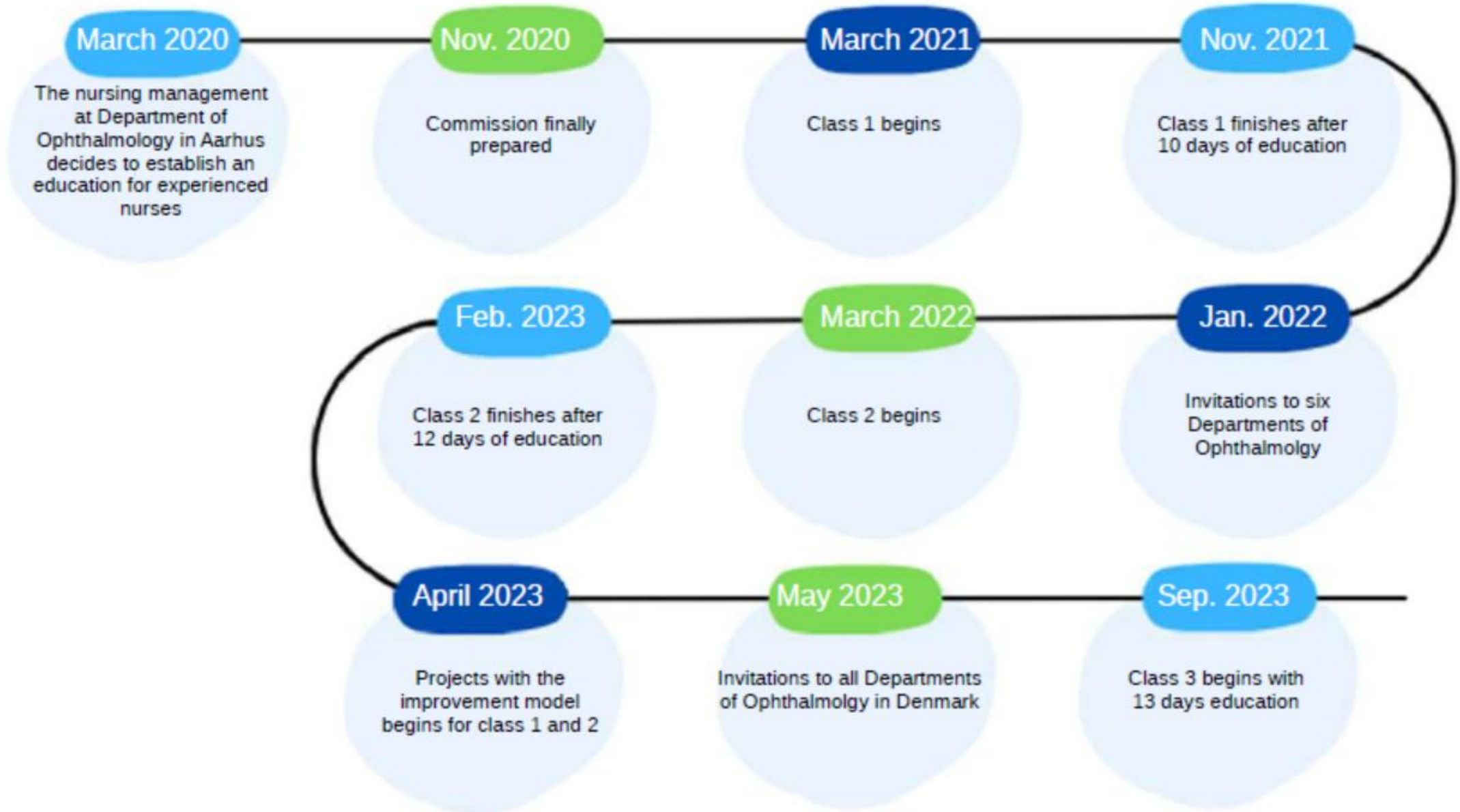Trine Agerbæk, RN, MLP (Master of Learning Processes),
Clinical Educator (Uddannelsesansvarlig sygeplejerske)
at Department of Ophthalmology, Aarhus University Hospital
Director of Education in Ophthalmic Nursing Care
(Programansvarlig for Videreuddannelse i Oftalmologisk Sygepleje)

Education in Ophthalmic Nursing Care

Why did we establish this education?

- Competence development of experienced nurses
- Important to prioritize experienced nurses
- Retention of employees
- Greater knowledge of ophthalmology and ophthalmic nursing care





Programme content

- Cataract and calculation of special lenses
- AMD
- Surgical treatment of retinal diseases
- The acute eye patient
- Eksternal eye diseases
- Diabetes
- Tumor
- Cornea
- Glaucoma
- Child and adult strabismus
- Refractive surgery
- Pediatric ophthalmology
- Tear ducts
- Neuroophthalmology
- Uveitis
- Eye thrombosis
- Ophthalmology in a historical perspective



Programme content

- Nursing care for patients in different ophthalmological diseases
- Nursing care for elderly patients
- Nursing care for socially vulnerable patients
- Youth and generations
- Transfer and learning
- Self efficacy
- Relational coordination og behavioral profilation
- Coping strategies and moral stress amongst nursing staff
- Quality development
- The Improvement Model
- Center for Vision and Assistive Technology
- The Danish Cornea Bank



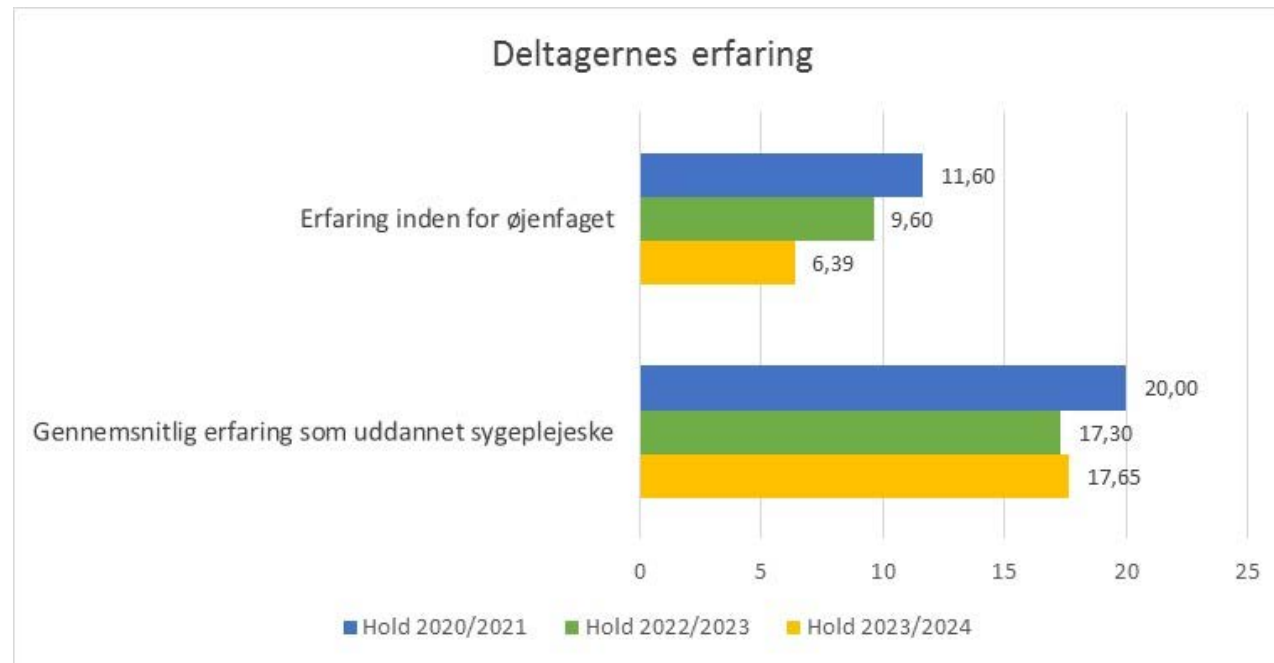
Programme

There are 14 education days distributed over a period of one year. At the end of the first year the participants make a presentation of a patient case which reflects a nursing problem.

After the first year the participants continues with an improvement project in their own departments. At the end of the second year the participants make a presentation of their development projects.



Participant nurses seniority



Participation of nurses from eight out of ten Departments of Ophthalmology in Denmark



Evaluation

By the Delphi-method



Evaluation - statements

Have the opportunity to exchange experiences

Professional knowledge of eye diseases strengthened to a large extent

Given great insight into other eye diseases than you work with on a daily basis

I now feel like a more professionally skilled eye nurse in a broader sense

More focus on own professionalism and additional joy in practice

Safe learning environment

Could spend more time on knowledge sharing/exchange

More focus on nursing



Facts about Education in Ophthalmic Nursing Care

The education is...

- primarily situated at Aarhus University Hospital
- not at university level/academic education and you do not obtain a title or credits
- offered national to experienced ophthalmic nurses (RN) working at a hospital

The students get wages when studying, because they are still working full time. They get a day off when there is an education day, but have to study in their spare time.

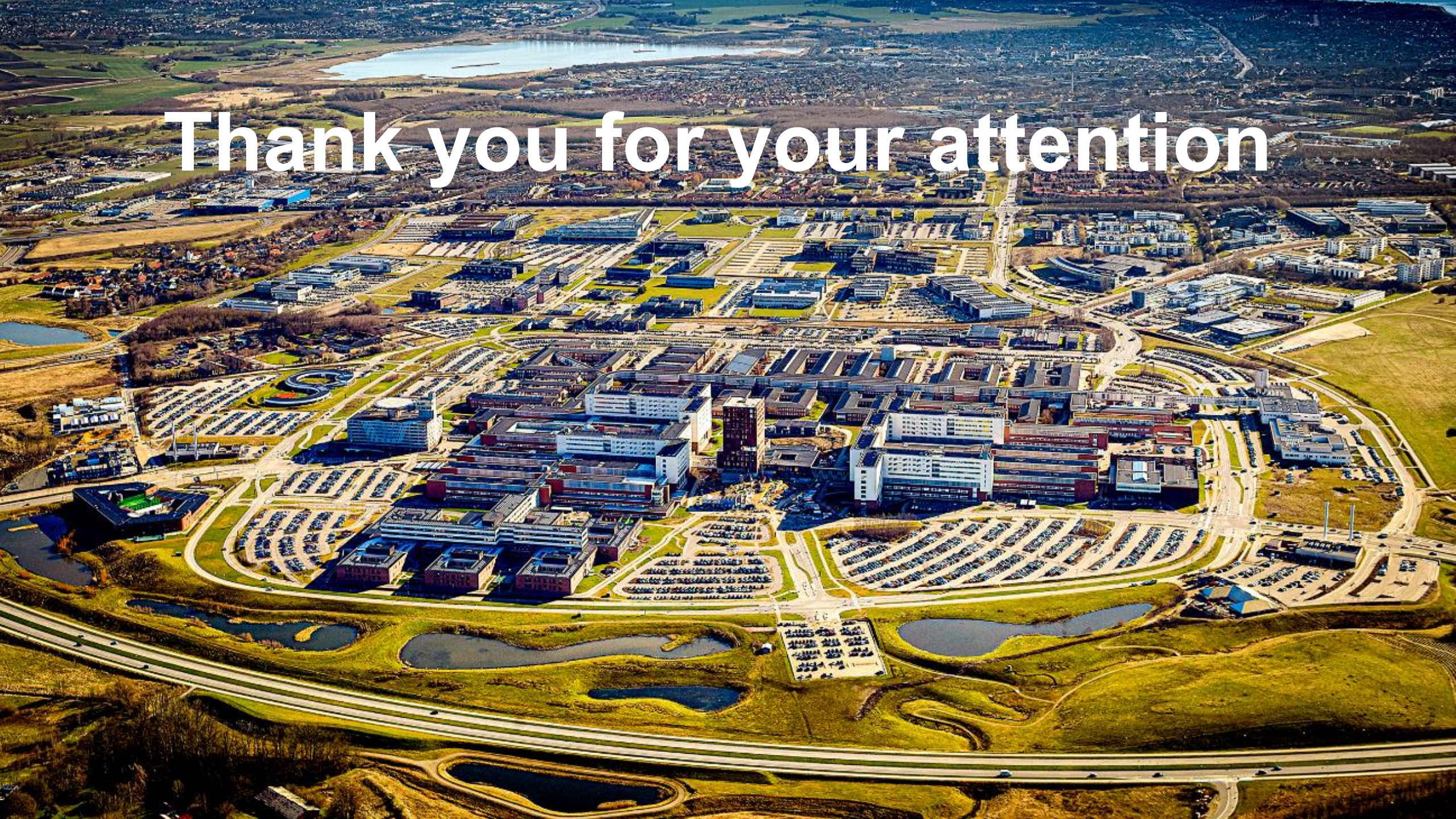

Employees at Departments of Ophthalmology in Denmark

- Nurses, RN
- Ophthalmologists
- Optometrists (Master in Optometry and Visual Science)
- Orthoptists (strabismus therapists)
- Social and health assistants
- Photographers
- Medical students



Thank you for your attention



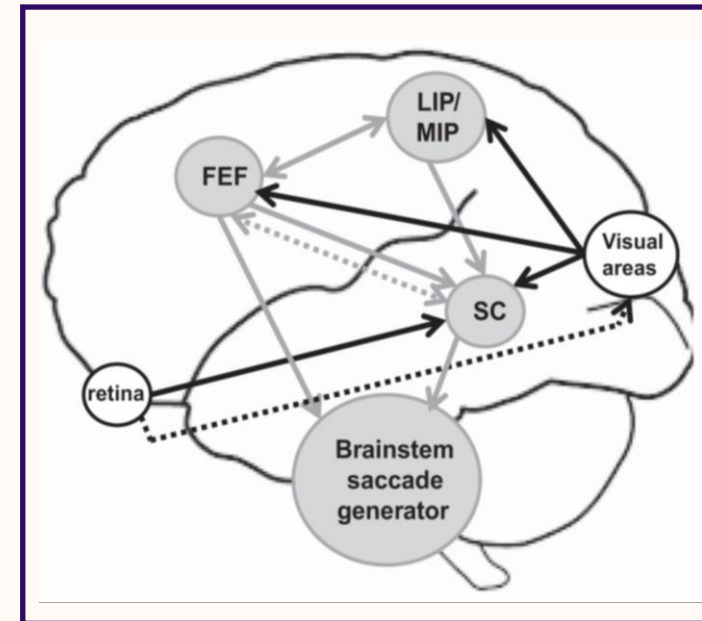
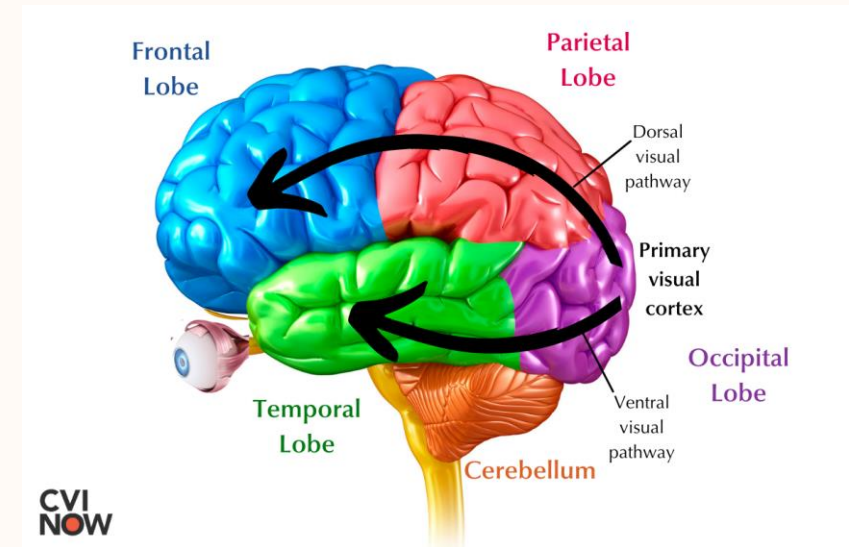
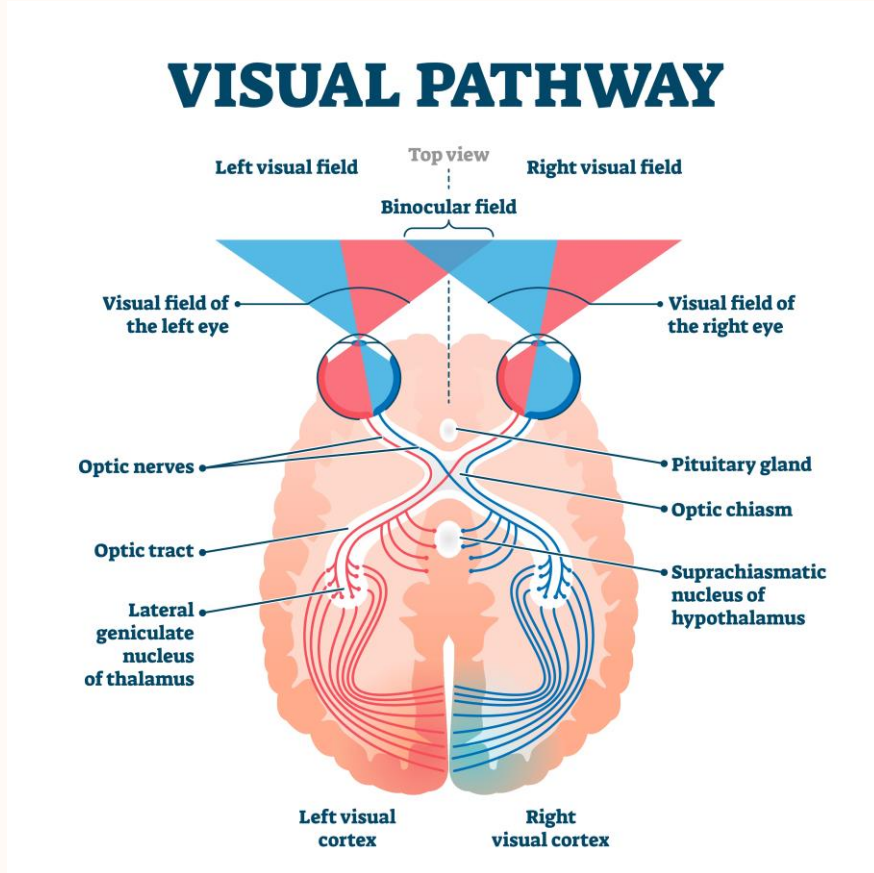
Visual problems after stroke

Associate professor Torgeir Solberg Mathisen

National Centre for Optics, Vision and Eye Care, Coordinator Norwegian Vision in Stroke (NorVIS) network

Professor Helle K. Falkenberg, National Centre for Optics, Vision and Eye Care

We see with our brain



FEF – frontal eye field
LIP/MIP - lateral and medial intraparietal cortex
SC – superior colliculus.
Caruso et al., 2018

RESEARCH ARTICLE

High incidence and prevalence of visual problems after acute stroke: An epidemiology study with implications for service delivery

Fiona J. Rowe^{1*}, Lauren R. Hepworth¹, Claire Howard¹, Kerry L. Hanna¹, Christopher P. Cheyne², Jim Currie³

¹ Department of Health Services Research, University of Liverpool, Liverpool, United Kingdom, ² Department of Biostatistics, University of Liverpool, Liverpool, United Kingdom, ³ Vision and Stroke Patient and Public Group (VISable), University of Liverpool, Liverpool, United Kingdom

* rowef@liverpool.ac.uk

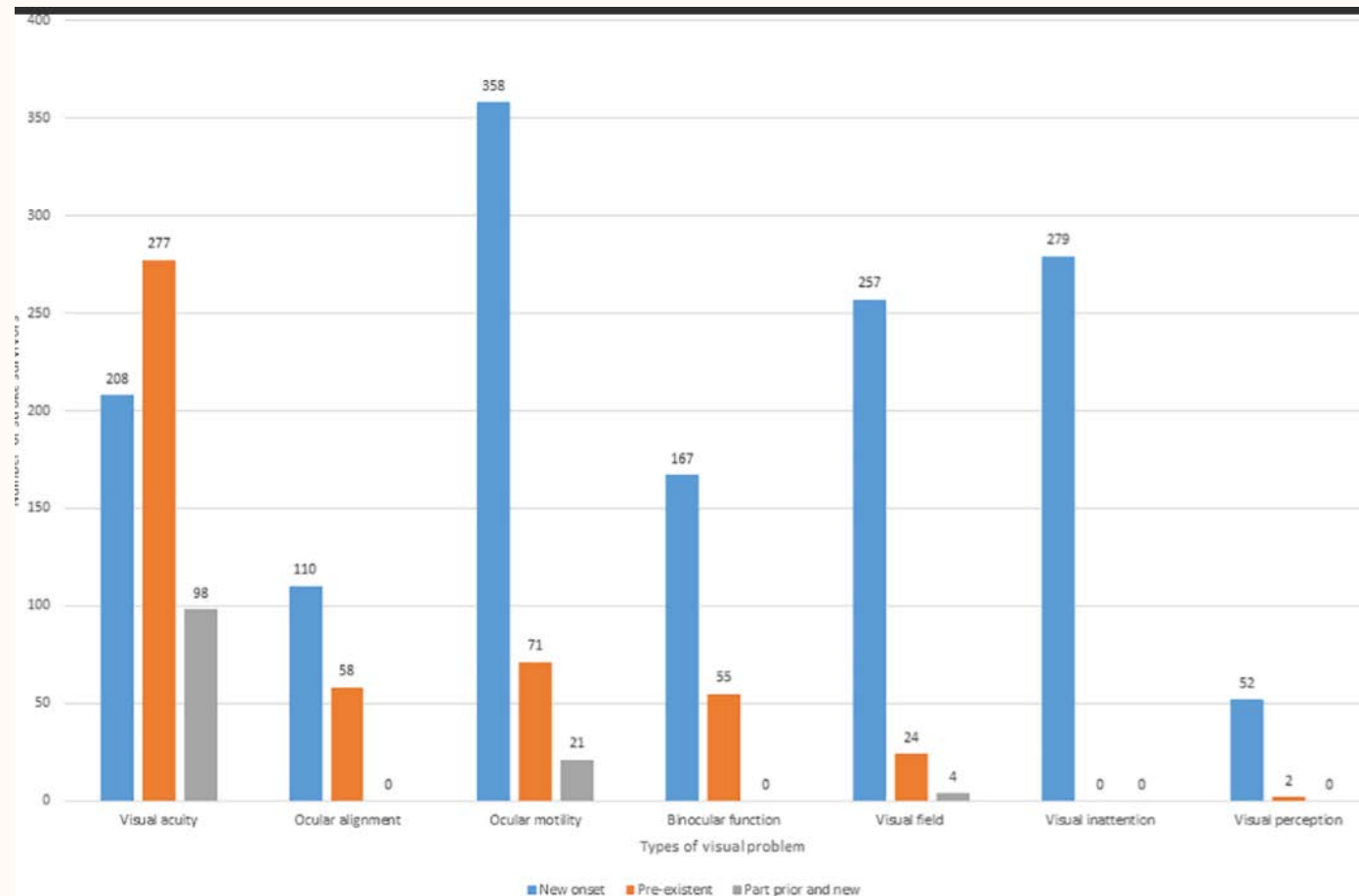
Abstract

Background

Visual problems are an under-reported sequela following stroke. The aim of this study is to report annual incidence and point prevalence of visual problems in an acute adult stroke population and to explore feasibility of early timing of visual assessment.

Methods and findings

Multi-centre acute stroke unit, prospective, epidemiology study (1st July 2014 to 30th June 2015). Orthoptists reviewed all patients with assessment of visual acuity, visual fields, ocular alignment, ocular motility, visual inattention and visual perception. 1033 patients underwent visual screening at a median of 2 days (IQR 2) and full visual assessment at a median of 4



Vision problems are common after stroke

- Norway 12 000 stroke cases per year (36/day)
- 7 000 persons per year (20/day) experience vision problems

53%

Dobbeltsyn gjør lesing vanskelig og slitsomt. Det er forvirrende at ord går i lave og høye. Det kan komme i mange ulike former.


30%

31%

32.9%

73%

Sansetap.no

A photograph of an elderly woman with short, wavy grey hair, looking out a window. She is wearing a blue patterned top and has a small hoop earring. Her hand is resting on the window frame. The window has multiple panes and is slightly fogged or dirty. The lighting is soft and natural, coming from the window.

***“Sometimes when things
turn bad, I really just want to
take a pill and be done with
it. Not having to struggle
with everything... for
example, paying the bills.
It feels hopeless.
I have tried for a long period,
but I can’t get the numbers
right....***

Falkenberg, Mathisen, Ormstad & Eilertsen, 2020

Post stroke vision problems are underreported by patients


Received: 17 February 2020 | Revised: 21 October 2020 | Accepted: 28 October 2020

DOI: 10.1002/brb3.1958

ORIGINAL RESEARCH

Brain and Behavior  WILEY

How to assess visual function in acquired brain injury—Asking is not enough

Märta Berthold-Lindstedt¹  | Jan Johansson² | Jan Ygge² | Kristian Borg¹

¹Division of Rehabilitation Medicine, Department of Clinical Science, Karolinska Institute, Danderyd University Hospital, Stockholm, Sweden

²Eye and Vision, Department of Clinical Neuroscience, Karolinska Institute, Stockholm, Sweden

Correspondence

Märta Berthold-Lindstedt, Division of Rehabilitation Medicine, Department of Clinical Science, Karolinska Institute, Danderyd University Hospital, SE 182 57 Danderyd, Sweden.
Email: marta.berthold-lindstedt@ki.se

Funding information

The County Council of Stockholm; The

Abstract

Background: Acquired brain injury affects many brain areas and causes a range of dysfunctions including vision-related issues. These issues can have negative impacts on rehabilitation progress and activities of daily life but may easily be overlooked. There is no common recommendation about how to assess visual impairments after ABI. The purpose of this study was to estimate the frequency of objectively measures oculomotor dysfunctions, and also how these findings are related to two inventories intended to support detection of visual impairment.

Methods: The study was cross-sectional and included 73 outpatients. In addition to the standard evaluation program, the patients went through a comprehensive optometric examination. The inventories used were the Vision Interview (VI) and the Convergence Insufficiency Symptom Survey (CISS).

“Eye” Don't See: An Analysis of Visual Symptom Reporting by Stroke Survivors from a Large Epidemiology Study

Lauren R Hepworth, PhD • Claire Howard, PhD • Kerry L Hanna, PhD • Jim Currie • Fiona J Rowe, PhD  

Published: April 01, 2021 • DOI: <https://doi.org/10.1016/j.jstrokecerebrovasdis.2021.105759>

Abstract

Aim

The purpose was to explore the reported symptoms of post-stroke visual impairment in a large epidemiology study.

Methods

Visual assessment, including a case history, visual acuity, ocular alignment



40 KR 2 FOR 40 KR



2 FOR 40 KR



2 FOR 40 2 FOR 40 KR



2 FOR 40 2 FOR 40 KR



R Gjelde ikke 2 for 40r 2 FOR 40 KR



R Gjelde ikke 2 for 40r 2 FOR 40 KR



Vision needs to be assessed

“Yeah, they—maybe they primarily do not have it in their checklist. Because it should be just as important to check your vision as it is to check if your arm works or not! But if your eyes work? Not at all! It is not even on their list!”

RESEARCH ARTICLE

Open Access

“Invisible” visual impairments. A qualitative study of stroke survivors` experience of vision symptoms, health services and impact of visual impairments



Helle K. Falkenberg^{1,2*}, Torgeir S. Mathisen^{1,2}, Heidi Ormstad³ and Grethe Eilertsen^{2,3}

Abstract

Background: Visual impairments (VIs) have a negative impact on life and affect up to 60% of stroke survivors. Despite this, VIs are often overlooked. This paper explores how persons with VIs experience vision care within stroke health services and how VIs impact everyday life the first 3 months post stroke.

Methods: Individual semi-structured interviews were conducted with 10 stroke survivors 3 months post stroke, and analyzed using qualitative content analysis.

Results: The main theme, “Invisible” visual impairments, represents how participants experience VIs as an unknown and difficult symptom of stroke and that the lack of attention and appropriate visual care leads to uncertainty about the future. VIs were highlighted as a main factor hindering the participants living life as before. The lack of acknowledgement, information, and systematic vision rehabilitation leads to feelings of being unsupported in the process of coping with VIs.

Conclusion: VIs are unknown symptoms pre stroke and sequelae after stroke that significantly affect everyday life. VIs and vision rehabilitation needs more attention through all phases of stroke health services. We request a greater awareness of VIs as a presenting symptom of stroke, and that visual symptoms should be included in stroke awareness campaigns. Further, we suggest increased competence and standardized evidence-based clinical pathways for VIs to advance all stroke health services including rehabilitation in order to improve outcomes and adaptation to future life for stroke survivors with VIs.

Keywords: Rehabilitation, Qualitative research, Municipal- and specialist health care services, Health care professionals, Vision

ASSESSMENT OF VISUAL PROBLEMS AFTER ACQUIRED BRAIN INJURY: A SURVEY OF CURRENT PRACTICE IN DANISH HOSPITALS

Trine SCHOW, PhD^{1,2}, Eike Ines WEHLING, PhD^{3,4}, Helle K. FALKENBERG, PhD⁵, Anne NORUP, PhD^{1,6}, and Karin Spangsberg KRISTENSEN, MPH¹

From the ¹Neurorehabilitation Research and Knowledge Centre, Rigshospitalet, Copenhagen, Denmark, ²Neurorehabilitation-Cph, Copenhagen, Denmark, ³Department of Biological and Medical Psychology, University of Bergen, Bergen, Norway, ⁴Department of Physical Medicine and Rehabilitation, Haukeland University Hospital, Bergen, Norway, ⁵Department of Optometry, Radiography and Lighting Design, University of South-Eastern Norway, Notodden, Norway, and ⁶Department of Neuroscience, University of Copenhagen, Copenhagen, Denmark

Objectives: To explore current hospital practice in relation to the assessment of vision problems in patients with acquired brain injury.

Design: A survey study.

Subjects: A total of 143 respondents from hospital settings, with background in occupational therapy and physical therapy, participated in the survey.

Methods: The survey questionnaire, developed collaboratively by Danish and Norwegian research groups, encompassed 22 items categorically covering "Background information", "Clinical experience and current practice", "Vision assessment tools and protocols", and "Assessment barriers". It was sent out online, to 29 different hospital departments and 18 separate units for occupational therapists and physiotherapists treating patients with acquired brain injury.

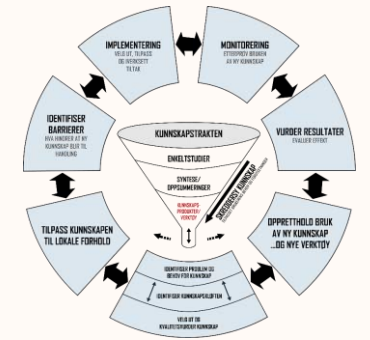
Results: Most respondents worked in acute or sub-acute hospital settings. Few departments had an interdisciplinary vision team, and very few therapists had formal education in visual problems after acquired brain injury. Visual assessment practices varied, and there was limited use of standardized tests. Barriers to identifying visual problems included patient-related challenges, knowledge gaps, and resource limitations.

LAY ABSTRACT

Vision problems are common after acquired brain injury, but no clear national guideline in Denmark exists in relation to assessing vision problems. This study looked at how therapists identify vision problems in patients who have acquired a brain injury. We surveyed 143 therapists working in hospitals. Interestingly, only a few had a practical guideline for how to do the assessment. Moreover, very few worked in teams, and therapists did not have much formal training on these problems. Therapists had different ways of assessing patients' vision, and some faced challenges like not having enough knowledge or resources. The study suggests that better interdisciplinary teamwork is needed, more education, and common ways of checking vision problems after a brain injury to improve how we treat patients with vision problems in Denmark.

(2), healthcare professionals, and society (3–6). Various aspects of visual processing lead to a wide range of visual impairments (7), including reduced visual acuity, visual field defects, oculomotor dysfunction, binocular vision abnormalities, and higher-level visual


The KROSS KTA project



ISN Universitetet i Sørøst-Norge

Bakgrunnsinformasjon		Dato for testing:	Tid siden hjerneslaget:
Navn:		Diagnose (hvis kjent):	
Fødselsdato:			
Opplysninger om syn og symptomer			
1. Tidligere kjent med	a. på størrelse med en myse b. enn glaukoma c. FAMILIE	JA	NEI
2. Bruker personlig	a. gjenstander b. gjenstander c. gjenstander	JA	NEI
3. Opplever selv endring i synet etter hjerneslaget?	Hvis ja, spesifiser:		
4. Har familie/ fagpersoner rapportert endring i synet etter hjerneslaget?	Hvis ja, spesifiser:		
Skarp syn/ Visus/ Sentralsyn			
5. Ser selv uklart/tåketete etter slaget	På nært (lesing)/ på avstand (tv)		
6. Synsskarphet på avstand (3 m)	Kan se minst tre bokstaver på øverste linje (0,3 visus) -Hvis ja, test midterste linje	Høyre	Venstre
Utført med / uten brille	Kan se minst tre bokstaver på midterste linje (0,5	Høyre	

KROSS



ISN Universitetet i Sørøst-Norge

Bakgrunnsinformasjon		Dato for testing:	Tid siden hjerneslaget:
Navn:			
Fødselsdato:		Diagnose (hvis kjent):	

Opplysninger om syn og synssymptom (marker)		JA	NEI
1. Tidligere kjente øyesykdommer	a. Grå stær/katarakt b. Grønn stær/glaukom c. Forkalkning/AMD d. Annet		
2. Bruker personen briller	a. Avstands-/tv-/kjørebrille b. Lesebrille c. Flerstykke/progressiv d. Egen brille er ikke tilgjengelig e. Kontaktlinser f. Lupebrille		
3. Opplever selv endring i synet etter hjerneslaget?	Hvis ja, spesifiser:		
4. Har familie/ fagpersoner rapportert endring i synet etter hjerneslaget?	Hvis ja, spesifiser:		

Skarpsyn/ Visus/ Sentralsyn (marker)		JA	NEI
5. Ser selv uklart/tåketete etter slaget	På nært (lesing)/ på avstand (tv)		
6. Synsskarphet på avstand (3 m)	Utført med / uten brille Test ett øye om gangen med tv/avstandsbrille om personen bruker dette.	Høyre Venstre	
7. Kan lese avistekst	Utført med / uten lesebrille (begge øyne)	Høyre Venstre	

Synsfelt (marker)		JA	NEI
8. Opplever selv mangler i synsfeltet ei	Hvis ja, spesifiser:		
9. Observasjon av orienteringsvansker	Hvis ja, spesifiser:		
10. Synsfelt yttergrenser	Er det utfall i deler av synsfeltet? Test ett øye om gangen uten brille.	VØ HØ VØ HØ	
11. Sentralt synsfelt	Er det utfall i sentralsynet? a. ansiktsansler (ett øye om gangen) b. fingertelling (begge øyne)	VØ HØ VØ HØ	

Skjema er utviklet i prosjektet «Et slag for syn» i Kongsberg kommune, og må tilpasses lokale forhold. Informasjon til bruker: Du har fått en enkel kartlegging og informasjon av synet ditt. Du bør ta med en kopi som informasjon i eventuell videre rehabilitering. Kartleggingen erstatter ikke en full synsundersøkelse, og garanterer ikke at alle typer synsproblem avdekkes. Merker du endringer i synet, kontakt din lokale optiker eller øylege. V3.0 2023

ISN Universitetet i Sørøst-Norge

Samsyn og øyebevegelse (marker)		JA	NEI
12. Opplever selv dobbeltsyn	Hvis ja, spesifiser:		
13. Opplever problemer med dybdesynet	Hvis ja, spesifiser:		
14. Skjeler på ett øye	Spesifiser øye og retning	Høyre øye Venstre øye	Ut til siden Oppover Nedover
15. Unormale øyebevegelser	Spesifiser hvor det er problemer med å følge blikket fullt og jevnt til sin høyre eller venstre side, opp eller ned	Uten brille, med begge øyne	Mot høyre Mot venstre

Redusert oppmerksomhet (neglekt) (marker)		JA	NEI
16. Mistanke om redusert oppmerksomhet	Antall hele hjertes <u>avkrysset</u> /50	Tid (min): (Maks 3 min)	
Hjertetesten: færre enn 42 av 50 avkrysset	Sideforskjell (tre eller flere hjertes): H / V Antall hele hjertes markert i de fire venstre boksene minus antall hele hjertes i de fire boksene til høyre.		
Annent test er brukt	Spesifiser test:		

Resultat (marker)		JA	NEI
17. Det er identifisert et synsproblem	Hvis ja, spesifiser:	Synsskarphet Redusert oppmerksomhet	Synsfelt Samsynsproblem
18. Det er behov for videre utredning/oppløsing/synsrehabilitering/synsundersøkelse	Hvis ja, spesifiser:		

Kryss nei, om synsproblemet er kjent fra tidligere og ivarett.

Informasjon (marker)		JA	NEI
Personen har fått informasjon om førerkort og bilkjøring			
Personen er informert om resultatet av KROSS kartleggingen			
Pårørende er informert om resultatet av KROSS kartleggingen			
Personen er informert om å kontakte optiker/fastlege/øylege hvis de senere opplever synsproblemer (f.eks. lese/tv/mobilisering)			

Andre kommentarer:

Skjema er utviklet i prosjektet «Et slag for syn» i Kongsberg kommune, og må tilpasses lokale forhold. Informasjon til bruker: Du har fått en enkel kartlegging og informasjon av synet ditt. Du bør ta med en kopi som informasjon i eventuell videre rehabilitering. Kartleggingen erstatter ikke en full synsundersøkelse, og garanterer ikke at alle typer synsproblem avdekkes. Merker du endringer i synet, kontakt din lokale optiker eller øylege. V3.0 2023



Veileder KROSS Kartleggingsskjema for syn



Tolkning av skjema: JA svar er som oftest relatert til redusert synsfunksjon med behov for videre oppfølging bortsett fra testing av synsskarphet (visus). Dersom noen punkter ikke undersøkes, bør årsaken spesifiseres.

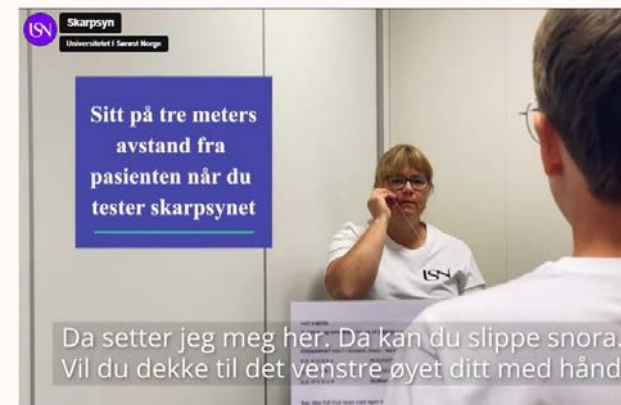Bakgrunnsinformasjon

Angi dato og personens fødselsår. Ring rundt det som beskriver personen, kjønn, diagnose og NIHSS resultat (vis tilgjengelig). KROSS bruker «person» for å beskrive den som testes (pasient/bruker) i helse-, omsorg- eller opplæringsstjeneste.

Opplysninger om syn og synssymptom

- Tidligere kjente øyesykdommer**
Utførelse: Spør personen/pårørende om tidligere kjente øyesykdommer.
«Har du fått beskjed om at du har en øyesykdom som f.eks. grå stær (katarakt), grønn stær (glaukom) eller forkalkning (aldersrelatert makuladegenerering, AMD)? Får du behandling med øyedråper av noe slag?»
Dokumentasjon: Ring rundt ett / flere alternativer. Ved annet, skriv diagnose om den er kjent (f.eks. tørre øyne, diabetes retinopati, øyeoperasjon, øyeskade eller liknende).

2. Bruker person briller



Assessing barriers

Mathisen et al. *BMC Health Services Research* (2021) 21:497
<https://doi.org/10.1186/s12913-021-06467-4>

BMC Health Services Research


RESEARCH ARTICLE

Open Access

Barriers and facilitators to the implementation of a structured visual assessment after stroke in municipal health care services



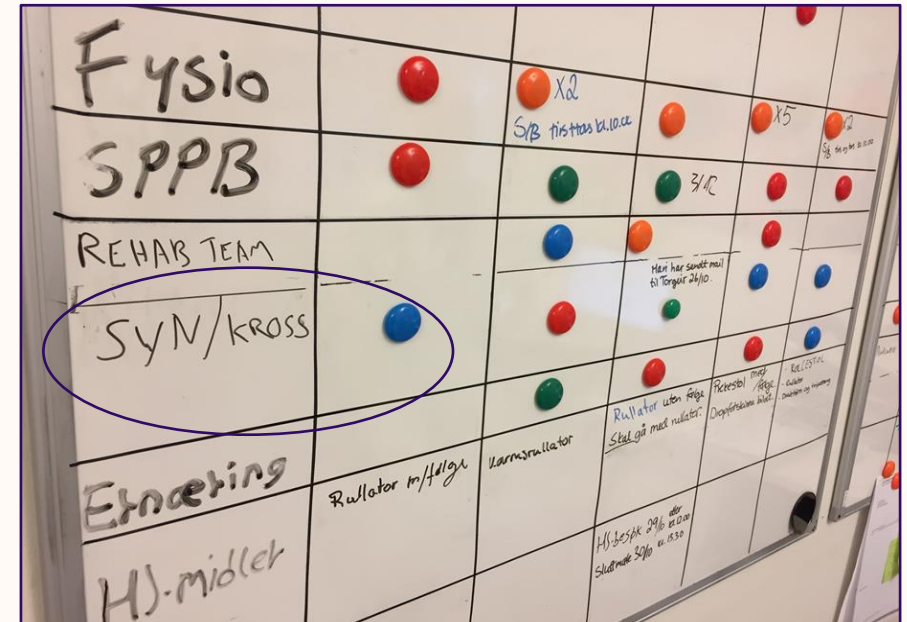
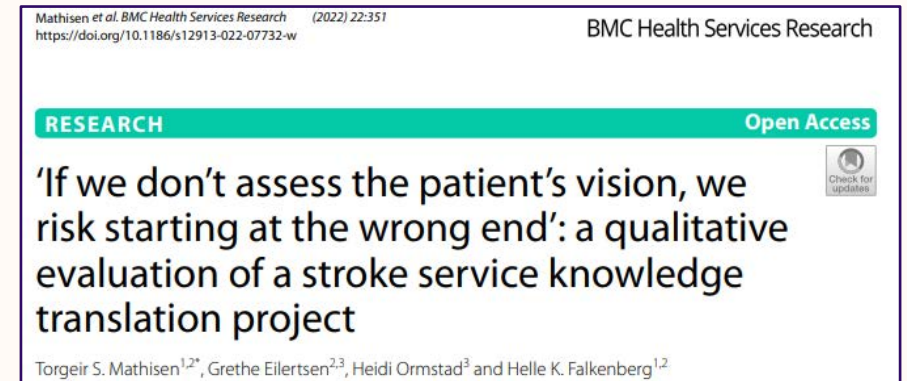
Torgeir S. Mathisen^{1,2*}, Grethe Eilertsen^{2,3}, Heidi Ormstad⁴ and Helle K. Falkenberg^{1,2}



“We got a note from the ophthalmologist, but I did not understand a thing. And I dont think its just me. Its all Greak to me, reading such (vision) reports. Just numbers and letters and some crazy words.»

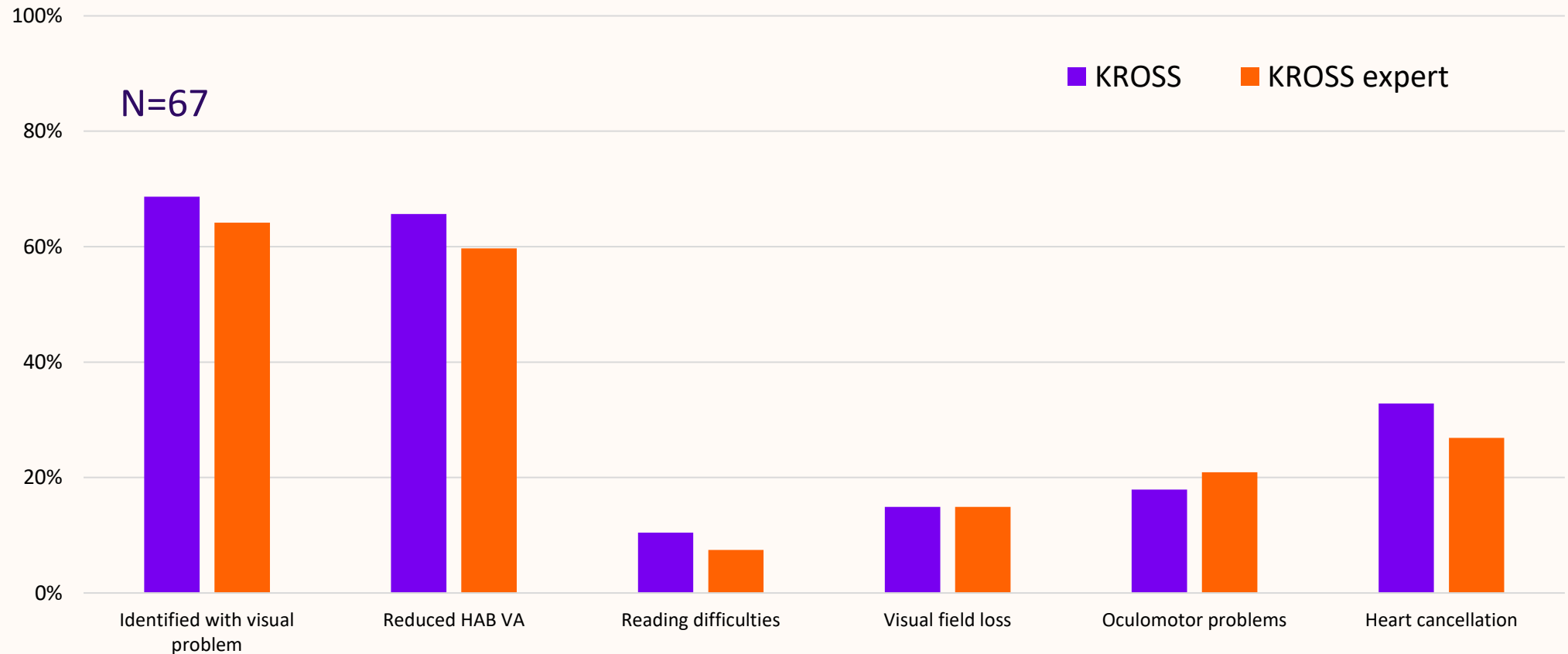
What we learned so far

“Before the KROSS workshop, I did not know anything about VIs after a stroke. I knew it existed, but in my education, we did not learn anything about it.”



Falkenberg, Mathisen, Ormstad & Eilertsen, 2020

KROSS can identify visual problems


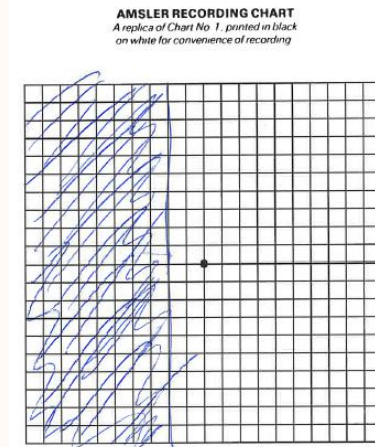
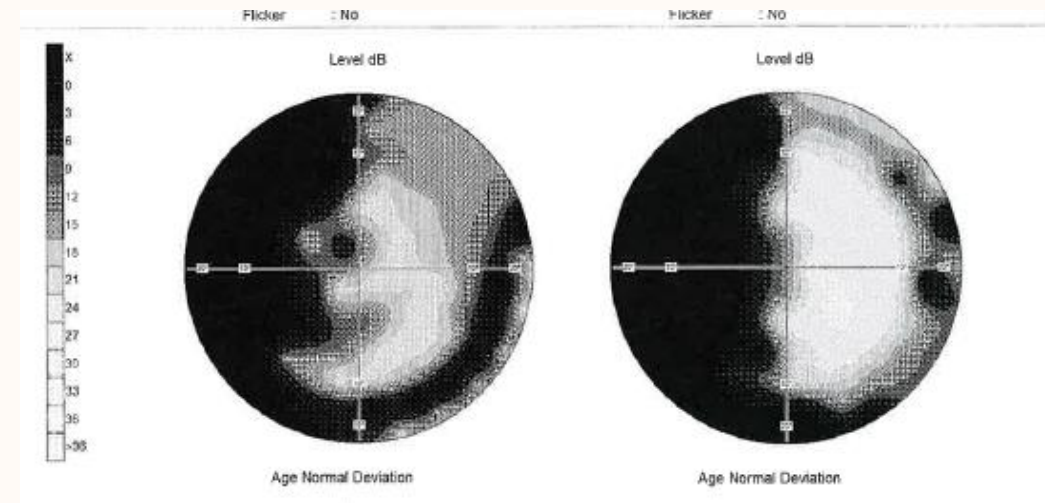


Visual rehabilitation

- Restitution
- Compensation
- Substitution
- Coping in a new situation

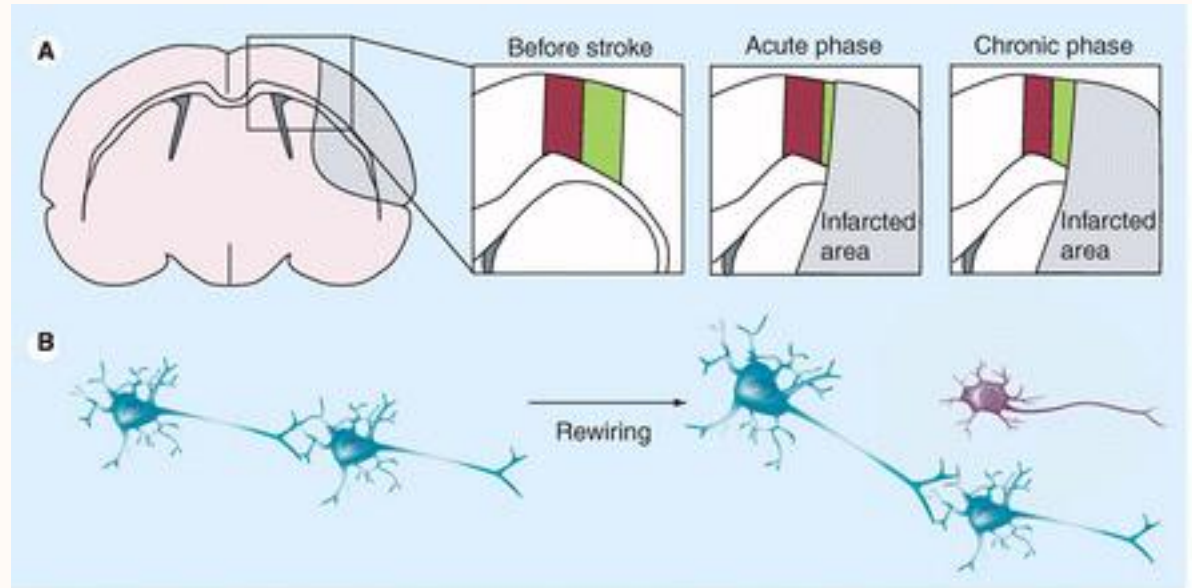
Venstre øye

Høyre øye



Restitution

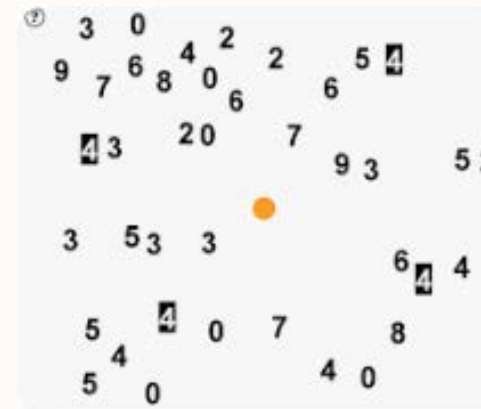
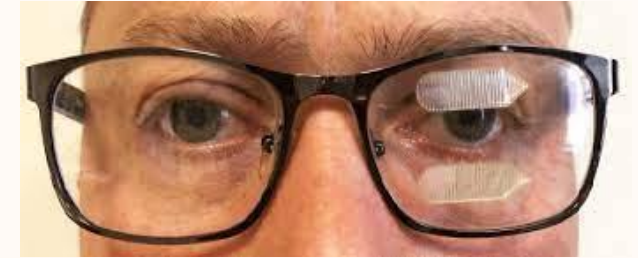- Builds on the principles of the plasticity of the brain
- Eye movements
- Visual field
- Spontaneous restitution



(Smedslund and Myrhaug 2017, Pollock, Hazelton et al. 2019, Taraldsen 2023)

Compensation

- Optimize the visual function
- Improve search strategies in small and large visual field
- Prisms



(Zihl 2011, Pollock, Hazelton et al. 2019)

Synsrehabilitering på Vikersund Bad Rehabiliteringssenter

Torgeir Mathisen · Siste rytt | May 10, 2022



Substitution

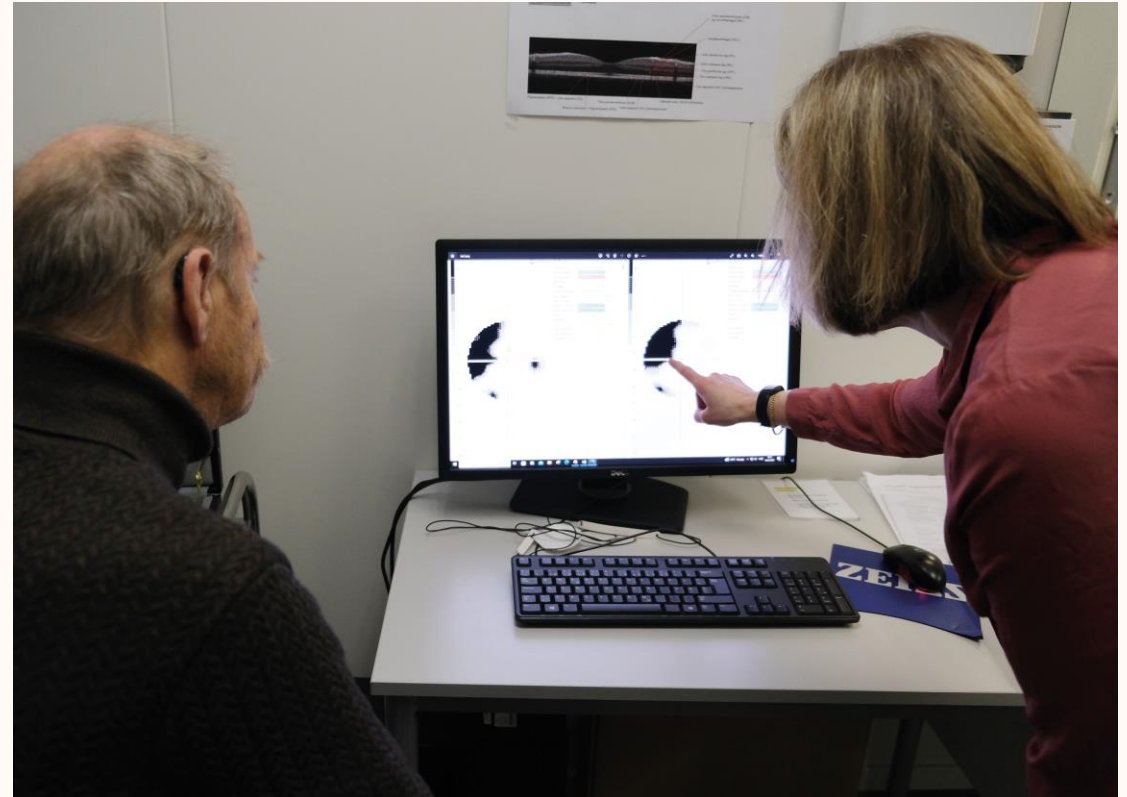
- Optics for visually impaired
- Magnifying
- Lighting



ADAM.

Coping with a new way of seeing

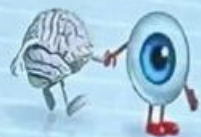- Understanding the visual problem
 - Patient
 - Caregivers
 - Health care personell
- Consequenses of impaired vision
 - Promote activity and participation
 - Coping



StrokeVIS

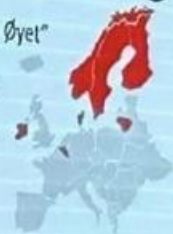

"Øyet I Slaget"



TenCRAOS

"Slag I Øyet"



- 🧠 Anne-Hege Aamodt
- 👁️ Fiona Rowe
- 👁️ Morten Carstens Moe
- 👁️ Øystein Kalnes Jørstad
- 🧠 Mona Skjelland
- 👁️ Anna-Katharina Lizten Jørstad
- 🧠 Ansar Roy
- ... og mange flere!


Norges Blindeforbund
Synshemmedes organisasjon

HELSE SØR-ØST

Oslo University Hospital

KLINBEFORSK






NorVIS
Norwegian Vision in Stroke



Plutselig problem med å

**PRATE
SMILE
LØFTE
SE**

må du ringe 113!



STORTINGET.NO
Representantforslag om en enklere hverdag for synshemmede

LHL Hjerneslag og Afasi

Norges Blindeforbund
Synshemmedes organisasjon

Norsk forening
for slagnesår

JOHANNES LÆRINGSSENTER

MOLDE KOMMUNE

Oslo

TRONDHEIM
KOMMUNE

Støttet av
Forskningsrådet

FINNMARKSSYKEHUSET
FINNMÁRKKU BUOHCCIVIESSU

Displass
Sykehus

TRONDHEIM
Sykehus

HELSE FØRDE

Lovisenberg Diakonale Sykehus

NASJONAL BEHANDLINGSTJENESTE
for helse og psykisk helse

SYKEHUS

HOSPITAL
I TRONDHEIM

SYKEHUS

SYKEHUSET I VESTFOLD

SØRLANDET SYKEHUS

unicare

VESTRE VIKEN

Vikersund Bad
REHABILITERINGSSENTER AS



NORGES
OPTIKERFORBUND

Instituttet
for Blinde og Svagsynede

HU
UNIVERSITY OF APPLIED
SCIENCES
UTRECHT

Linnéuniversitetet

GÖTEBORGS UNIVERSITET

NTNU

UNIVERSITY OF
LIVERPOOL

USN
Universitetet
i Sørøst-Norge

**Takk
for
deltagelse
og
støtte!**



Medical glaucoma

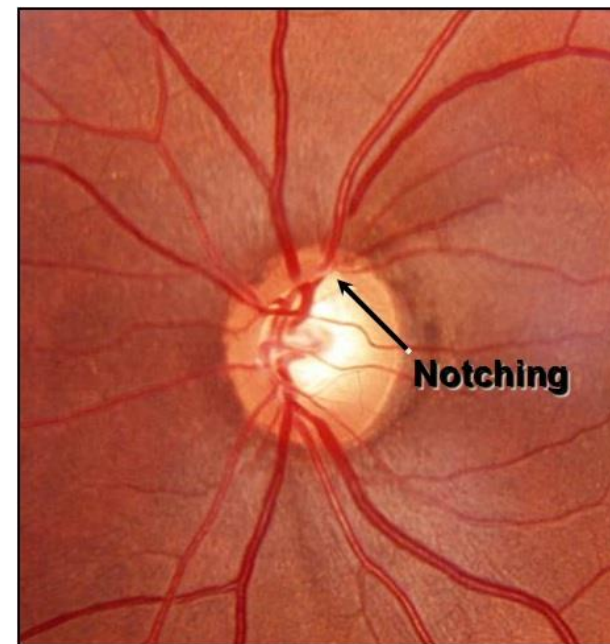
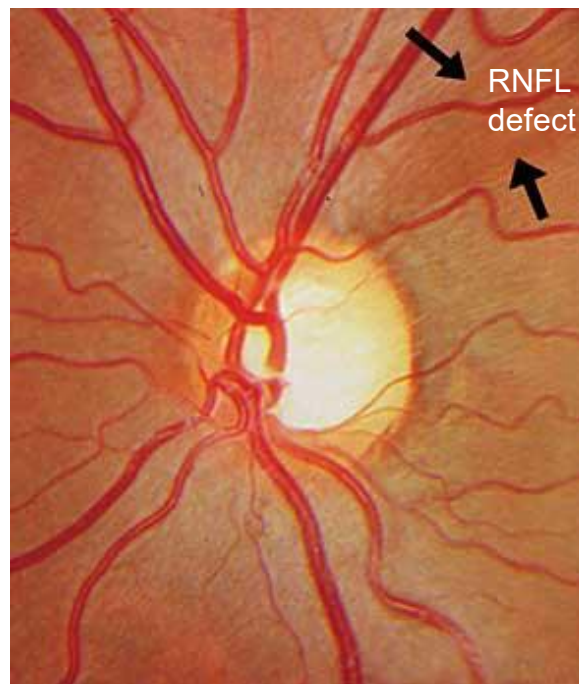
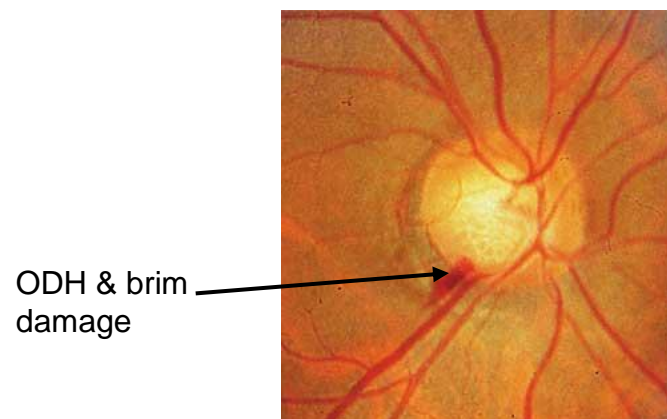
Johan Aspberg, MD, PhD

Eye department, Malmö

Definition of glaucoma

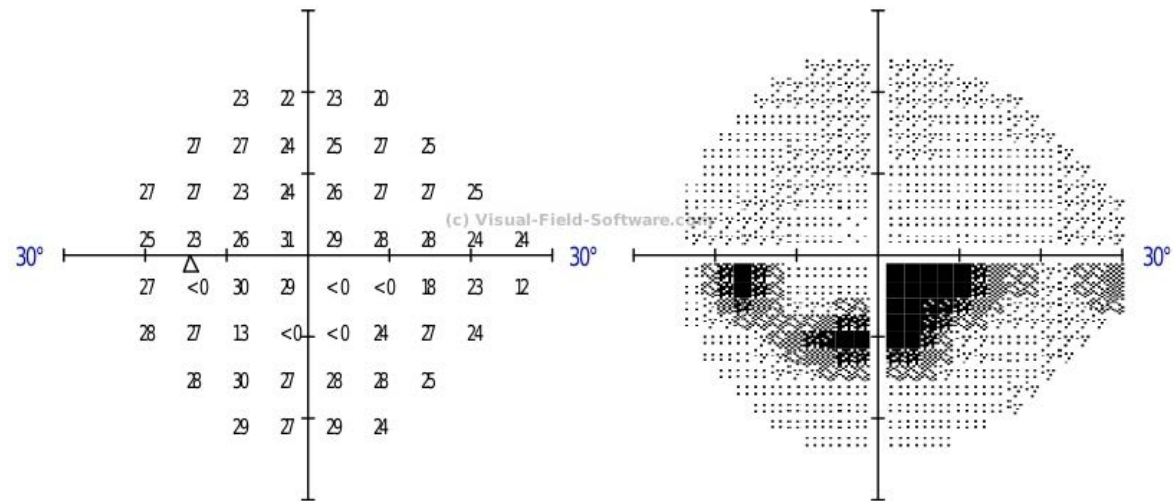
- Structure:

Typical changes of the optic nerve (thinner brim), or a nerve fibre layer defect.



- Function:

Repeated visual field defects in the same area correlating with optic nerve damage.



- The intraocular pressure (IOP) not relevant for the diagnosis
- Damage not explained by other causes than glaucoma (neurologic disease etc)

Epidemiology

- Open angle (Western world): 2% \geq 40 years
- Closed angle (Asia)

- Primary glaucoma
- Secondary glaucoma



Prevalence POAG

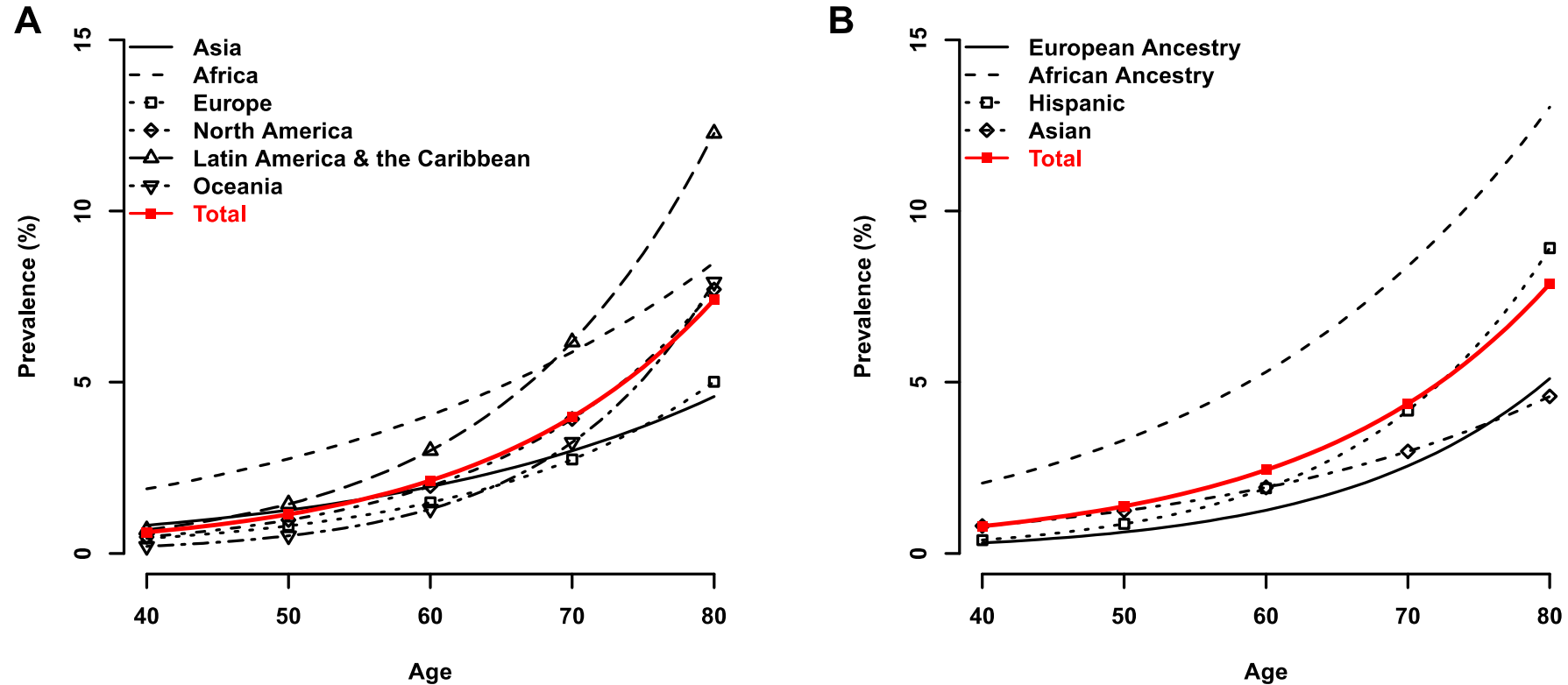


Figure 5. Age-specific prevalence of primary open-angle glaucoma (POAG) by (A) world regions and (B) ethnic groups. From Tham et. al. Ophthalmology, 2014

Types of glaucoma

Primary

- POAG (incl. PEX-glaucoma)
- PACG

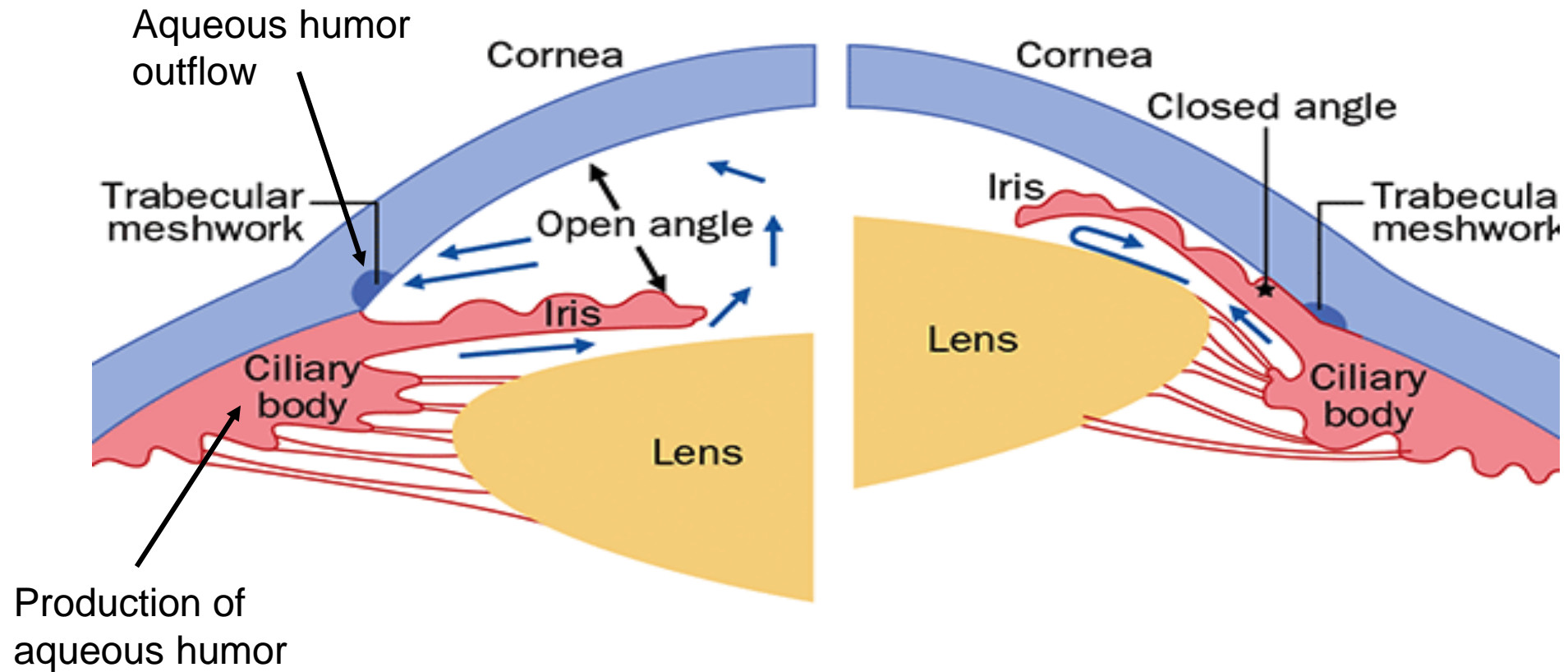
Congenital glaucoma

Secondary

- Pigmentary
- Inflammatory
- Neovascular
- Trauma
- Cortison-induced
- Other



Anterior chamber anatomy



- "Real" closed-angle glaucoma rare in Sweden.
- Acute glaucoma in Sweden has often a secondary cause (cataract, anterior synechiae of the chamber angle)

This is what happens if you dilate the pupil of a patient with elevated IOP!

Or...?

Something
is...
WRONG!!!



AAARGH!!

Treatment

- IOP-lowering eye drops
- Laser trabeculoplasty
- Surgery

Eye drops

- Most important aspect – Compliance
- Ask the patient: the name of the drops, how often, missed doses since the last visit. Side effects?

- Does the patient understand why he/she is taking the eye drops?
- Who is administering the drops? Living situation? Economic situation? Sometimes you need help from home care or a district nurse

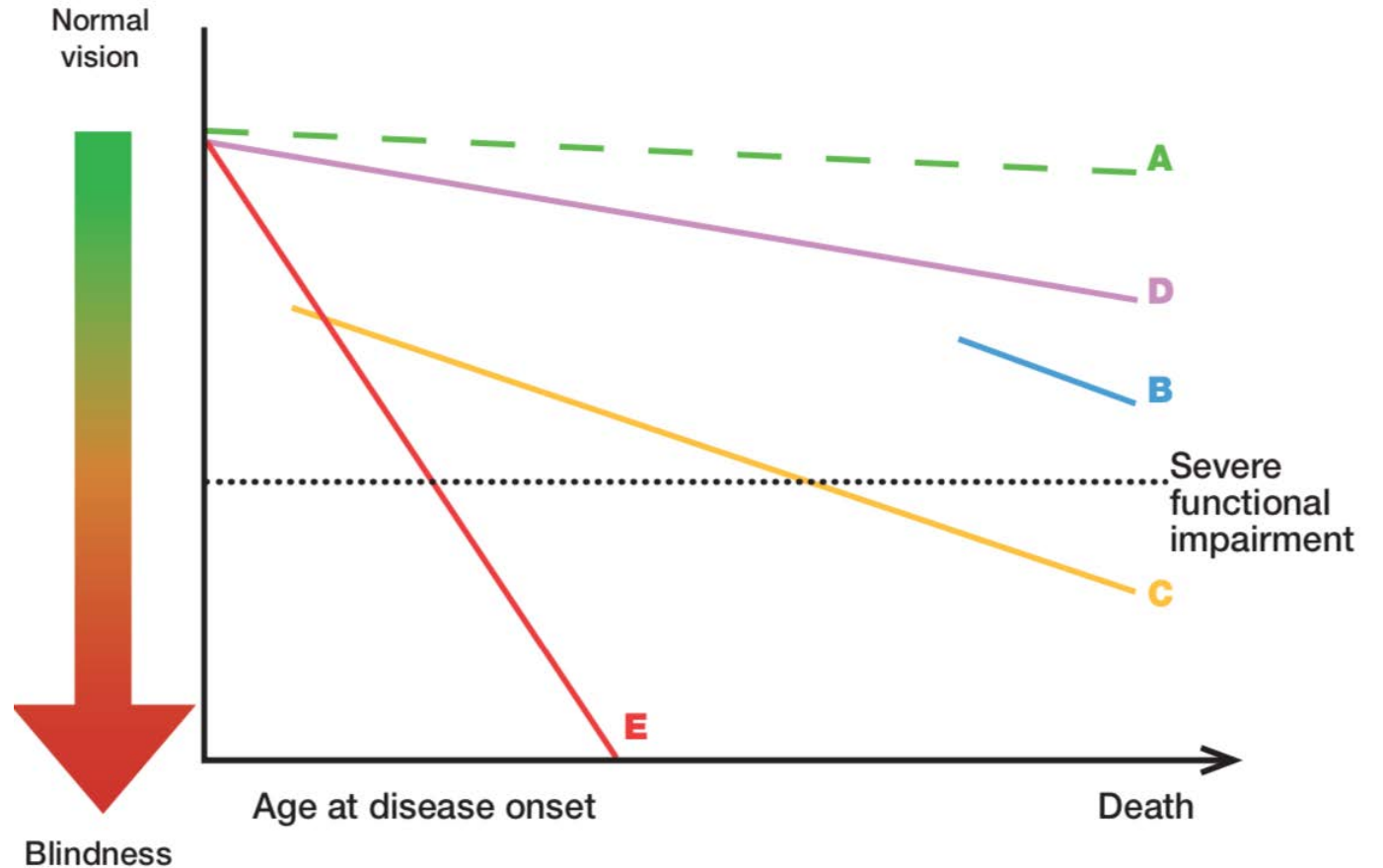
Side effects or not?

- Allergy or side effects described in the charts – is it correct? Is it really necessary to avoid the substance?
- Does the symptoms match known side effects? How long has he/she used the drops?
- Type 1-allergy uncommon, often within 2 weeks
- Common complaints: Stingy, red, dry & tired eyes.



Treatment aims

- Prevent visual impairment
- At VFI < 50% in both eyes, QoL starts to be affected
- Initial treatment is adjusted to risk factors of progression



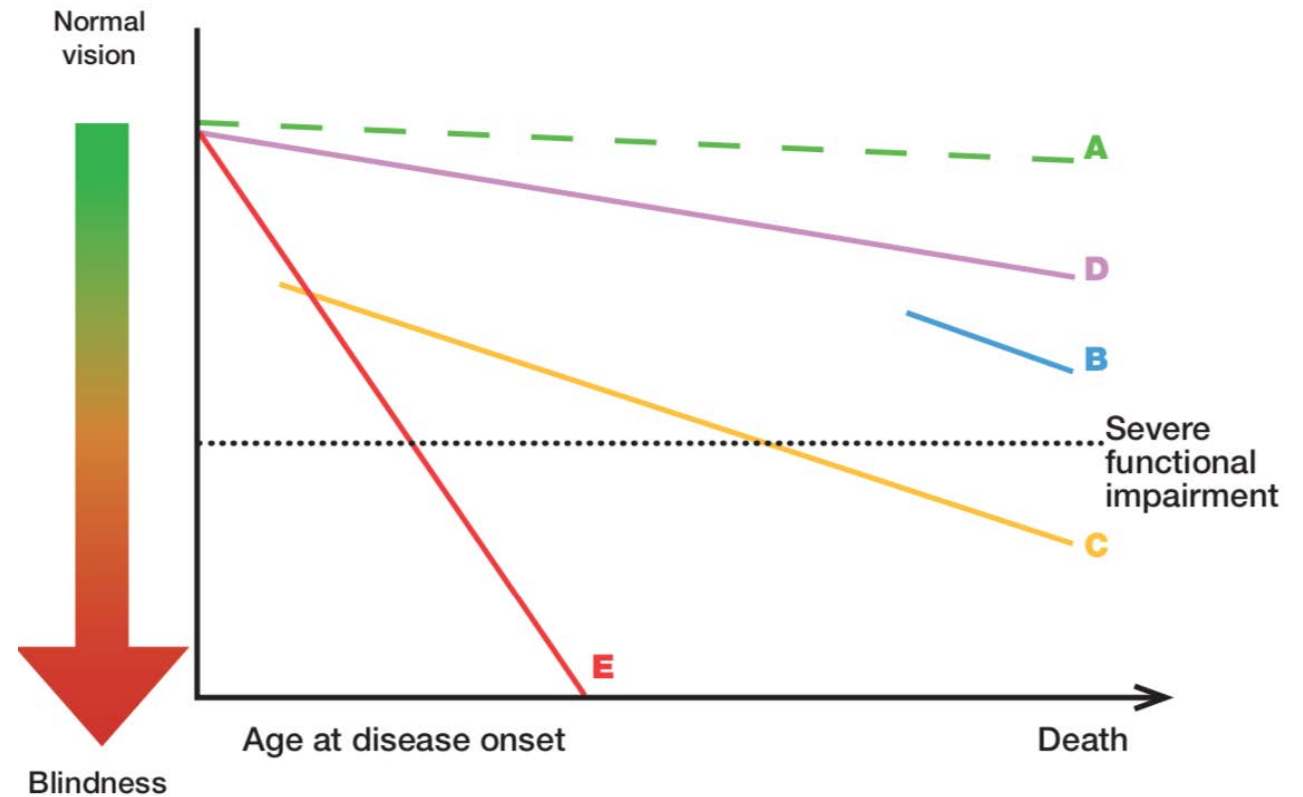
Natural history of glaucoma in the EMGT (untreated patients)

IOP <21: -0.36 MD*/year

IOP ≥21: -1.31 MD/year

PEX: -3.13 MD/year

*MD = about 3% VFI



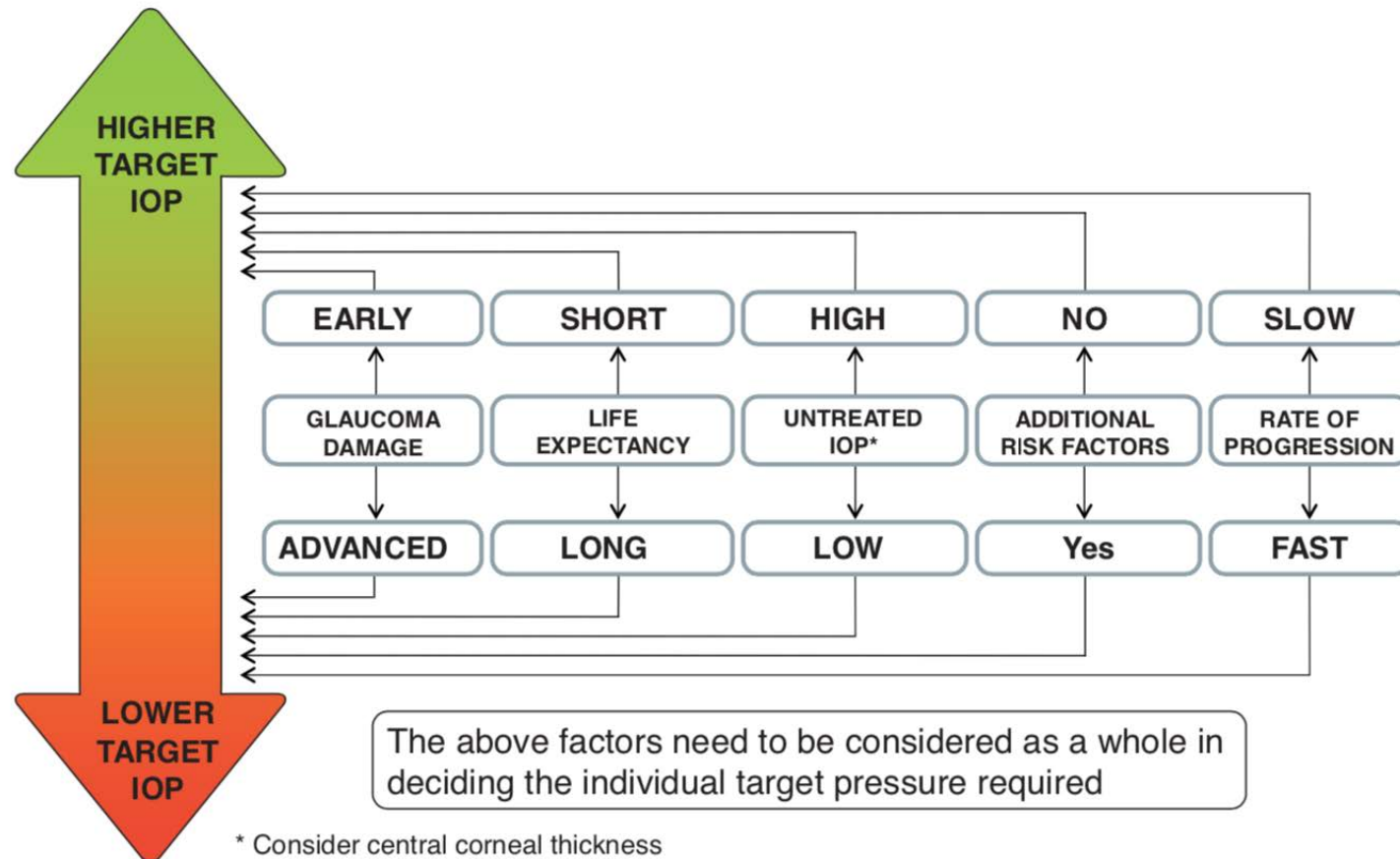
What type of patient?

- Young – Old (life expectancy)
- Untreated IOP
- PEX or pigment dispersion?
- Amount of visual field damage at diagnosis?
- Uni- or bilateral glaucoma?
- Ethnicity

Risk factors for progression - EMGT

- Age \geq 68 years Hazard Ratio (HR): 1.51
- IOP \geq 21 HR: 1.77
- PEX HR: 2.12
- Bilateral glaucoma HR: 1.88
- IOP reduction /mmHg HR: 0.92
- \uparrow mean IOP over time /mmHg HR 1.12
- Optic disc hemorrhage / % of visits HR 1.02

Target pressure



Rate of progression

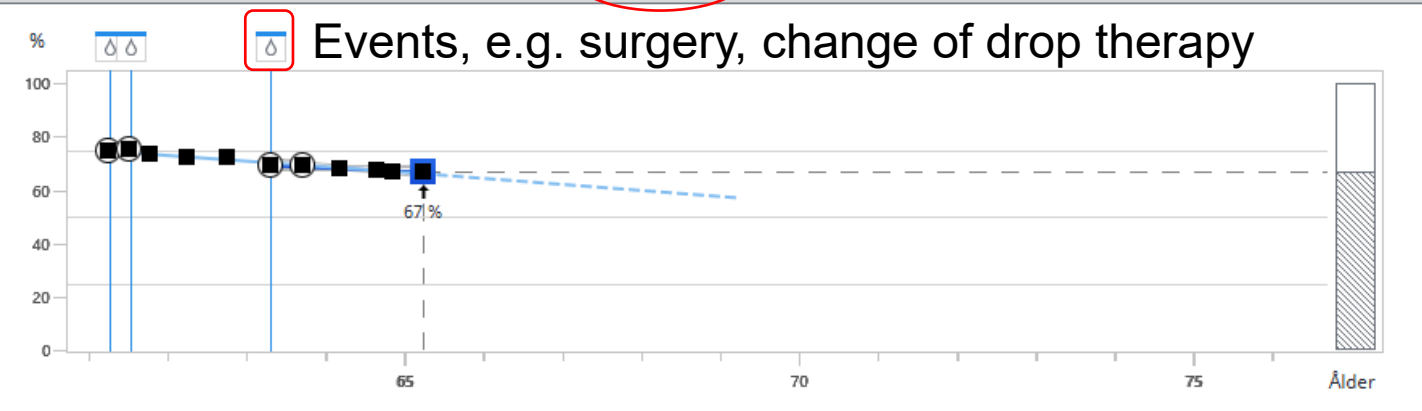
- Not possible to predict at the individual level at baseline. All glaucoma patients progress sooner or later
- A progression estimate available after 5-6 visual field tests, in 2 or 3 years. Do not use OCT!
- Progression is most often linear, related to mean IOP over time.
- Too much progression – increase treatment. New baseline.



OS

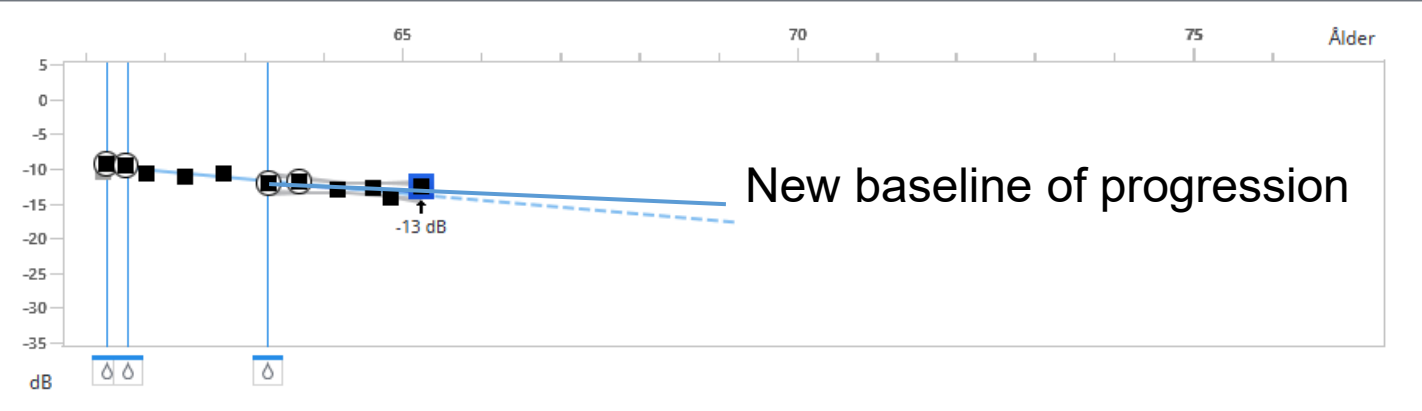
Visual Field Index

Progressionstakt: $-2,2 \pm 0,3 \%$ / år (95% förtroende) $-1,5 \pm 0,5 \%$ / år (95% förtroende)



Medelvärdesavvikelse

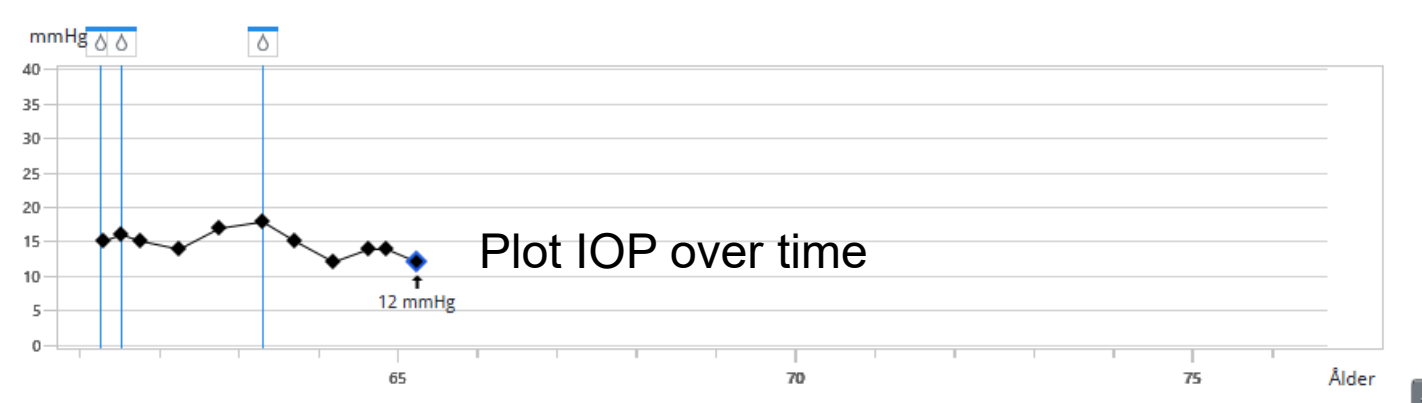
MD-lutning: $-1,0 \pm 0,3 \text{ dB}$ / år (95% förtroende) $-0,6 \pm 1,2 \text{ dB}$ / år (95% förtroende)



Intraokulärt tryck

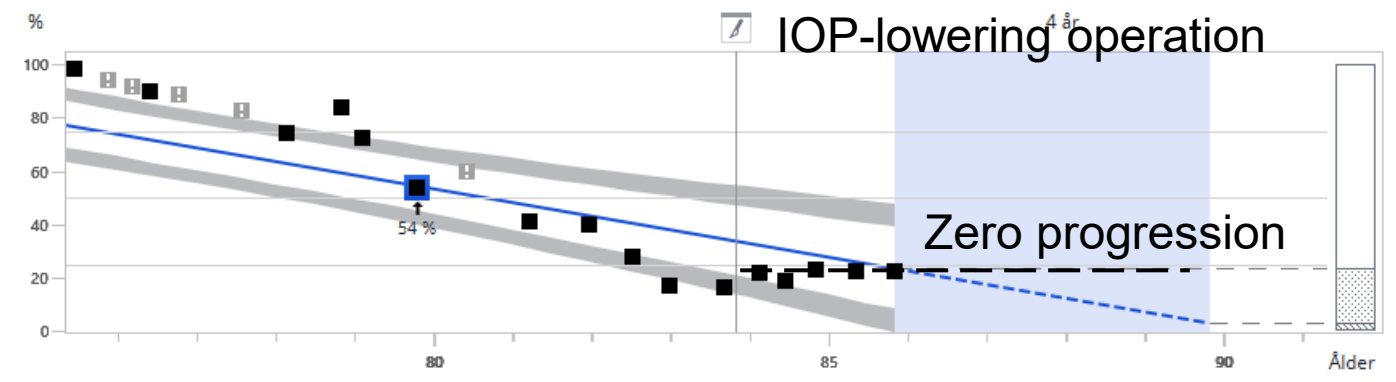
IOP + IOP

CCT (manuellt): μm



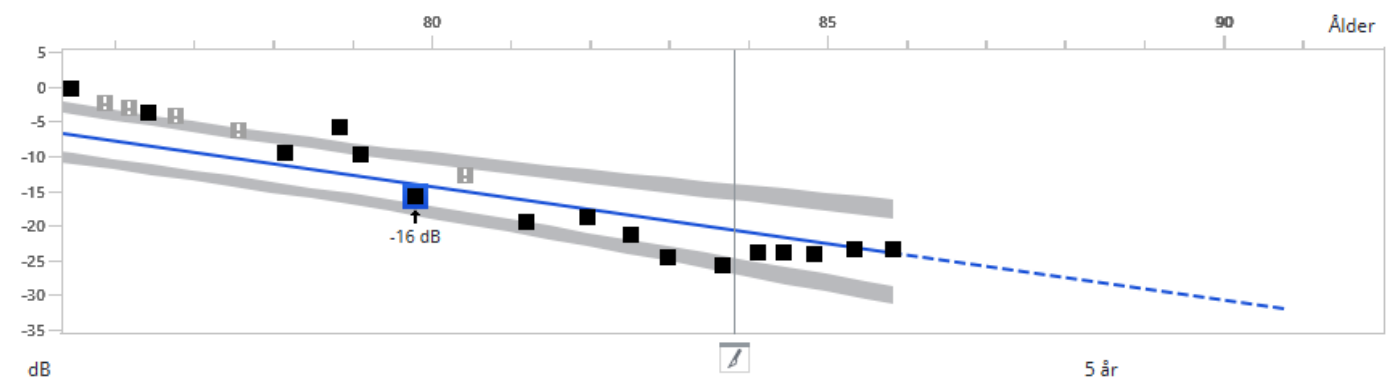
Visual Field Index

Progressionstakt: $-5,1 \pm 1,0\%$ / år (95% förtroende)



Medelvärdesavvikelse

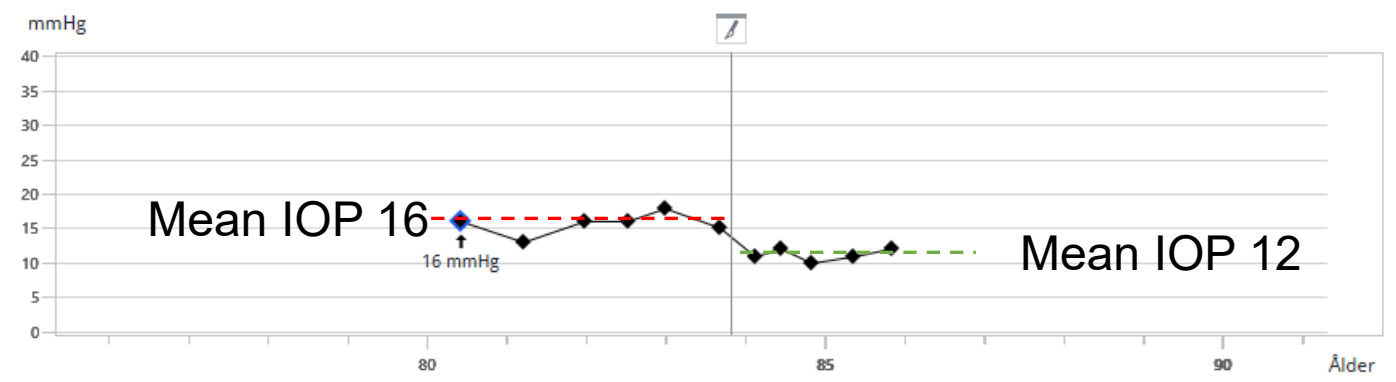
MD-lutning: $-1,6 \pm 0,3\text{ dB}$ / år (95% förtroende)



Intraokulärt tryck

IOP + IOP

CCT (manuellt): μm



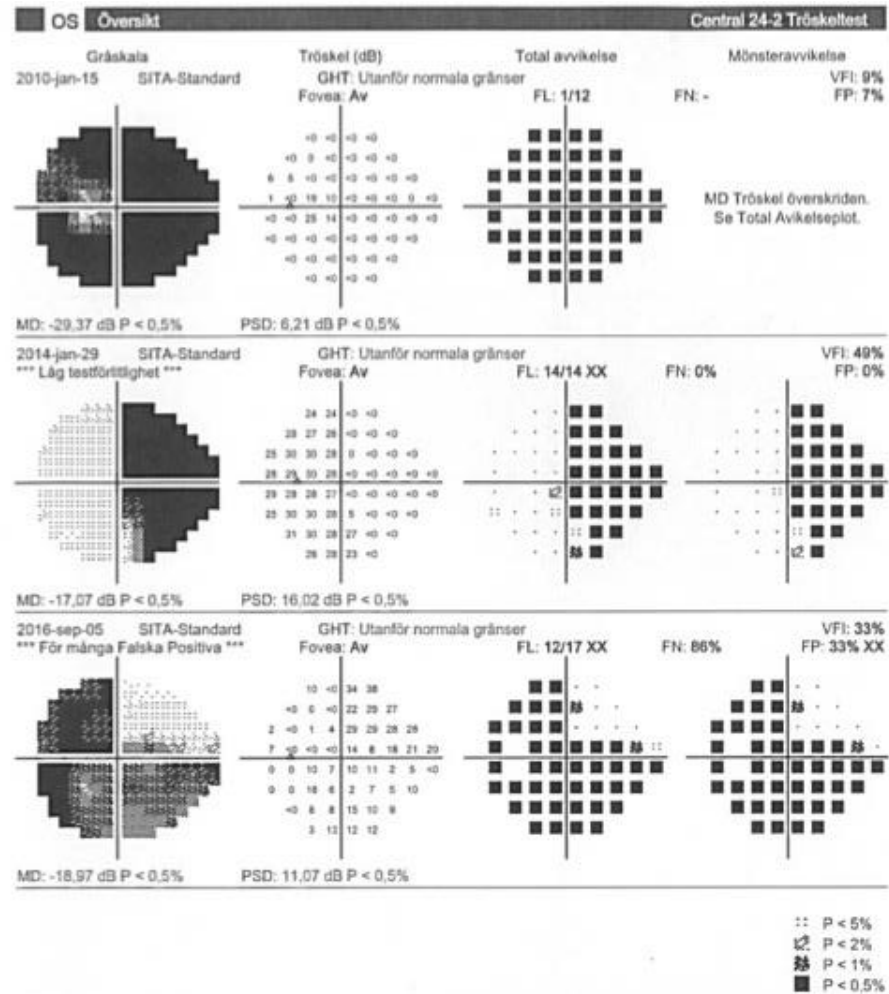
True progression or not?

- IOP – the same or higher than before?
- Bilateral progression? Equal amount?
- Other disease (AMD, stroke)?
- Compliance?

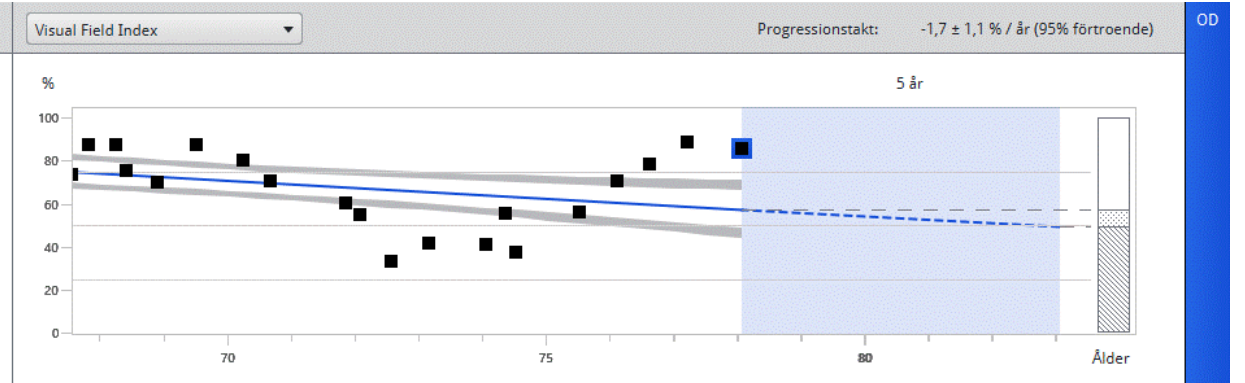
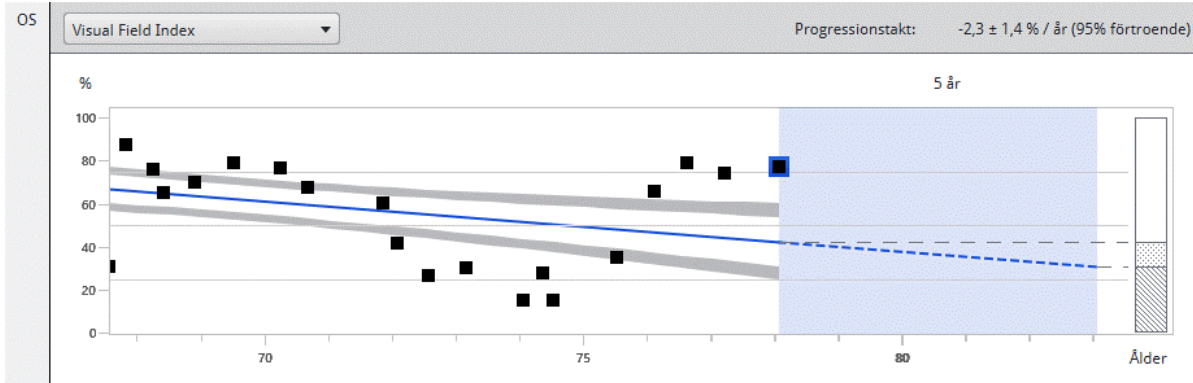
- Always look at the individual visual fields, not just GPA!
- If in doubt – new visual field test within a few months if IOP is ok

Unreliable visual field tests

- Everyone can have a bad day, or two, or three...



- Does the optic nerve appearance match the visual fields?




How to get reliable tests

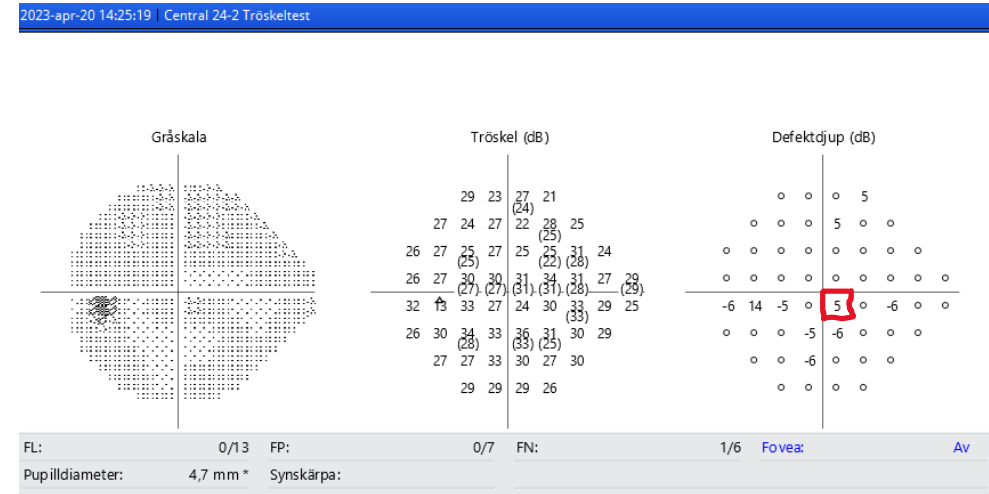
- Inform the patient on how to perform a visual field test
- Watch the patient for clues to bad performance
- Do a visual field test yourself!

- Try Stimulus V – easier due to larger stimulus size

Before




After



- Large diamond fixation \diamond , e.g. AMD
- Fatigue – start testing the left eye
- SITA faster – takes less time, better results in some patients
- Slower tempo, adjust in the machine settings

Thank you!



LUNDS
UNIVERSITET



Skånes universitetssjukhus
En del av Region Skåne

Positive Psychology in the Eye ward

NCON Malmø 22-24 May 2024

Kristina Thybo Petersen

Headnurse, Diploma in health & Master of
Positive Psychology

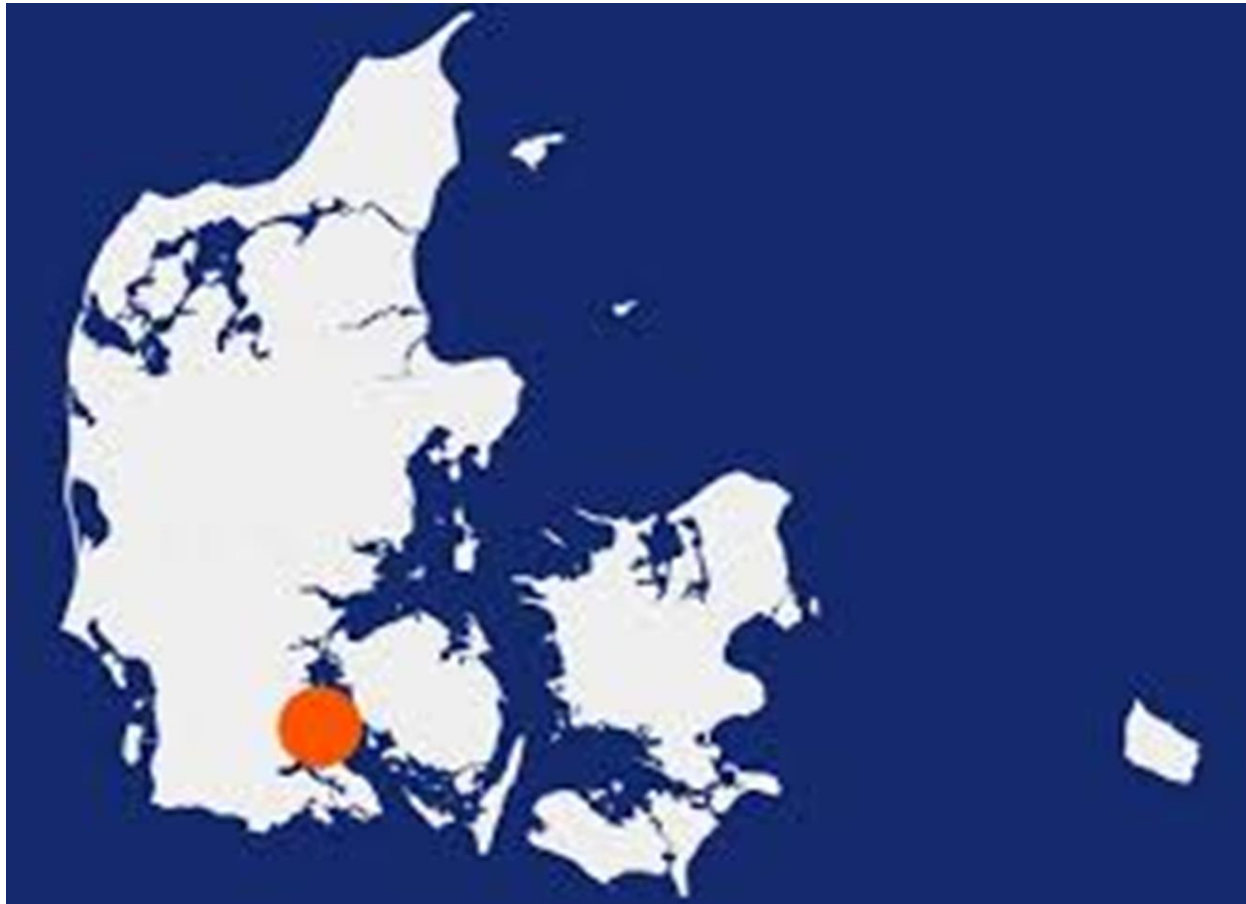Eye department at SHS -Sønderborg
Hospital

Why am I here today?:

Hospital
Sønderjylland



Hospital Sønderjylland







Hospital Sønderjylland



Hospital
Sønderjylland

Does it matter ?



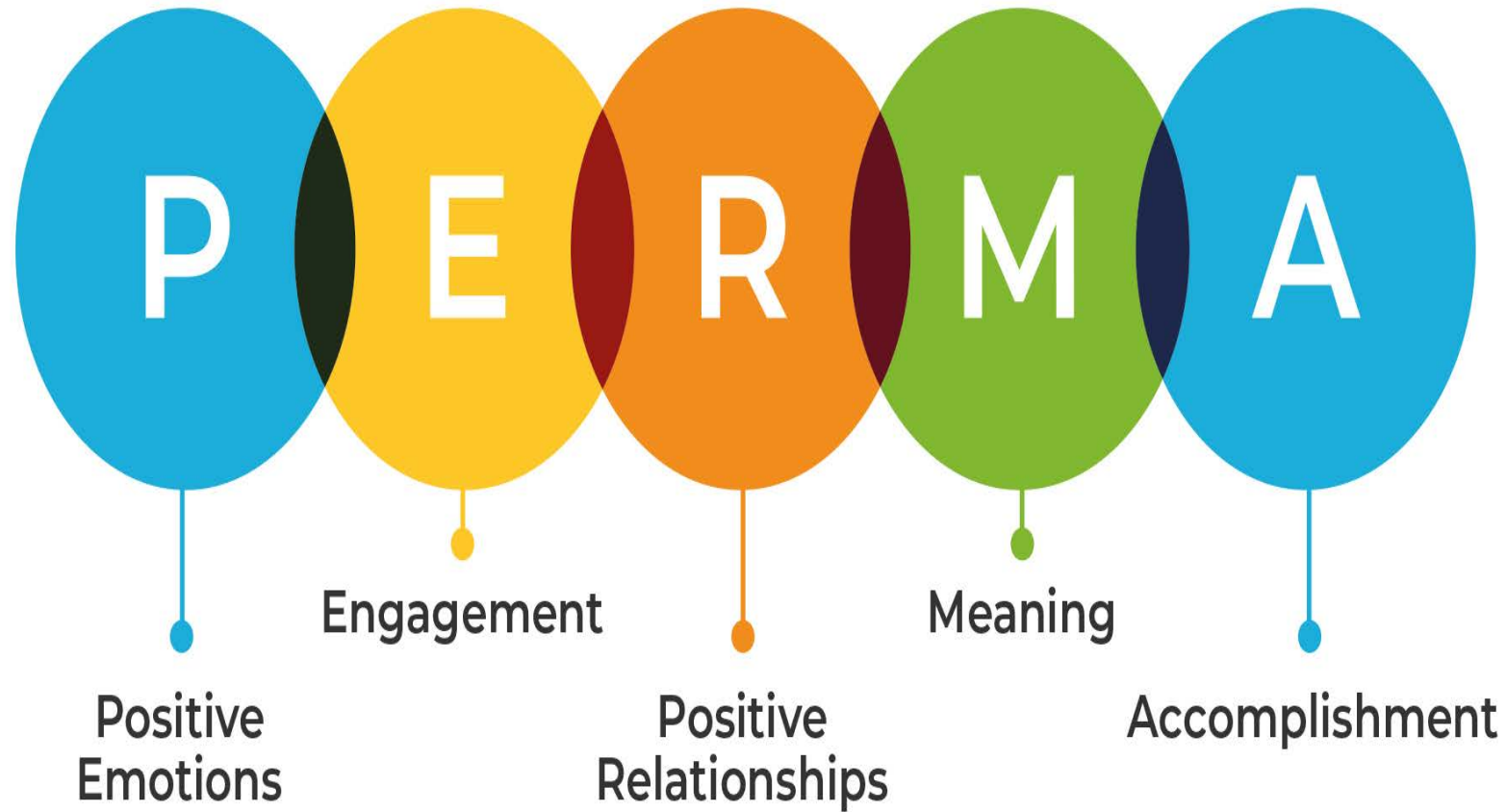


Source: Fredrickson, Barbara (2009)

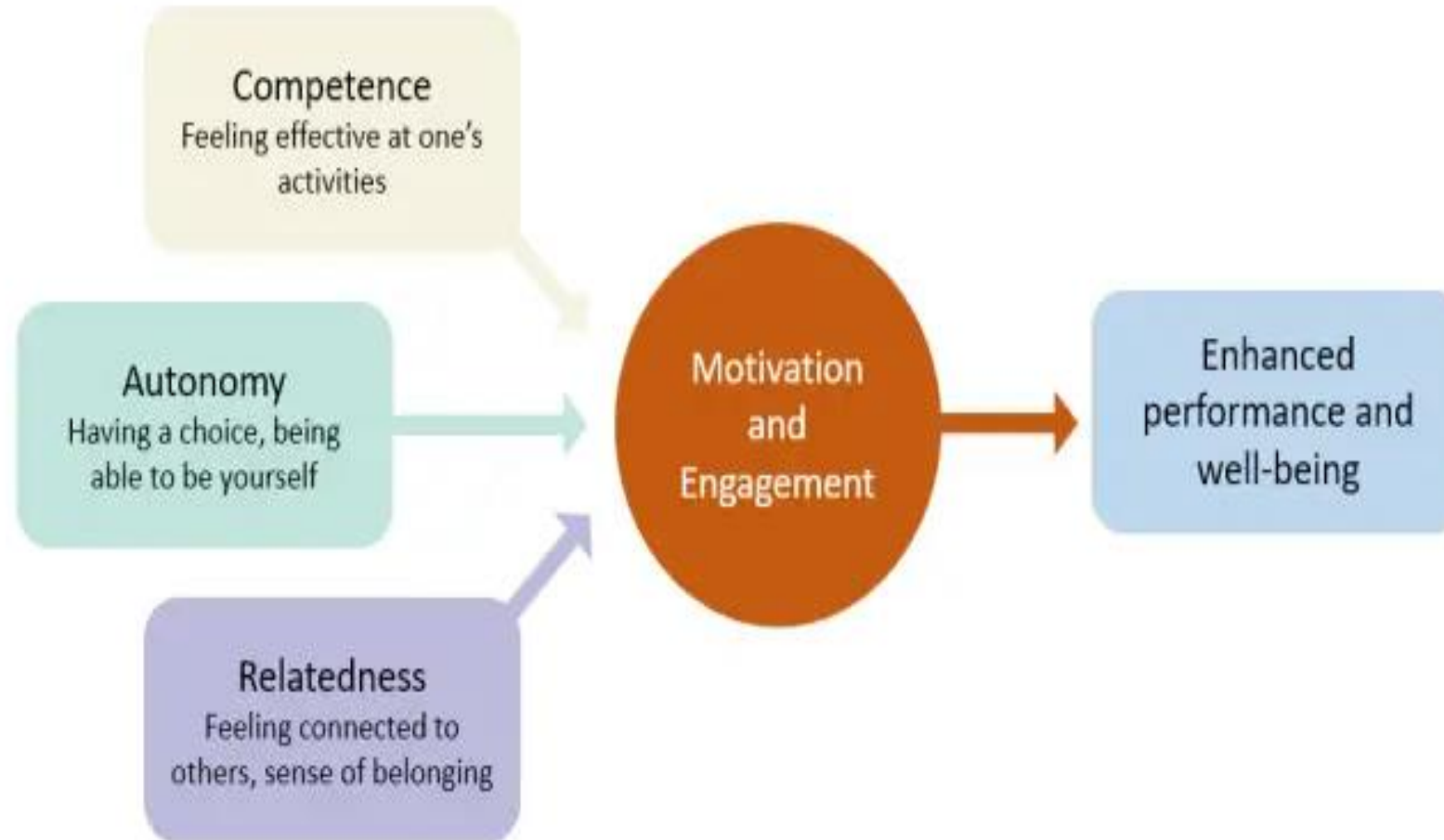
3 POSITIVES TO 1 NEGATIVE



PERMA model of well-being



Self-determination Theory (Ryan & Deci, 2017)

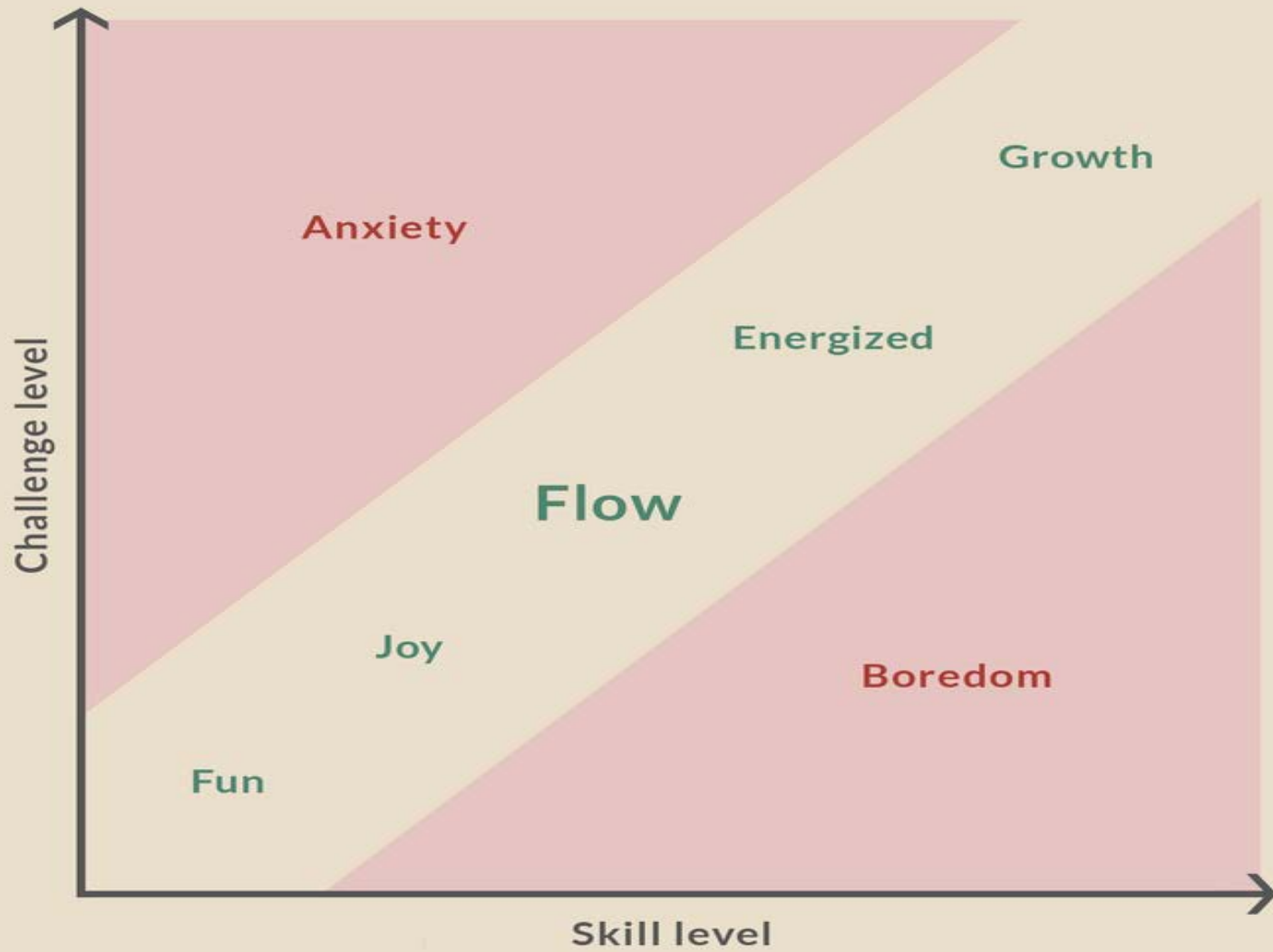


Motivation –intrinsic or extrinsic

Hospital
Sønderjylland



FLOW STATE

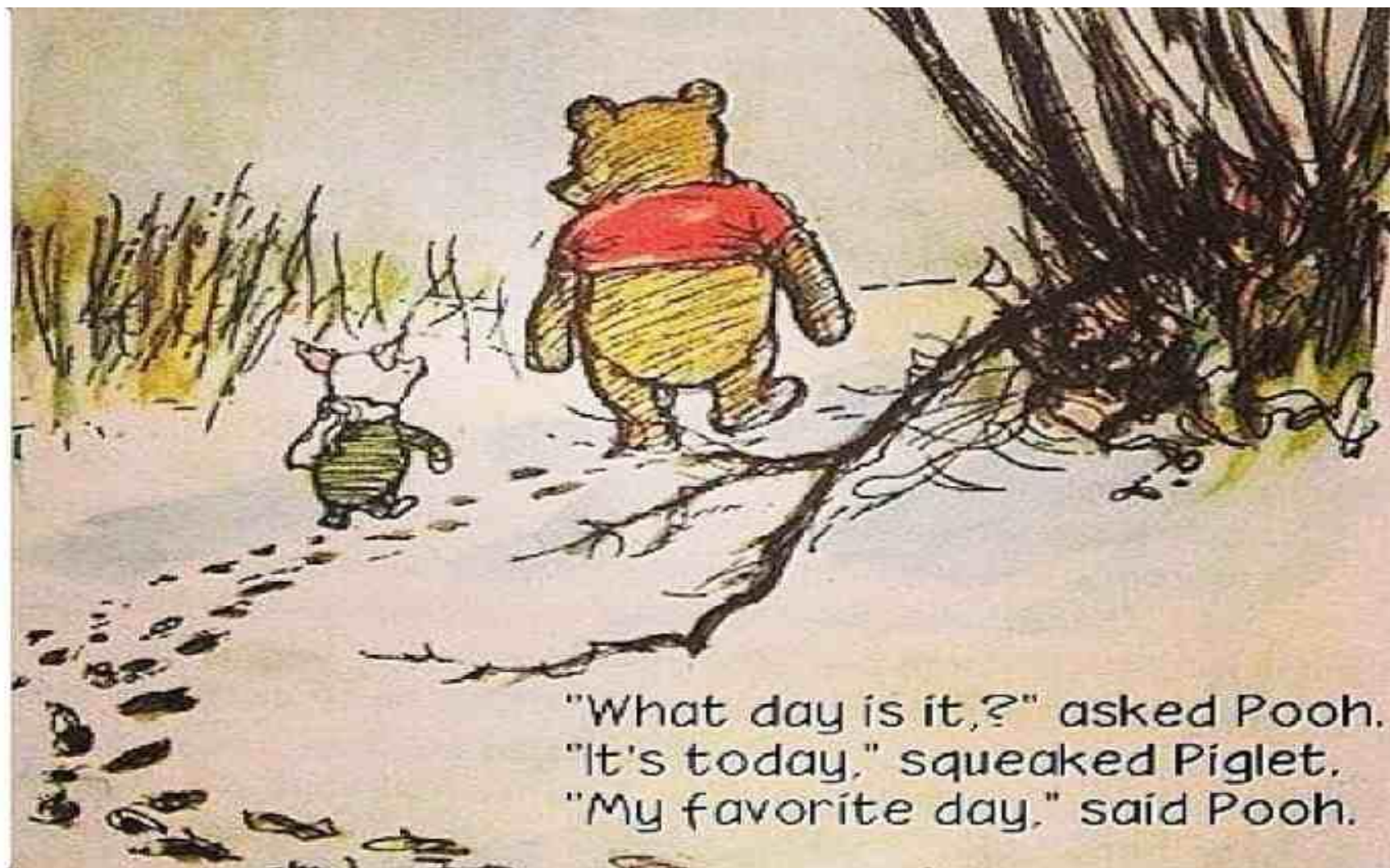


PositivePsychology.com

Hospital
Sønderjylland



Region Syddanmark



"What day is it,?" asked Pooh.
"It's today," squeaked Piglet.
"My favorite day," said Pooh.

Any questions?



Hospital
Sønderjylland

How to become an Ophthalmic Nurse at Halmstad University

Jeanette Källstrand
PhD and Ophthalmic Nurse
Senior lecturer

Jeanette.kallstrand@hh.se



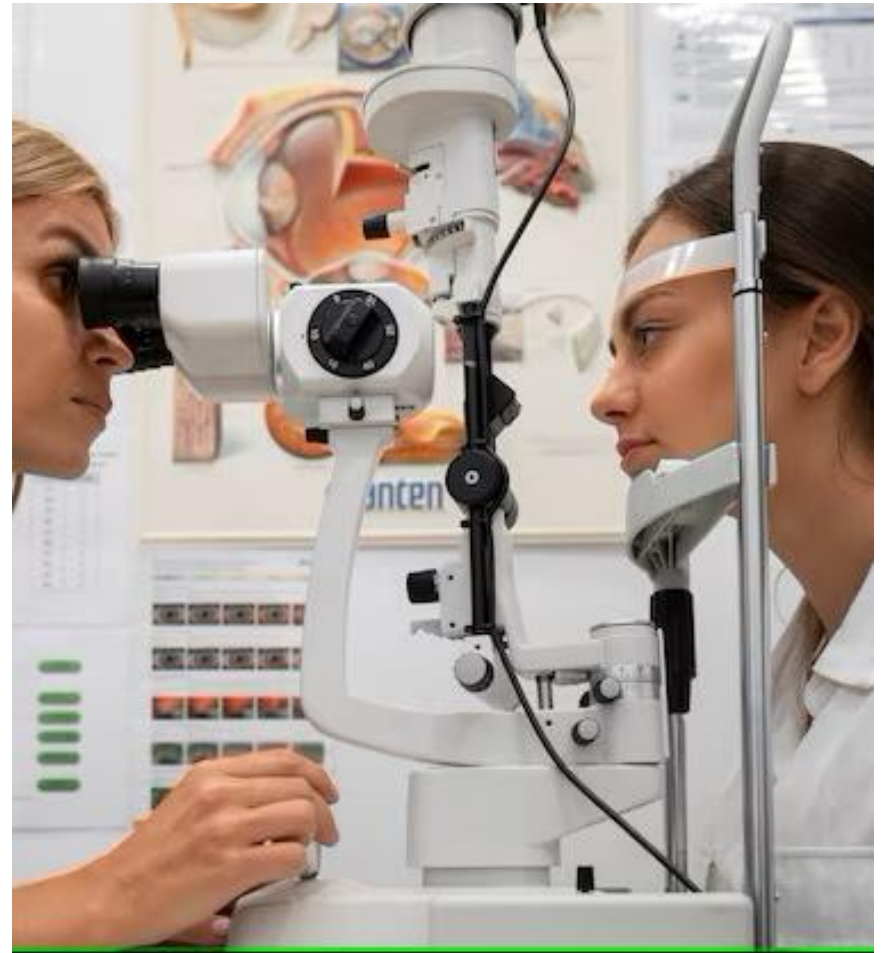What do a Swedish ophthalmic nurse do?

Visual acuity, Visual field tests,
Intraocular pressure, Color vision, Eye
muscles tests, Slit-lamp examinations

Nurse led clinics

- Triage at eye emergency room
- Glaucoma
- Diabetes, screening -
photography
- AMD
- Administer intravitreal injections
- Dry eyes
- Patient education

- E.g. assess visual fields, fundus
photography



And.....

- Telephone counseling
 - OCT
 - Photography
 - Angiography such as fluorescein angiography
 - Surgery
 - Assist during eye surgery
 - Pre- and post operative examinations
- ..and probably so much more



Hämtat från Vårdhandboken

The Swedish Higher Education Act SFS 2006:173

- Higher education must rest on a **scientific basis** and be **evidence based**
- Higher education must be conducted so that there is a **strong connection between research and education**

Exams

- Specialist Nurse in Ophthalmic Care (a professional degree)
- One year Master (an academic degree)



Entry requirements

- Registered nurse
- Bachelor's degree including a bachelor's thesis of 15 credits
- At least one year full time work experience as a registered nurse



Specialist Nursing - Ophthalmic Nursing

60 credits

Term 1

- The eye - anatomy and physiology, optics*
- Ophthalmiatrics 1– in the perspective of ophthalmic nursing (anterior segments)*

Term 2

- Ophthalmology in Ophthalmic Nursing Care I*
- Ophthalmiatrics II – in the perspective of ophthalmic nursing (posterior segments)*

Term 3

- Science Theory and Scientific Method*
- Ophthalmology in Ophthalmic Nursing Care II (posterior segments)*

Term 4


Nursing - Thesis, Ophthalmic Care 15 credits

*7,5 credits

The ICN Code of Ethics for Nurses

The Core Competencies of Nursing

- Person centered care
- Teamwork and collaboration
- Evidencebased care
- Quality improvement
- Informatics
- Safe Care

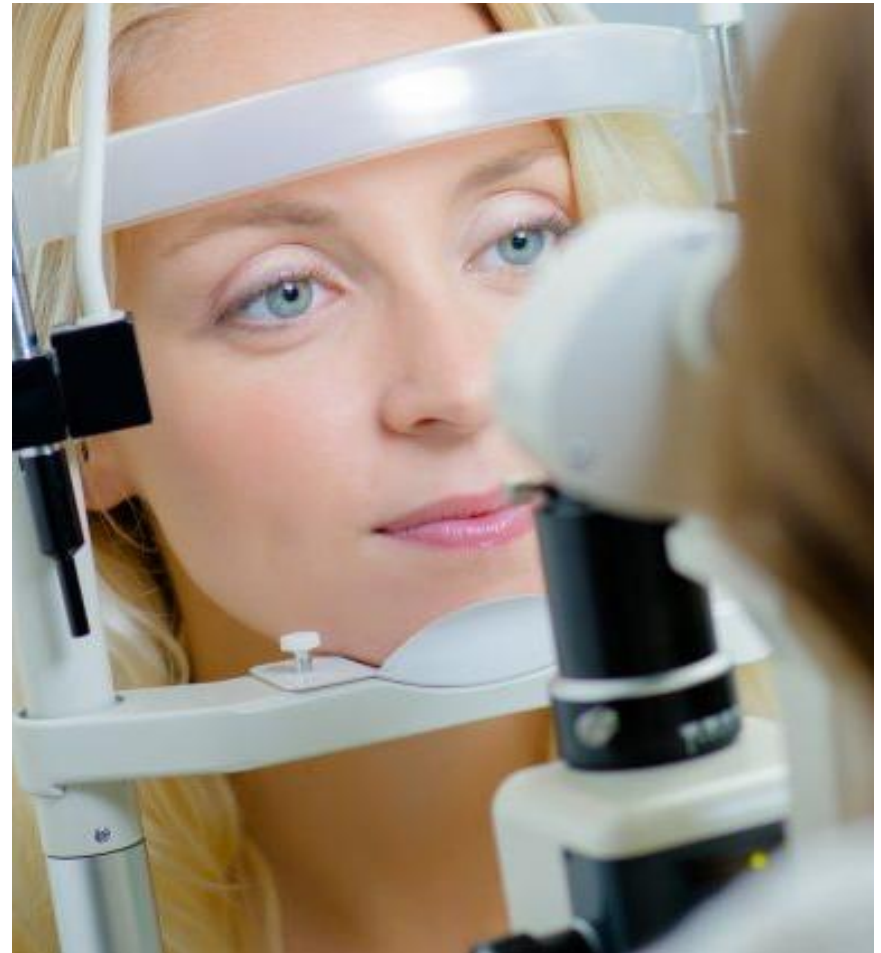

The supervisor nursing placement

- Specialist nurse exam
- At least one year working experience
- Preferable a course in *Supervising Nursing students* 7,5 credits

Challenges

To find supervisors who are specialist ophthalmic nurses!



<http://nurseadvisormagazine.com/tn-exclusive/how-to-become-an-ophthalmic-nurse/>

Nursing placements

- Field studies
 - 2 days with an ophthalmic nurse during the first
 - Low vision clinic
 - Orthoptist
- 5 weeks anterior segments including 1 week eye surgery
- 5 weeks posterior segments

(full time because of the continuity)

Assessment of Clinical Education tool AssCe

Factors in the AssCE-master tool

1. Communication and interaction with patients
2. Communication and encounter with next of kin
3. Co-operation with various authorities within nursing and health care
4. Informs and teaches patients and family/friends
5. Informs and teaches colleagues and students
6. Describes patients' nursing care needs
7. Plans and prioritizes nursing care interventions
8. Carries out nursing care interventions
9. Follows up needs/problems and nursing care interventions
10. Reports, documents and record-keeping
11. Participates in and carries out examinations and treatments
12. Administers medications
13. Plans, organizes and allocates work assignments
14. Co-operates
15. Readiness to act
16. Safety awareness
17. Scientific awareness
18. Ethical awareness
19. Self-knowledge
20. Thoroughness, reliability and judgment
21. Independence

The student shall be able to

I. Communication and teaching

1. Communication and interaction with patients

Inadequate achievement of goals	Good achievement of goals	Very good achievement of goals
	Demonstrate an independent and professional approach in the communication with patients, also in complicated situations involving individuals with different cognitive capacities. Demonstrate the ability to listen. Demonstrate knowledge and commitment to facilitating communication and ensuring patient participation.	Demonstrate an <i>advanced</i> independent and professional approach in the communication with patients, also in complicated situations involving individuals with different cognitive capacities. Demonstrate a <i>specialised</i> knowledge and commitment to facilitating communication and ensuring patient participation.

Comments:

Triple Jump examination

Firstly (step one)

2 patient visits with various assessments

Secondly (step two)

Identify "problem areas" in caring related to the 2 cases

Finally (third step)

Oral seminar together with other students



HÖGSKOLAN
I HALMSTAD

En högskola där olika perspektiv möts

KAFÉ FRAMKANTEN

KAFÉ FRAMKANTEN



Ophthalmic nursing at the USN

Torgeir Solberg Mathisen, PhD

Tove Lise Morisbakk, PhD

Institutt for optometri, radiografi og lysdesign





Tove Lise Morisbakk

Førsteamanuensis innen optometri

Fakultet for helse- og sosialvitenskap
Institutt for optometri, radiografi og lysdesign
Campus Kongsberg (5327)

Tove.Lise.Morisbakk@usn.no
31 00 97 55



Torgeir Solberg Mathisen

Førsteamanuensis

Fakultet for helse- og sosialvitenskap
Institutt for optometri, radiografi og lysdesign
Campus Kongsberg (5320)

Torgeir.Solberg.Mathisen@usn.no
31 00 94 48

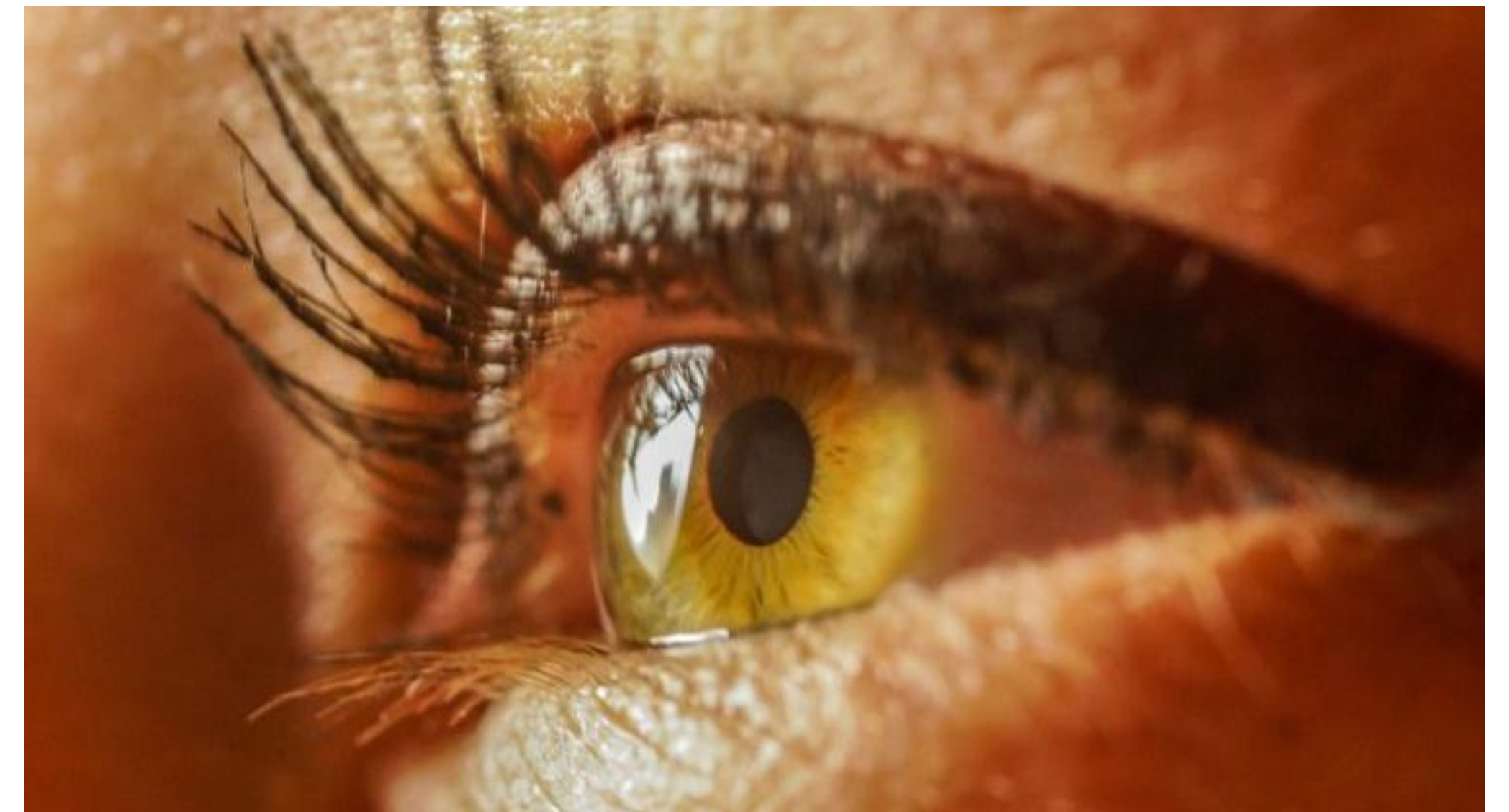
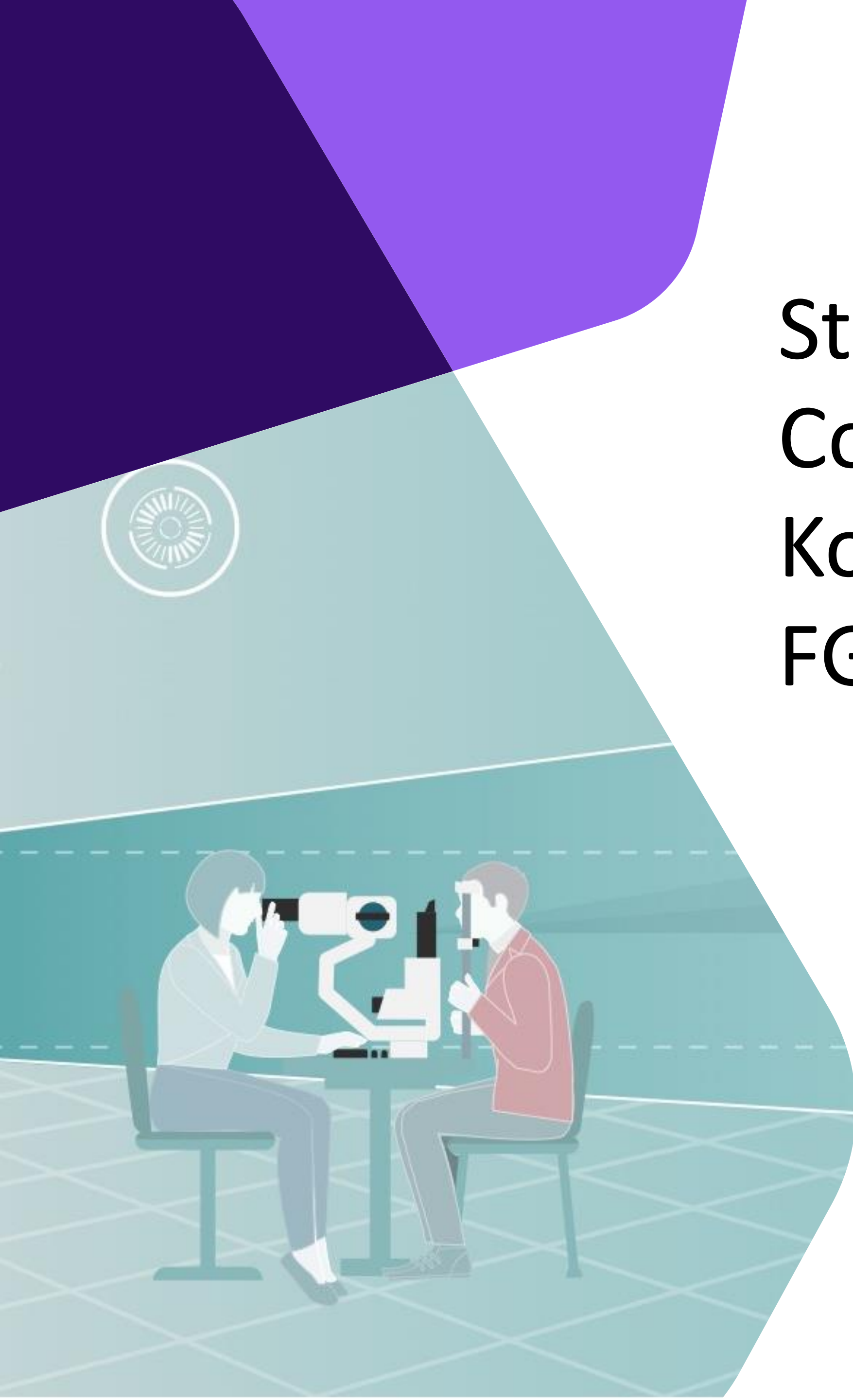
CAMPUS DRAMMEN



CAMPUS KONGSBERG

Started in 2015
Collaboration between optometry in
Kongsberg, nursing in Drammen, and
FGØS



www.usn.no
Øyesykepleie



The screenshot shows the top navigation bar of the USN website. On the left is the USN logo and the text "Universitetet i Sørøst-Norge". To the right are menu items: "Studier" with a dropdown arrow, "Forskning" with a dropdown arrow, "Om USN" with a dropdown arrow, and "Kontakt oss" with a dropdown arrow. Further right is a search bar with the text "Søk" and a magnifying glass icon. On the far right are two buttons: "For studenter" and "For ansatte".

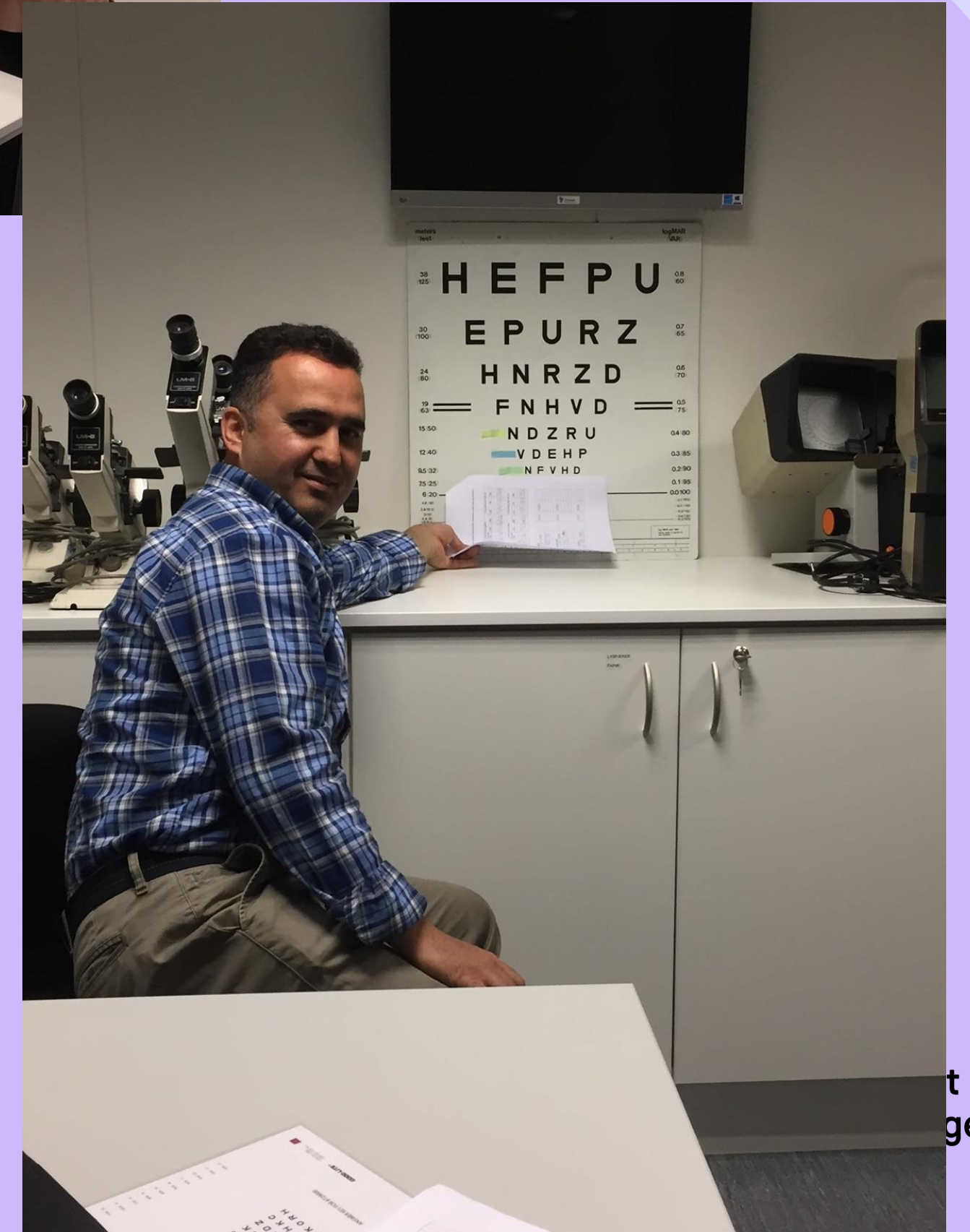
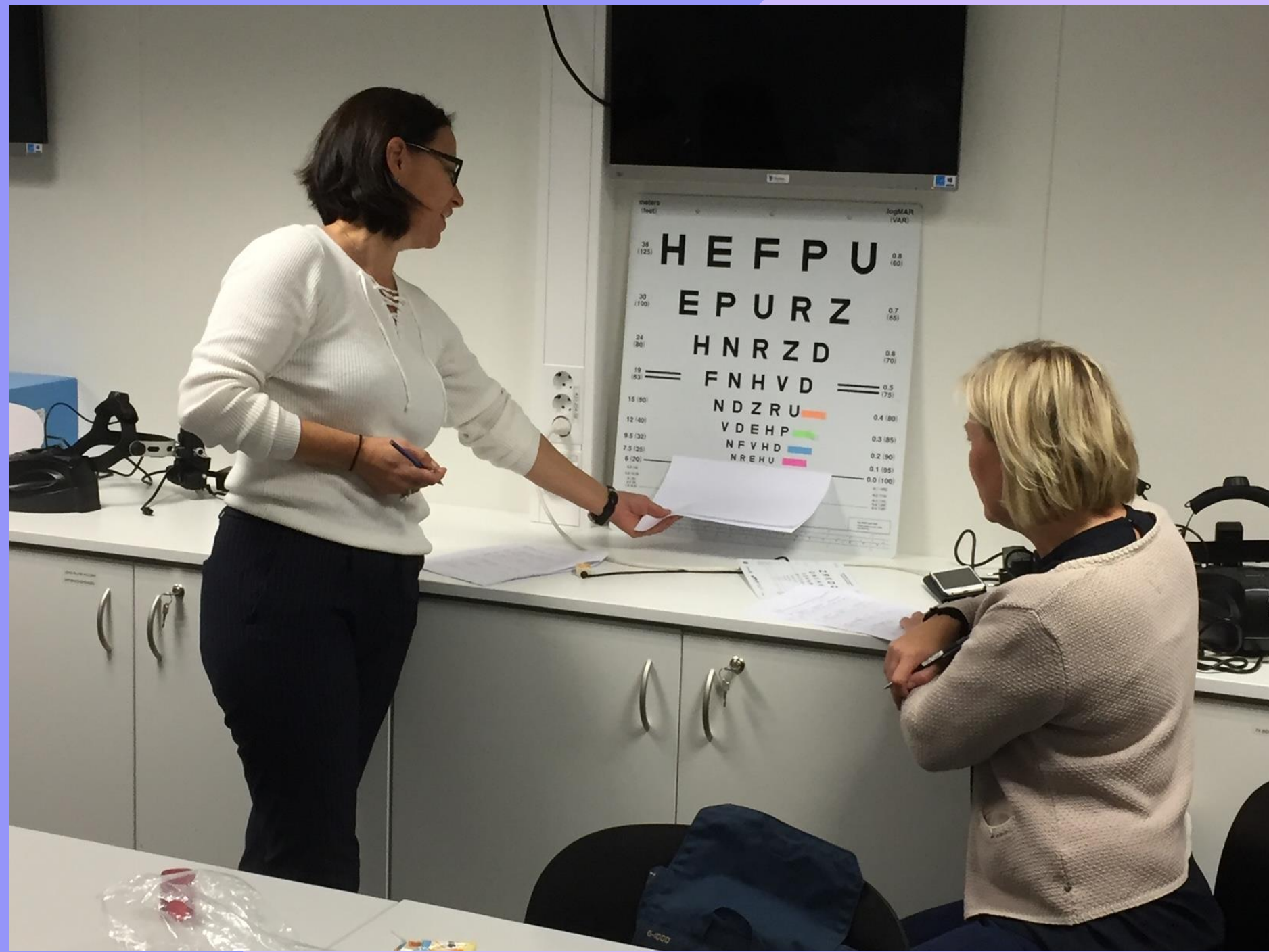
The main content area has a dark blue background. At the top center is a circular logo with a sunburst pattern. To the right of the logo is the text "Next application spring 2025". Below the logo is the title "Øyesykepleie" in a large, white, serif font. Underneath the title is the text "Kongsberg - Deltid". At the bottom of the main content area is a paragraph of text in white: "Er du sykepleier og ønsker deg økt kompetanse innenfor øyesykepleie? Da har vi et spennende studietilbud for deg! Studiet er unikt og den eneste videreutdanningen innen feltet i Norge."

Organisation

4 semesters, part time

2 on campus seminars per
semester

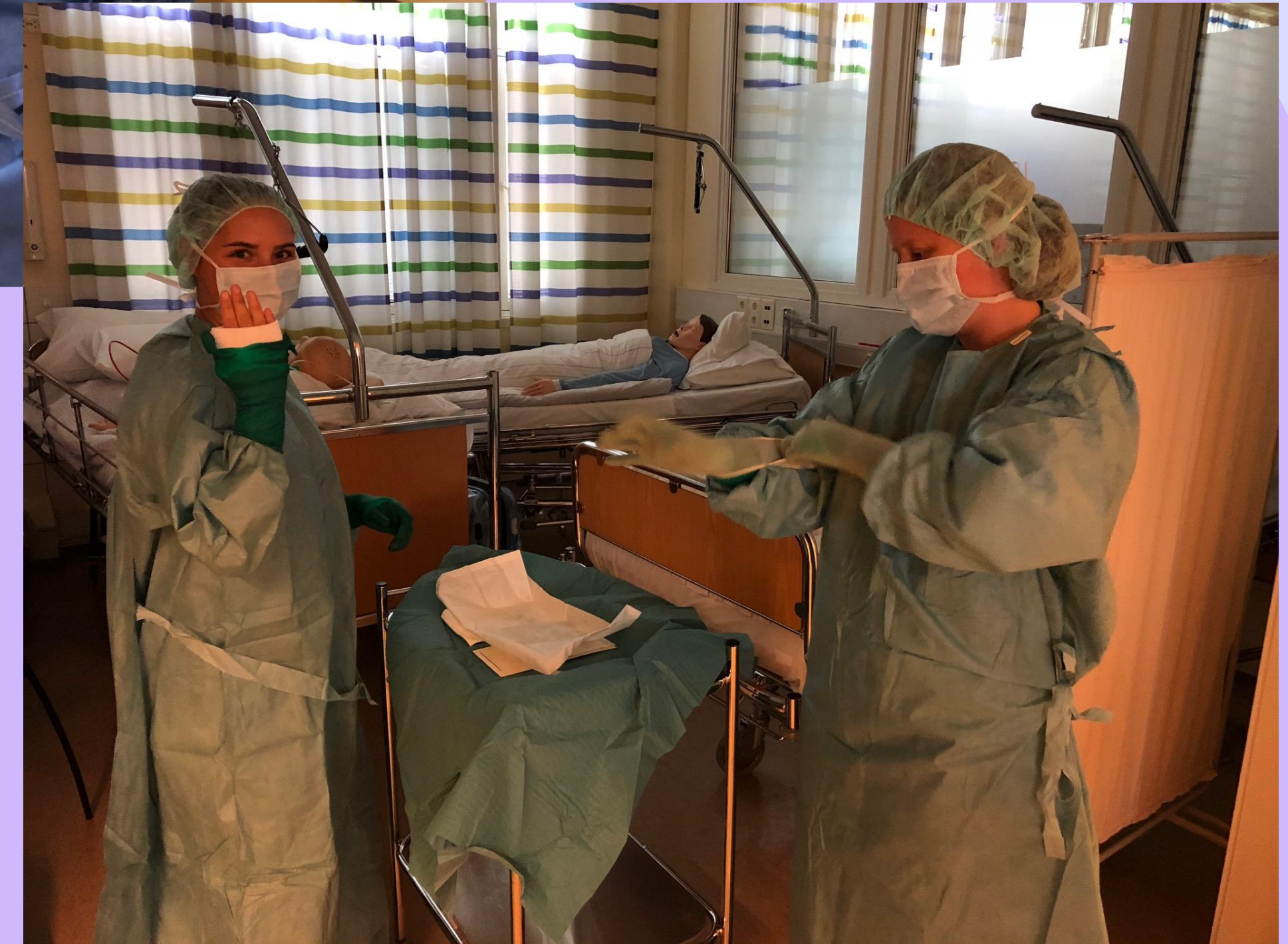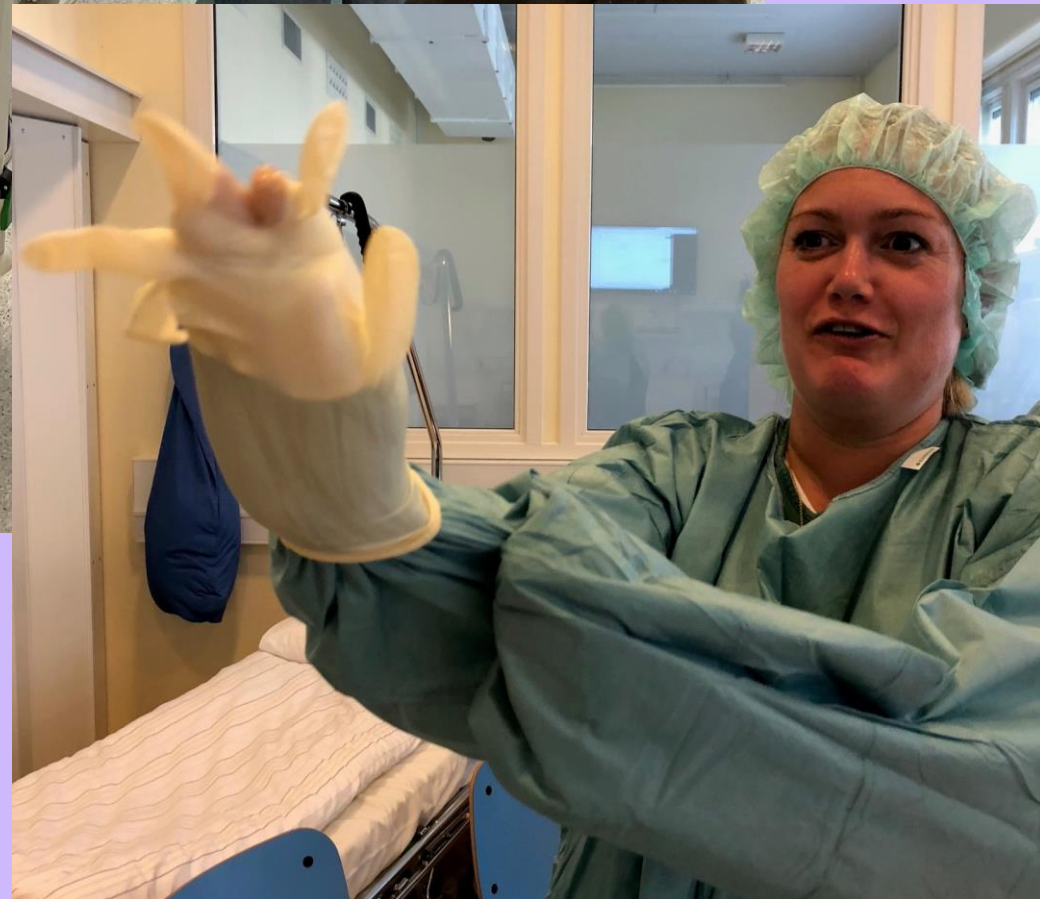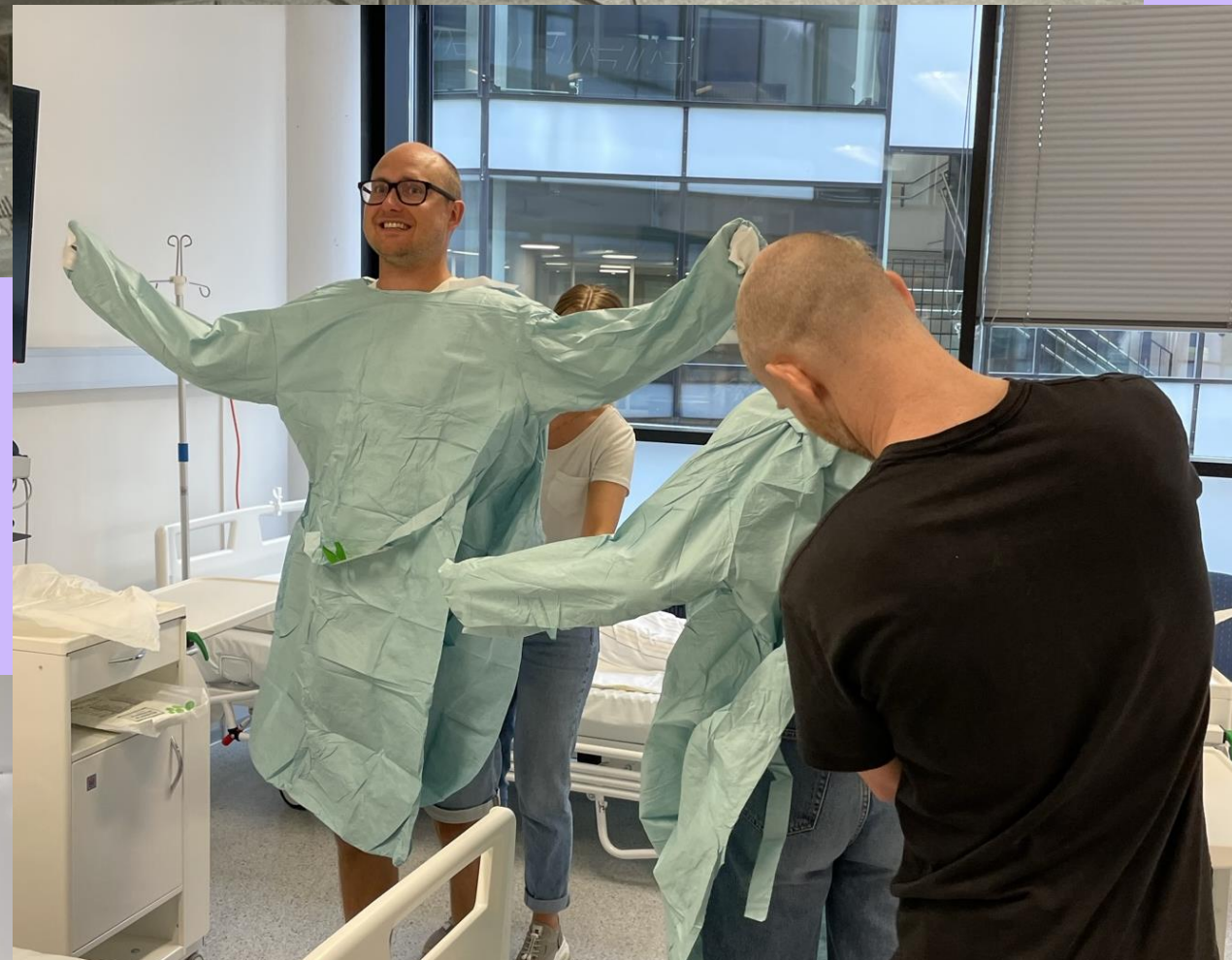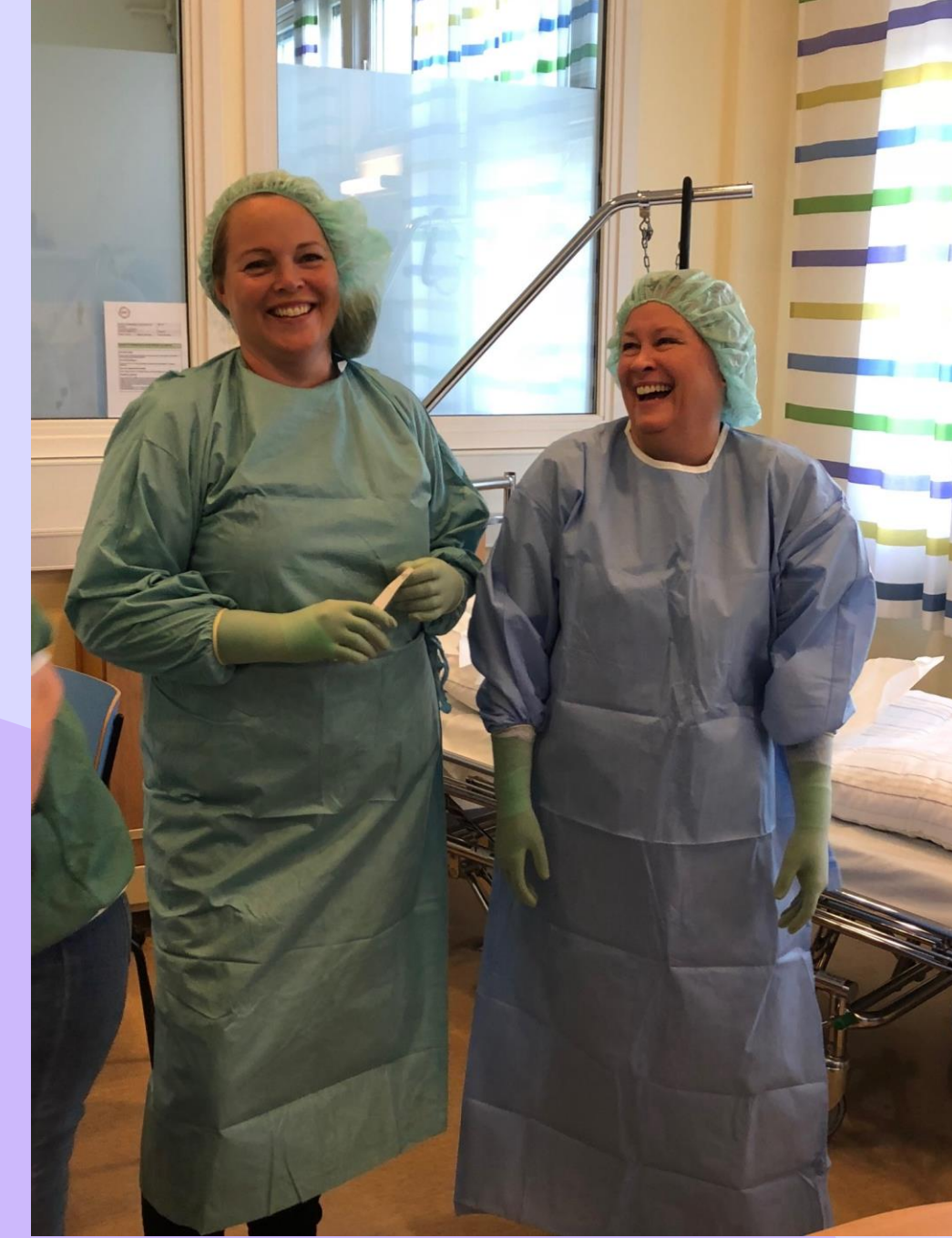Workshops, assignments and
exams



Content of the education

www.usn.no
Øyesykepleie

- Anatomy, physiology and optics of the eye
- Ophthalmology and examination methods, including 2 weeks practise in an outpatient clinic
- Ophthalmic surgery and perioperative care, including 6 weeks practise in surgery
- The role of nursing in preventive, caring, palliative and rehabilitative ophthalmic care



Fagdag - Øyesykepleie

Institutt for optometri, radiografi og lysdesign
Institutt for sykepleie- og helsevitenskap

Videreutdanning i Øyesykepleie

Emne: ØSYK400 – Forebyggende, behandlende, lindrende og rehabiliterende øyeomsorg,
15 studiepoeng

Onsdag 14. juni 2023

Moderatorer: Torgeir Solberg Mathisen, Ph.D. og Tove Lise Morisbakk, Ph.D.

Universitetet i Sørøst-Norge, Campus Kongsberg
Rom: Becker auditorium

www.usn.no
Øyesykepleie





Masters degree?

- Working on a model, may be ready 2025
- Can use earlier education: ØSYK + 60 ECT (methods and masters assignment)
- Currently under work and will be applied for in June

Additional courses

- Diabetes and vision

Ny tverrfaglig Master – fargekoding:

optometrist

øyesykepleier

ortoptist

synspedagog

tverrfaglig

Modul 1

MSKL124 5 stp	MSKL224 10 stp	MPRA124 5 stp	MPRA224 5 stp	MOKM024 5 stp	MOPD024 5 stp optometrist øyesykepleier ortoptist
------------------	-------------------	------------------	------------------	------------------	---

MEBP124 5 stp øyesykepleier synspedagog	MEBP224 5 stp optometrist øyesykepleier ortoptist synspedagog
---	---

MØYE1 10 stp
Øyets anatomi og fysiologi
ortoptist øyesykepleier

MSYN1 5 stp
Syn og optikk
ortoptist øyesykepleier synspedagog

ØSYK200 15 stp
Oftalmologi, undersøkelsesmetoder
ortoptist

MSRI 10 stp
Intro spes.ped, rehab
optometrist synspedagog

NMS002 15 stp
Synsped.arbeid, rehab
optometrist synspedagog

Modul 2

MAKM119
10 stp

MAKM219
10 stp

MORT1
10 stp
optometrist ortoptist

MORT2
10 stp
optometrist ortoptist

MSS1
10 stp
optometrist synspedagog

NMS003
10 stp
optometrist synspedagog

MANA1
5 stp
optometrist øyesykepleier ortoptist synspedagog

MANA2
5 stp
optometrist øyesykepleier ortoptist synspedagog

ØSYK300 15 stp
Kirurgisk oftalmologi,
perioperativ omsorg

ØSYK4 5 stp
Forebyggende behandling,
lindrende og rehabilit. omsorg

MRES
10 stp
optometrist øyesykepleier ortoptist synspedagog

MKVL
5 stp
optometrist øyesykepleier ortoptist synspedagog

Modul 3



MORT324
10 stp
optometrist ortoptist

MTER024
10 stp

MSS2
10 stp
optometrist synspedagog

MAKM319
10 stp
synspedagog

Diabetes
10 stp
optometrist øyesykepleier

Masteroppgave 30 stp
optometrist øyesykepleier ortoptist synspedagog

Lyst til å holdes oppdatert?

Hilde.e.wedde@usn.no



Hilde Elisabeth Wedde

Bedriftskoordinator / Rådgiver

Fakultet for helse- og sosialvitenskap
Institutt for optometri, radiografi og lysdesign
Campus Kongsberg (5311)

Hilde.E.Wedde@usn.no

31 00 97 05



Universitetet
i Sørøst-Norge